

# UC Davis

## Dermatology Online Journal

### Title

Cutaneous varicella zoster virus infection following zoster vaccination: report of post-vaccination herpes zoster skin infection and literature review of zoster vaccination efficacy and guidelines

### Permalink

<https://escholarship.org/uc/item/9tv6p5jz>

### Journal

Dermatology Online Journal, 23(6)

### Authors

Stiff, Katherine M  
Cohen, Philip R

### Publication Date

2017

### DOI

10.5070/D3236035389

### Copyright Information

Copyright 2017 by the author(s). This work is made available under the terms of a Creative Commons Attribution-NonCommercial-NoDerivatives License, available at <https://creativecommons.org/licenses/by-nc-nd/4.0/>

Peer reviewed

# Cutaneous varicella zoster virus infection following zoster vaccination: report of post-vaccination herpes zoster skin infection and literature review of zoster vaccination efficacy and guidelines

Katherine M Stiff<sup>1</sup> BS and Philip R Cohen<sup>2</sup> MD

Affiliations: <sup>1</sup>Northeast Ohio Medical University, Rootstown, Ohio, <sup>2</sup>Department of Dermatology, University of California San Diego, La Jolla, California

Corresponding Author: Philip R Cohen, MD, 10991 Twinleaf Court, San Diego, CA 92131, Email: mitehead@gmail.com

## Abstract

**Background:** Herpes zoster vaccine is currently recommended in the United States for immune competent individuals  $\geq 60$  years. The efficacy of the herpes zoster vaccine decreases with age and with time following vaccination.

**Purpose:** An elderly man with herpes zoster following vaccination is described. The guidelines for vaccination and issues regarding re-vaccination are reviewed.

**Methods:** PubMed was used to search the following terms: efficacy, elderly, herpes zoster, herpes zoster incidence, herpes zoster recurrence, and vaccination. The papers and relevant citations were reviewed. The clinical features of a patient with post-vaccination herpes zoster skin infection are presented; in addition, vaccine efficacy and guidelines are reviewed.

**Results:** A 91-year-old man, vaccinated for herpes zoster 10 years earlier, presented with crusted erosions on his face corresponding to the area innervated by the ophthalmic division of the left trigeminal nerve. Evaluation using polymerase chain reaction confirmed the diagnosis of herpes zoster.

**Conclusions:** Herpes zoster vaccine decreases in efficacy with both age and number of years following vaccination. Therefore, booster shots or revaccination in the older population may be of benefit.

dormant in sensory and cranial ganglia and reactivates in approximately 15% of people to cause herpes zoster (shingles). Most cases of reactivation occur in the older population owing to declining cell-mediated immunity [1]. The virus usually presents with painful unilateral dermatomal lesions. The most common complication of herpes zoster is postherpetic neuralgia; this is a progression of herpes zoster, with pain persisting for over three months [2].

A herpes zoster vaccine was approved for use in the United States in 2006. It is recommended, in the United States, for all immune-competent individuals  $\geq 60$  years. We describe a man who received the zoster vaccine at age 81 years and subsequently developed cutaneous herpes zoster 10 years post-vaccination. We also review the guidelines and concerns regarding the efficacy of the herpes zoster vaccine in older adults.

## Case Synopsis

A 91-year-old man visits his ophthalmologist every 3 months for an ocular procedure involving an injection of aflibercept (Eylea<sup>®</sup>) to treat his macular degeneration. Immediately following the procedure, he noted pain around his eye. During the next two days, the pain worsened and extended towards his left ear and forehead. Two days later, he noted blisters on his upper eyelid and scalp.

The ophthalmologist referred him to a dermatologist for evaluation of the lesions. He presented to the dermatology clinic on day 7 after the onset of symptoms. Cutaneous examination revealed crusted erosions on the left upper eyelid and superior helical

*Keywords: herpes, vaccination, vaccine, zoster*

## Introduction

Varicella zoster virus causes varicella (chicken pox) upon initial exposure. The virus then becomes

rim in addition to erythematous pustules on the face and anterior scalp (**Figure 1**). The distribution of the lesions corresponded to the ophthalmic division of the left trigeminal nerve.

A specimen from a lesion was obtained for polymerase chain reaction evaluation. The test was positive for varicella zoster virus. The diagnosis of cutaneous herpes zoster was confirmed.

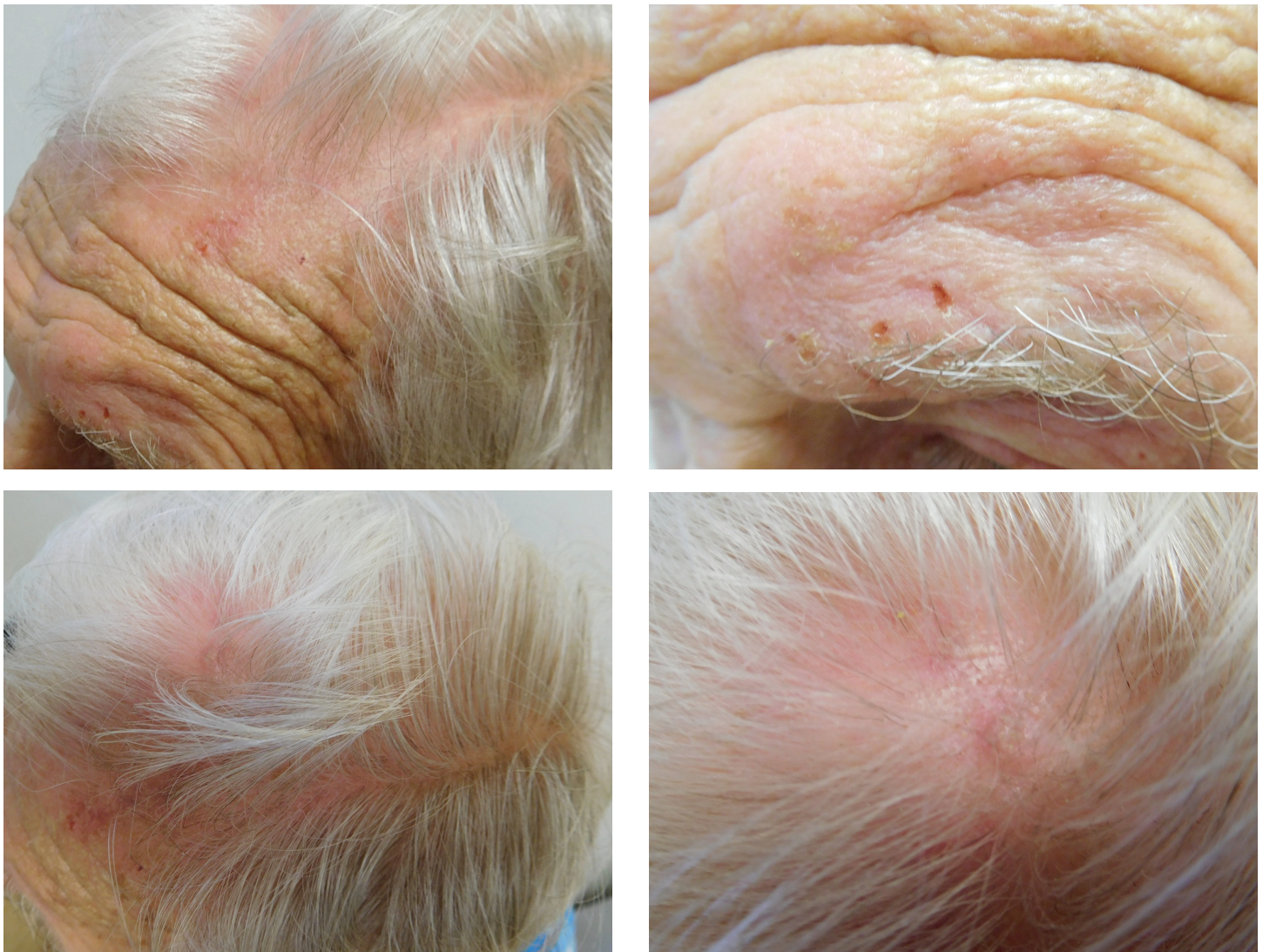
Treatment included oral valacyclovir (1000 mg 3 times daily) and topical mupirocin 2% ointment (3 times daily to the lesions). Within two days after initiating treatment, there was significant relief of pain and the vesicles began to crust. He continued the oral and topical therapy until his follow up appointment

two weeks later; all of his symptoms and lesions had resolved.

### Case Discussion

Varicella zoster virus infects the body when it contacts the mucosa of the upper respiratory tract or the conjunctiva. It then travels through the blood to the skin, leading to the development of the varicella eruption known as chicken pox. The virus can also infect other organ systems [1].

Subsequently, varicella zoster virus becomes dormant in dorsal root and cranial nerve ganglia, where it can reactivate and present as herpes zoster [1]. Herpes zoster affects approximately one million Americans every year. Nearly one in three Americans



**Figure 1.** Distant (left) and closer (right) views of lesions on the face (top left and right) and scalp (bottom left and right) show painful erythematous lesions on the face and pustules on the anterior scalp corresponding to the dermatome innervated by the ophthalmic division of the left trigeminal nerve.

will develop herpes zoster throughout their lifetime and 68% of cases occur in those aged 50 years and older [3].

Most patients with herpes zoster have a prior history of varicella virus infection during childhood. The virus reactivates when cell-mediated immunity declines in older individuals [1] or in immunocompromised patients, including persons with bone marrow and other organ transplants, human immunodeficiency virus infection, Hodgkin disease, leukemia, non-Hodgkin lymphomas, rheumatoid arthritis, systemic lupus erythematosus, and immunosuppressive medication exposure [2, 4, 5].

The onset of herpes zoster can be spontaneous or linked to trauma [6]. A study by Zhang et al. in 2013 showed that individuals with herpes zoster were 3.4-times as likely as controls to have experienced trauma in the week before onset; in addition, patients with cranial herpes zoster were more than 25 times as likely as controls to have had cranial trauma in the week before herpes zoster onset [6]. Our patient's eye treatment may have been associated with his development of herpes zoster.

Herpes zoster usually presents with unilateral erythematous blisters or pustules. Clear vesicles and

new vesicle formation follow for three to 5 days after which the lesions pustulate and scab [6]. The vesicles are traditionally located within one or two adjacent dermatomes, most commonly the thoracic, cervical, or ophthalmic branch of trigeminal ganglion [1]. Pain may precede the appearance of a rash, as it did with our patient, or the patient may not experience pain until the eruption appears. The pain ranges from mild itching, tingling, or allodynia to severe pain [6].

Postherpetic neuralgia, pain persistent after resolution of the eruption, is the most common side effect of herpes zoster [2]. The incidence of this complication increases with age. Indeed, post-herpetic neuralgia occurred in 33% of zoster patients of age 79 years and older; approximately 80-85% of postherpetic neuralgia cases occurs in zoster patients  $\geq 50$  years old [3]. In an analysis of data from the United Kingdom General Practice Research Data-base, Gauthier et al. found that postherpetic neuralgia, defined as pain at 3 months post-zoster episode, increased from 8% of patients ages 50-54 years to 21% of patients ages 80-84 years [7]

The herpes zoster vaccine, Zostavax<sup>®</sup>, was licensed in the United States in 2006. This vaccine is a live attenuated vaccine; thus, it is contraindicated for certain groups of individuals (**Table 1**), [8-11]. The

**Table 1:** Contraindications for herpes zoster vaccination [8-11].

**Allergy: Patients allergic to any component of shingles vaccine, such as:**

**Gelatin**

**Neomycin**

Weakened Immune System: Patients who have or who are receiving:

Chemotherapy

Hematoproliferative malignancies

High dose corticosteroid treatment

HIV infection, CD4+ count <200 cells/ $\mu$ L

Peripheral blood stem cell transplantation recipients <sup>[a]</sup>

Radiation

Other: Patients who have or who are receiving, or who are:

Active, untreated tuberculosis

Anti-TNF biologics <sup>[b]</sup>

Non-TNF biologics <sup>[c]</sup>

Pregnant

[a] Peripheral blood stem cell transplantation recipients who are < 24 months post-transplantation, who still require immunosuppressive therapy, or who have evidence of graft-versus-host-disease should not receive live vaccines [10].

[b] Anti-TNF biologics include adalimumab, certolizumab pegol, etanercept, golimumab, and infliximab [11].

[c] Non-TNF biologics include abatacept, rituximab, and tocilizumab [11].

**Table 2:** Efficacy of herpes zoster vaccine with increasing age [a,b].

Age	50-59 years	60-69 years	70-79 years	≥80 years
Efficacy	69.8%	64%	41%	18%

[a] Table is modified from data in references 12, 22, and 23.

[b] The age group is the age in which the patient received the vaccine. The mean duration of follow up was 3.13 years for those aged 60 years and older [12] and 1.3 years in those aged 50-59 [22].

vaccine has been shown to reduce the incidence of herpes zoster, postherpetic neuralgia; it also reduces the burden of illness among persons of 60 years or older [12-14].

The herpes zoster vaccine is recommended in the United States for immune-competent individuals  $\geq 60$  years. The vaccine is also approved by the Federal Drug Administration (FDA) for adults aged 50-59 years. However, since the incidence of herpes zoster and post-herpetic neuralgia is low at this age, vaccination is not recommended by the Center for Disease Control and Prevention (CDC) for this age group [15].

The CDC recommends administration of the vaccine to those aged 60 and older regardless of history of varicella or herpes zoster infection [8]. Studies by Morrison et al. [16] and Mills et al. [17] support the CDC's guidelines; their investigations concluded that the vaccine is safe to administer in patients with a documented history of herpes zoster [16, 17]. Yawan et al. found the recurrence rate to be approximately 6%, which is near the incidence rate, suggesting that zoster vaccination should be offered to people with previous episodes of herpes zoster to prevent more recurrences [18]. However, Tseng et al. found the recurrence rate in immunocompetent individuals to be much lower [19].

The amount of time that a patient should wait to be vaccinated after a herpes zoster episode remains to be established. Cohen [19] argues that that an immunocompetent individual should wait 3 years following their herpes zoster episode because the risk of recurrent herpes zoster after a recent episode is low [20] and the immune response for 3 years following the episode is similar to that after vaccination [21]. However, it might not be unreasonable to vaccinate earlier than 3 years following the occurrence of zoster.

The incidence of herpes zoster increases with age. Unfortunately, the efficacy of the zoster vaccine declines with increasing age [12-14, 22]. Indeed, the efficacy of Zostavax<sup>®</sup> declines from nearly 70% in individuals aged less than 60 years at the time of their vaccination, to only 18% in those aged 80 and older when vaccinated (**Table 2**), [12, 22, 23].

The vaccine's effectiveness also decreases over time. Tseng et al. found that the efficacy falls from 68.7% in the first year to 4.2% in the eighth year [24]. Another study showed that the decrease in risk of developing zoster is significant for at least 5 years after vaccination [14]. However, a booster dose of the vaccine is currently not recommended [14].

The decline in efficacy of the zoster vaccine presents a problem. Many people who receive the vaccine at age 60 go on to live for many years after vaccination and their risk for development of herpes zoster and post-herpetic neuralgia continues to increase as they age. This suggests the need for a revaccination program in older patients.

Levin et al. found that administering a booster dose of zoster vaccine to adults  $\geq 70$  years who had received their first dose of zoster vaccine  $\geq 10$  years previously elicited a varicella zoster virus antibody response that was non-inferior to that in adults aged  $\geq 70$  years who received their first dose of zoster vaccine [25]. This suggests a potential benefit to a booster for patients following their initial vaccination. Our patient was again vaccinated two months after his zoster infection resolved.

A concern regarding revaccination in patients nearing the older end of the indicated age ( $\geq 80$  years) is the cost-effectiveness of the vaccine. Cost-effectiveness analysis by Gelb in 2007 showed that, given the cost per quality-adjusted life-years gained by vaccine

administration, models of patients vaccinated closer to 60 years old were more cost-effective than models of patients vaccinated at older ages [26]. However, this study, along with other studies analyzing the cost-effectiveness of the herpes zoster vaccine, was performed before the long-term efficacy of the vaccine was known [26-28]

## Conclusion

Herpes zoster is a disease caused by reactivation of the varicella zoster virus. The incidence of herpes zoster increases with advancing age. A vaccine for herpes zoster has proven to be effective in preventing the disease; however, the efficacy declines as patients age. The effectiveness of the vaccine also decreases as the time following vaccination increases. This disparity in efficacy leads to numerous situations, similar to that which occurred in our patient, in which the patient develops zoster following vaccination.

Currently, the CDC recommends only a single dose of the zoster vaccine. Analysis of other individuals with similar scenarios to our patient prompts consideration as to whether booster immunizations or revaccination should be considered in order to provide better immunity with increasing age. More studies are required in order to determine if these methods would be cost-effective and beneficial to our continuously growing aging population.

After consulting with his primary care physician, our patient decided to be revaccinated following his zoster episode. The arguments supporting revaccination are the minimal side effects to the vaccine, and potential benefits in possibly preventing future episodes of zoster. The arguments against revaccination are the cost of the medication and the lower efficacy based on increasing treatment age. From a medical point of view, there is no contraindication to vaccination in immunocompetent elderly individuals. However, from a socioeconomic and evidence-based medicine perspective it may not be cost-effective, considering the likelihood of an elderly patient developing a clinical recurrence.

## References

- Cohen JI, Brunell PA, Straus SE, Krause PR. Recent advances in varicella-zoster virus infection. *Ann Intern Med* 1999;130:922-932. [PMID: 10375341]
- Harpaz R, Ortega-Sanchez IR, Seward JF; Advisory Committee on Immunization Practices (ACIP) Centers for Disease Control and Prevention (CDC). Prevention of herpes zoster: recommendations of the advisory committee on immunization practices (ACIP). *MMWR Recomm Rep* 2008;57:1-30. [PMID: 18528318]
- Yawn BP, Saddier P, Wollan PC, St Sauver JL, Kurland MJ, Sy LS. A population-based study of the incidence and complication rates of herpes zoster before zoster vaccine introduction. *Mayo Clin Proc* 2007;82:1341-1349. [PMID: 17976353].
- Cohen JI. Clinical practice: herpes zoster. *N Engl J Med* 2013;369:255-263. [PMID: 23863052]
- Winthrop KL, Baddley JW, Chen L, Liu L, Grijalva CG, Delzell E, Beukelman T, Patkar NM, Xie F, Saag KG, Herrinton LJ, Solomon DH, Lewis JD, Curtis JR. Association between the initiation of antitumor necrosis factor therapy and the risk of herpes zoster. *JAMA* 2013;309:887-895. [PMID: 23462785]
- Zhang JX, Joesoef RM, Bialek S, Wang C, Harpaz R. Association of physical trauma with risk of herpes zoster among Medicare beneficiaries in the United States. *J Infect Dis* 2013;207:1007-1011. [PMID: 23307932]
- Gauthier A, Breuer J, Carrington D, Martin M, Rémy V. Epidemiology and cost of herpes zoster and post-herpetic neuralgia in the United Kingdom. *Epidemiol Infect* 2009;137:38-47. [PMID: 18466661]
- Kim DK, Bridges CB, Harriman KH. Advisory committee on immunization practices recommended immunization schedule for adults aged 19 years or older – United States, 2016. *Ann Intern Med* 2016; 164:184-194. [PMID: 26829913].
- Bader, MS. Herpes zoster: diagnostic, therapeutic, and preventative approaches. *Postgrad Med* 2013;125:78-91. [PMID: 24113666]
- Tomblyn M, Chiller T, Einsele H, Gress R, Sepkowitz K, Storek J, Wingard JR, Young JA, Boeckh MJ; Center for International Blood and Marrow Research; National Marrow Donor program; European Blood and Marrow Transplant Group; American Society of Blood and Marrow Transplantation; Canadian Blood and Marrow Transplant Group; Infectious Diseases Society of America; Society for Healthcare and Epidemiology of America; Association of Medical Microbiology and Infectious Disease Canada; Center for Disease Control and Prevention. Guidelines for preventing infectious complications among hematopoietic cell transplantation recipients: a global perspective. *Biol Blood Marrow Transplant* 2009;15:1143-1238. [PMID: 19747629]
- Perry LM, Winthrop KL, Curtis JR. Vaccinations for rheumatoid arthritis. *Curr Rheumatol Rep* 2014;16:431. [PMID: 24925587]
- Oxman MN, Levin MJ, Johnson GR, Schmader KE, Straus SE, Gelb LD, Arbeit RD, Simberkoff MS, Gershon AA, Davis LE, Weinberg A, Boardman KD, Williams HM, Zhang JH, Peduzzi PN, et al; Shingles Prevention Study Group. A vaccine to prevent herpes zoster and postherpetic neuralgia in older adults. *N Engl J Med* 2005;352:2271-2284. [PMID: 15930418]
- Morrison VA, Johnson GR, Schmader KE, Levin MJ, Zhang JH, Looney DJ, Betts R, Gelb L, Guatelli JC, Harbecke R, Pachucki C, Keay S, Menzies B, Griffin MR, Kauffman CA, Marques A, Toney J, Boardman K, Su SC, Li X, Chan IS, Parrino J, Annunziato P, Oxman MN; Shingles Prevention Study Group. Long-term persistence of zoster vaccine efficacy. *Clin Infect Dis* 2015;60:900-909. [PMID: 25416754]
- Schmader KE, Oxman MN, Levin MJ, Johnson G, Zhang JH, Betts R, Morrison VA, Gelb L, Guatelli JC, Harbecke R, Pachucki C, Keay S, Menzies B, Griffin MR, Kauffman C, Marques A, Toney J, Keller PM, Li X, Chan IS, Annunziato P; Shingles Prevention Study Group. Persistence of the efficacy of zoster vaccine in the shingles prevention study and the short-term persistence substudy. *Clin Infect Dis* 2012;55:1320-1328. [PMID: 22828595]
- Le P, Rothberg MB. Cost-effectiveness of herpes zoster vaccine for persons aged 50 years. *Ann Intern Med* 2015;163:489-497. [PMID: 26344036]
- Morrison VA, Oxman MN, Levin MJ, Schmader KE, Guatelli JC, Betts

- RF, Gelb LD, Pachucki CT, Keay Sk, Menzies B, Griffin MR, Kauffman CA, Marques AR, Toney JF, Simberkoff MS, Serrao R, Arbeit RD, Gnann JW, Greenberg RN, Holodniy M, Keitel WA, Yeh SS, Davis LE, Crawford GE, Neuzil KM, Johnson GR, Zhang JH, Harbecke R, Chan IS, Keller PM, Williams HM, Boardman KD, Silber JL, Annunziato PW; Shingles Prevention Study Group. Safety of zoster vaccine in elderly adults following documented herpes zoster. *J Infect Dis* 2013;208:559-563. [PMID: 23633406]
17. Mills R, Tyring SK, Levin MJ, Parrino J, Li X, Stek JE, Schlienger K, Chan IS, Silber JL. Safety, tolerability, and immunogenicity of zoster vaccine in subjects with a history of herpes zoster. *Vaccine* 2010;28:4204-4209. [PMID: 20416263]
  18. Yawn BP, Wollan PC, Kurland MJ, St Sauver JL, Saddier P. Herpes zoster recurrences more frequent than previously reported. *Mayo Clin Proc* 2011;86:88-93. [PMID: 21220354]
  19. Cohen JI. Herpes zoster. *N Engl J Med* 2013;369:1766-1767. [PMID: 24171531]
  20. Tseng HF, Chi M, Smith N, Marcy SM, Sy LS, Jacobsen SJ. Herpes zoster vaccine and the incidence of recurrent herpes zoster in an immunocompetent elderly population. *J Infect Dis* 2012;206:190-196. [PMID: 22669900]
  21. Weinberg A, Zhang JH, Oxman MN, Johnson GR, Hayward AR, Caulfield MJ, Irwin MR, Clair J, Smith JG, Stanley H, Marchese RD, Harbecke R, Williams HM, Chan IS, Arbeit RD, Gershon AA, Schödel F, Morrison VA, Kauffman CA, Straus SE, Schmader KE, Davis LE, Levin MJ; US Department of Veterans Affairs (VA) Cooperative Studies Program Shingles Prevention Study Investigators. Varicella-zoster virus-specific immune responses to herpes zoster in elderly participants in a trial of a clinically effective zoster vaccine. *J Infect Dis* 2009;200:1068-1077. [PMID: 19712037]
  22. Schmader KE, Levin MJ, Gnann JW Jr, McNeil SA, Vesikari T, Betts RF, Keay S, Stek JE, Bundick ND, Su SC, Zhao Y, Li X, Chan IS, Annunziato PW, Parrino J. Efficacy, safety, and tolerability of herpes zoster vaccine in persons aged 50-59 years. *Clin Infect Dis* 2012;54:922-928. [PMID: 22291101]
  23. Zostavax® [package insert]. Whitehouse Station, NJ: Merck Sharp & Dohme Corp; 2014.
  24. Tseng HF, Harpaz R, Luo Y, Hales CM, Sy LS, Tartof SY, Bialek S, Hechter RC, Jacobsen SJ. Declining effectiveness of herpes zoster vaccine in adults aged  $\geq 60$  years. *J Infect Dis* 2016;213:1872-1875. [PMID: 26908728]
  25. Levin MJ, Schmader KE, Pang L, Williams-Diaz A, Zerbe G, Canniff J, Johnson MJ, Caldas Y, Cho A, Lang N, Su SC, Parrino J, Popmihajilov Z, Weinberg A. Cellular and humoral responses to a second dose of herpes zoster vaccine administered 10 years after the first dose among older adults. *J Infect Dis* 2016;213:14-22. [PMID: 26452397]
  26. Gelb LD. Preventing herpes zoster through vaccination. *Ophthalmology* 2008;115:535-38. [PMID: 18243932]
  27. Pellissier JM, Brisson M, Levin MJ. Evaluation of the cost-effectiveness in the United States of a vaccine to prevent herpes zoster and postherpetic neuralgia in older adults. *Vaccine* 2007;25:8326-8337. [PMID: 17980938]
  28. Hornberger J, Robertus K. Cost-effectiveness of a vaccine to prevent herpes zoster and postherpetic neuralgia in older adults. *Ann Intern Med* 2006;145:317-325. [PMID: 16954357]