

# UC Davis

## Dermatology Online Journal

### Title

Paclitaxel-induced dorsal hand-foot syndrome

### Permalink

<https://escholarship.org/uc/item/9jm0x1rq>

### Journal

Dermatology Online Journal, 29(3)

### Authors

Quan, Eugenie Y  
Engel, Casey  
Rush, Patrick S  
et al.

### Publication Date

2023

### DOI

10.5070/D329361434

### Copyright Information

Copyright 2023 by the author(s). This work is made available under the terms of a Creative Commons Attribution-NonCommercial-NoDerivatives License, available at <https://creativecommons.org/licenses/by-nc-nd/4.0/>

Peer reviewed

# Paclitaxel-induced dorsal hand-foot syndrome

Eugenie Y Quan<sup>1</sup> MD, Casey Engel<sup>2</sup> BA, Patrick S Rush<sup>1,3</sup> DO, Joshua D Eikenberg<sup>1</sup> MD

Affiliations: <sup>1</sup>Section of Dermatology, Department of Internal Medicine, Virginia Tech Carilion School of Medicine, Roanoke, Virginia, USA, <sup>2</sup>Virginia Tech Carilion School of Medicine, Roanoke, Virginia, USA, <sup>3</sup>Department of Basic Science Education, Virginia Tech Carilion School of Medicine, Roanoke, Virginia, USA

Corresponding Author: Eugenie Y Quan MD, Section of Dermatology, Department of Internal Medicine, Virginia Tech Carilion School of Medicine, 1 Riverside Circle, Suite 300, Roanoke, VA 24016, Tel: 540-224 5170, Email: [quaney@vcu.edu](mailto:quaney@vcu.edu)

## Abstract

Hand-foot syndrome (HFS), also known as palmoplantar erythrodysesthesia or acral erythema, is a known adverse effect of chemotherapeutic agents that most commonly presents as palmoplantar dysesthesia and erythematous plaques localized to the palms and soles. Paclitaxel is an uncommon cause of HFS and is notable for its unique presentation on the dorsal hands and feet. We present an unusual case of paclitaxel-induced HFS localized to the dorsal hands of a 66-year-old man with metastatic angiosarcoma. Early identification and management of HFS is critical to allow for continuation of chemotherapy while improving patient quality of life.

*Keywords: acral erythema, chemotherapy, hand-foot, paclitaxel, palmoplantar erythrodysesthesia, toxic erythema*

## Introduction

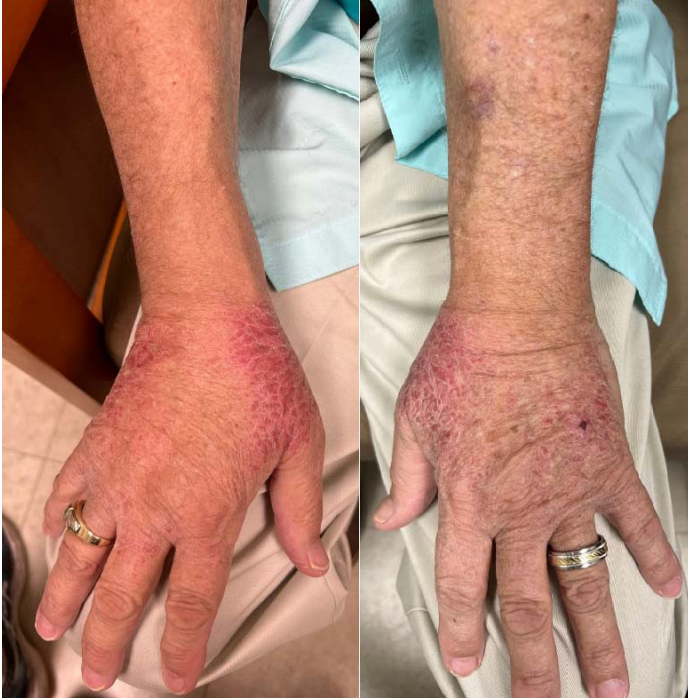Hand-foot syndrome (HFS), also known as palmoplantar erythrodysesthesia or acral erythema, is a known adverse effect of chemotherapeutic agents and is characterized by palmoplantar dysesthesia and well-demarcated erythematous plaques most commonly involving the palms and soles. The incidence of HFS ranges from 6% to 64% and is most frequently associated with pegylated liposomal doxorubicin, capecitabine, 5-fluorouracil, cytarabine, and docetaxel [1]. Paclitaxel is an uncommon cause of HFS. We report a 66-year-old

man with metastatic angiosarcoma treated with paclitaxel who developed HFS localized only to the dorsal hands.

## Case Synopsis

A 66-year-old man with a history of multifocal hepatic angiosarcoma was initiated on single-agent paclitaxel. One week after completing six weekly doses of paclitaxel, he developed a rash on his bilateral dorsal hands. The patient reported paresthesia and numbness localized to the area of the rash and at his fingertips. The patient did not notice improvement with application of OTC topical hydrocortisone.

Physical examination showed erythematous scaly plaques symmetrically distributed on the medial and lateral aspects of the bilateral dorsal hands (**Figure 1**). Numbness was present within the plaques, but sensation was intact in the skin directly adjacent to the plaques. The palms and feet were clear of rash. This presentation was consistent with grade two severity of HFS according to the National Cancer Institute Common Terminology Criteria for Adverse Events. Histopathologic examination demonstrated areas of parakeratosis with hypergranulosis, occasional dyskeratotic keratinocytes in the basilar cell layer and superficial aspects of the eccrine ducts, and papillary dermal extravasation of red blood cells (**Figure 2**). The diagnosis of hand-foot syndrome was made. The patient significantly improved with clobetasol 0.05% cream and was then transitioned to 10% urea cream for preventive maintenance. The patient was continued on paclitaxel.

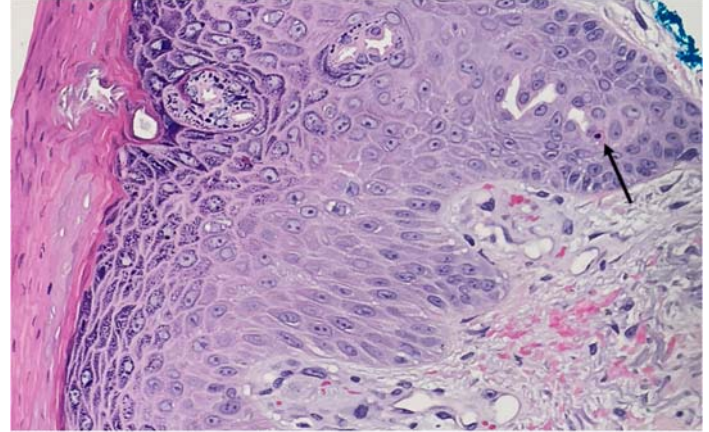


**Figure 1.** Erythematous scaly plaques symmetrically distributed on the medial and lateral aspects of the bilateral dorsal hands.

## Case Discussion

Hand-foot syndrome is a well-documented adverse effect of chemotherapeutic agents. It classically presents with well-demarcated erythematous plaques and edema of the palms and soles accompanied by palmoplantar dysesthesia, such as tingling and burning pain [2]. Erythema can progress to blistering, erosion, or ulcerations [1]. These symptoms can oftentimes significantly impact quality of life and may necessitate discontinuation of treatment.

The incidence of HFS may be as high as 50% to 60% for certain chemotherapeutic agents, such as capecitabine and pegylated liposomal doxorubicin [1]. Hand-foot syndrome occurs in 5-10% of patients treated with taxanes and even more rarely occurs with paclitaxel when compared to docetaxel [3]. Taxanes are cytotoxic anti-microtubule agents that ultimately arrest mitosis [4]. They are a preferred treatment for angiosarcoma [5]. Dermatologic adverse events are common, although the true incidence is not known. They include HFS, flexural and intertriginous rashes, morbilliform rashes, pustular eruptions, drug-induced lupus erythematosus, scleroderma-like changes, radiation



**Figure 2.** Parakeratosis with coarse hypergranulosis, occasional dyskeratotic keratinocyte (indicated by black arrow) in the superficial aspect of the eccrine duct, and papillary dermal extravasation of red blood cells.

and UV recall, pigmentary changes such as reticulate hyperpigmentation, edema, alopecia, subungual pyogenic granulomas, onycholysis, and mucositis [3,6-8]. Taxane-induced HFS is particularly notable for its unique presentation involving the dorsal hands and feet [3]. There are several case reports of paclitaxel-induced HFS. They are most notable for varying distributions of scaly erythematous plaques including involvement of the entire dorsal surfaces of the bilateral hands [9], both the dorsal hands and the soles [10], both the palms and the dorsal feet [11], the dorsal hands and palms as well as the soles [12], only the lateral surfaces of the dorsal feet [13], in a dermatomyositis-like distribution on the metacarpalphalangeal joints and interphalangeal joints [14], and on sun-exposed areas [15].

The pathophysiology of HFS is poorly understood, but it is believed to occur due to direct cytotoxic effect on keratinocytes with preferential secretion of chemotherapeutic agents by the eccrine ducts leading to predominant involvement of the palms and soles [1]. Other suggested mechanisms include increased trauma, rich capillary networks, and keratinocyte turnover of the palms and soles [1]. As these hypotheses do not explain the dorsal localization of HFS seen with paclitaxel, sun exposure may likely be a contributing factor [3].

Paclitaxel-induced photosensitive dermatoses include photo-distributed erythema multiforme, photo-onycholysis, UV recall phenomenon, and

subacute cutaneous lupus erythematosus [16,17]. There are also several reported cases of paclitaxel-induced photosensitivity [17,18]. One case demonstrated elevated urinary and erythrocyte porphyrins in a patient with metastatic breast cancer who was treated with paclitaxel and trastuzumab and developed photo-distributed erythema multiforme and onycholysis. Discontinuation of paclitaxel led to resolution of the rash and normalization of porphyrin levels [19]. A case series demonstrated aberrant porphyrin biosynthesis in several patients treated with paclitaxel; however, photosensitivity was not seen in all patients with elevated porphyrins [20]. It remains unclear whether the aberrations in porphyrin biosynthesis is causative or an epiphenomenon in the development of paclitaxel-induced photosensitivity.

Management of HFS is case dependent. Grade one HFS may be managed symptomatically, whereas more severe cases may require dose reduction, treatment interruption, or an alternative chemotherapeutic regimen; symptoms usually

improve within one to two weeks. Avoidance of sun exposure, hot water, friction, and trauma may be helpful in preventing HFS [1]. Treatment is largely supportive and includes use of high-potency topical corticosteroids, urea-based creams, regional cooling, wound care, and pain control [1].

## Conclusion

We presented a case of paclitaxel-induced HFS localized to the dorsal hands. Clinicians should be aware of paclitaxel as an uncommon cause of HFS and its unique presentation on the dorsal hands and feet. Early identification and management of paclitaxel-induced HFS can minimize interruptions in chemotherapy, while maintaining patient quality of life, as in our case.

## Potential conflicts of interest

The authors declare no conflicts of interest.

## References

1. Miller KK, Gorcey L, McLellan BN. Chemotherapy-induced hand-foot syndrome and nail changes: a review of clinical presentation, etiology, pathogenesis, and management. *J Am Acad Dermatol*. 2014;71:787-794. [PMID: 24795111].
2. Cohen PR. Acral erythema: a clinical review. *Cutis*. 1993;51:175-179. [PMID: 8444048].
3. Sibaud V, Lebœuf NR, Roche H, et al. Dermatological adverse events with taxane chemotherapy. *Eur J Dermatol*. 2016;26:427-443. [PMID: 27550571].
4. Pazdur R, Kudelka AP, Kavanagh JJ, Cohen PR, Raber MN. The taxoids: paclitaxel (Taxol) and docetaxel (Taxotere). *Cancer Treat Rev*. 1993;19:351-386. [PMID: 8106152].
5. Goerdt LV, Schneider SW, Booken N. Cutaneous Angiosarcomas: Molecular Pathogenesis Guides Novel Therapeutic Approaches. *J Dtsch Dermatol Ges*. 2022;20:429-443. [PMID: 35218306].
6. Cohen PR. Paclitaxel-associated reticulate hyperpigmentation: Report and review of chemotherapy-induced reticulate hyperpigmentation. *World J Clin Cases*. 2016;4:390-400. [PMID: 28035312].
7. Paul LJ, Cohen PR. Paclitaxel-associated subungual pyogenic granuloma: report in a patient with breast cancer receiving paclitaxel and review of drug-induced pyogenic granulomas adjacent to and beneath the nail. *J Drugs Dermatol*. 2012;11:262-268. [PMID: 22270214].
8. Payne JY, Holmes F, Cohen PR, Gagel R, Buzdar A, Dhingra K. Paclitaxel: severe mucocutaneous toxicity in a patient with hyperbilirubinemia. *South Med J*. 1996;89:542-545. [PMID: 8638189].
9. Zelman B, Lee K, Reserva J, Speiser J. A paclitaxel-induced variant of hand-foot syndrome affecting dorsal surfaces. *J Cutan Pathol*. 2021;48:1320-1323. [PMID: 33938036].
10. Kataria PS, Kendre PP, Patel AA, Tahiliani N, Bhargav V, Parekh H. Rare occurrence of hand-foot syndrome due to paclitaxel: A rare case report. *Indian J Pharmacol*. 2018;50:284-286. [PMID: 30636833].
11. Ben Abdallah I, Ben Nasr S, Zribi A, et al. An unusual and severe case of paclitaxel-induced hand-foot syndrome. *Clin Case Rep*. 2020;9:594-596. [PMID: 33489227].
12. Wahab A, Khakwani M, Ehsan H, Bellam N. Paclitaxel-Induced Palmar-Plantar Erythrodysesthesia. *Cureus*. 2020;12:e11507. [PMID: 33214972].
13. Richards KN, Ivan D, Rashid RM, Chon SY. Paclitaxel-Induced Acral Erythema. *Arch Dermatol*. 2012;148:1333-1334. [PMID: 23165853].
14. Housholder AL, Adams BB. Chemotherapy-induced acral erythema sparing the palms. *J Am Acad Dermatol*. 2012;67:e116-e117. [PMID: 22890739].
15. Assi HA, Ayoub ZA, Jaber SM, Sibai HA, El Saghir NS. Management of Paclitaxel-induced hand-foot syndrome. *Breast Care (Basel)*. 2013;8:215-217. [PMID: 24415973].
16. Cohen PR. Photodistributed erythema multiforme: paclitaxel-related, photosensitive conditions in patients with cancer. *J Drugs Dermatol*. 2009;8:61-64. [PMID: 19180897].
17. Beutler BD, Cohen PR. Nab-paclitaxel-associated photosensitivity: report in a woman with non-small cell lung cancer and review of taxane-related photodermatoses. *Dermatol Pract Concept*. 2015;5:121-124. [PMID: 26114068].

18. Mahajan VK, Sharma V, Wadhwa D. Photodermatitis in a woman with infiltrating intraductal breast carcinoma: An uncommon adverse cutaneous drug reaction of paclitaxel revisited. *Indian J Pharmacol.* 2020;52:430-434. [PMID: 33283775].
19. Cohen AD, Mermershtain W, Geffen DB, et al. Cutaneous photosensitivity induced by paclitaxel and trastuzumab therapy associated with aberrations in the biosynthesis of porphyrins. *J Dermatolog Treat.* 2005;16:19-21. [PMID: 15897162].
20. Tokunaga M, Iga N, Endo Y, et al. Elevated protoporphyrin in patients with skin cancer receiving taxane chemotherapy. *Eur J Dermatol.* 2013;23:826-829. [PMID: 24480579].