

UC Davis
Dermatology Online Journal

Title

Skin-limited relapse of systemic anaplastic large-cell lymphoma

Permalink

<https://escholarship.org/uc/item/9gz970jm>

Journal

Dermatology Online Journal, 22(12)

Authors

Farhadian, Joshua A
Terushkin, Vitaly
Meehan, Shane A
et al.

Publication Date

2016

DOI

10.5070/D32212033374

Copyright Information

Copyright 2016 by the author(s). This work is made available under the terms of a Creative Commons Attribution-NonCommercial-NoDerivatives License, available at <https://creativecommons.org/licenses/by-nc-nd/4.0/>

Peer reviewed

Skin-limited relapse of systemic anaplastic large-cell lymphoma

Joshua A. Farhadian, MD, Vitaly Terushkin, MD, Shane A. Meehan, MD, Craig Kornreich, MD

Ronald O. Perelman Department of Dermatology, NYU School of Medicine, NYU Langone Medical Center

Abstract

Anaplastic large-cell lymphomas (ALCLs) are a group of CD30-positive non-Hodgkin lymphomas that are linked by common morphologic and immunophenotypic features but have varying clinical and genetic characteristics. The World Health Organization classification currently recognizes three subtypes of ALCL: systemic anaplastic lymphoma kinase-positive ALCL, systemic anaplastic lymphoma kinase-negative (ALK-) ALCL, and primary cutaneous ALCL. Here we present a 42-year-old man with a history of systemic ALK- ALCL, who was in remission for six months before relapsing with skin-limited anaplastic large-cell lymphoma.

Case Presentation

PATIENT: 42-year-old man

DURATION: Four months

DISTRIBUTION: Suprapubic area, arms, and legs

HISTORY: A 42-year-old man with a past medical history of systemic anaplastic large-cell lymphoma in remission presented to the Skin and Cancer Unit for evaluation of new erythematous and violaceous papules and nodules with central crusts on his arms and legs. The lesions were variably painful when pressed. At the time, physical examination was consistent with a diagnosis of pityriasis lichenoides et varioliformis acuta, and a biopsy confirmed this diagnosis. The patient was started on clobetasol propionate ointment and a one-month course of doxycycline. While completing this course of antibiotic, he developed a new, similar appearing

lesion on his right thigh that showed increased fluorodeoxyglucose uptake on a screening positron emission tomography scan. The patient also developed additional lesions on the legs, left axilla, and left suprapubic area. Punch biopsies were taken from representative lesions on the left suprapubic area. The patient was subsequently treated by his oncologist with six cycles of brentuximab vedotin followed by an allogenic peripheral stem-cell transplant. After this therapy, he experienced a nearly complete resolution of the skin papules and nodules.

Six months prior to his initial presentation, the patient was diagnosed with anaplastic lymphoma kinase-negative systemic anaplastic large-cell lymphoma and treated with four courses of cytarabine, vincristine, adriamycin, and dexamethasone, which alternated with four doses of high-dose methotrexate and cytarabine. The patient subsequently went into remission. He then underwent consolidation with carmustine, etoposide, cytarabine, and melphalan, which was followed by an autologous stem-cell transplant.

PHYSICAL EXAMINATION: Variably-sized, erythematous papules and nodules with central eschars and peripheral scale were present on the arms, legs, and suprapubic area (**Figure 1**).

LABORATORY DATA: A bone-marrow biopsy was normal. Hemoglobin was 10.6 g/dL, and platelet count was 133 K/uL. A comprehensive metabolic panel was normal. Lactate dehydrogenase was normal. Bacterial, fungal, and acid-fast bacilli tissue cultures were negative. A positron-emission tomography scan showed intense

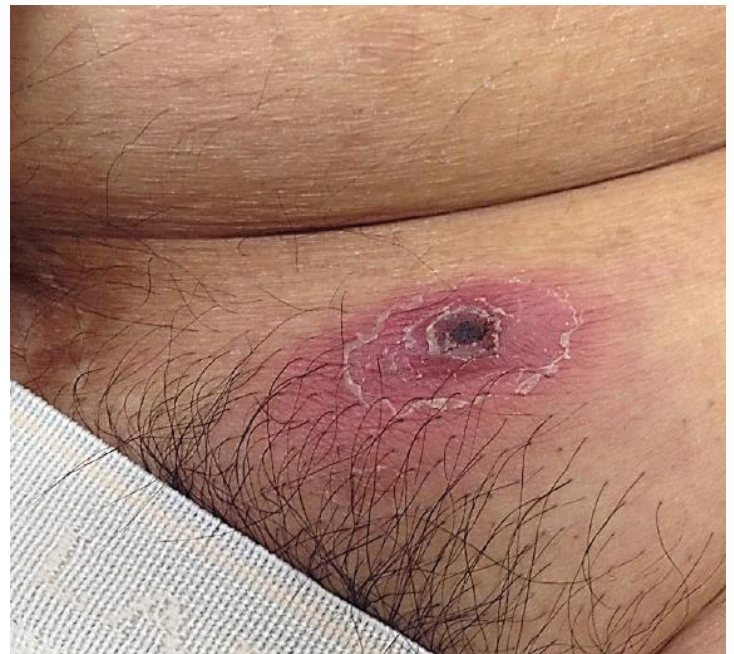
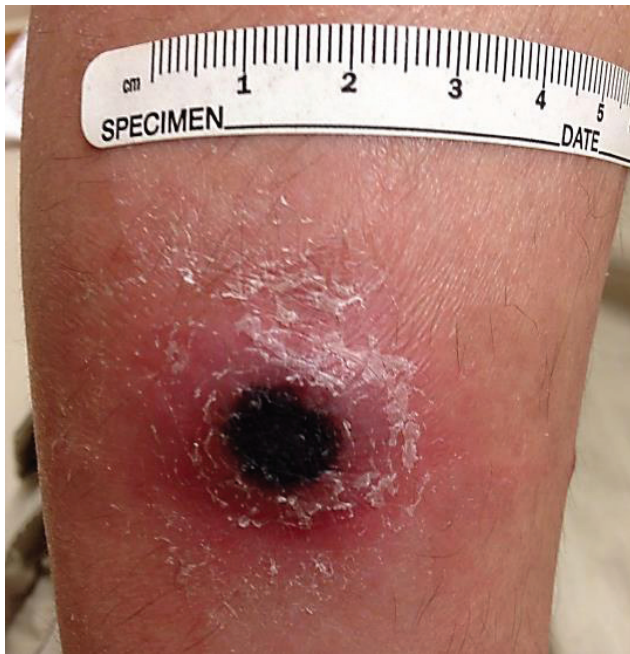
Figure 1. Variably-sized, erythematous papules and nodules with central eschars and peripheral scale were present on the arms, legs, and suprapubic area.

fluorodeoxyglucose uptake that was associated with skin thickening in the medial aspect of the left upper thigh.

HISTOPATHOLOGY: Throughout the dermis, there is a diffuse infiltrate of atypical lymphocytes that are characterized by enlarged nuclei with irregular nuclear contours and coarse chromatin. The majority of atypical lymphocytes react for CD30 (**Figure 2**).

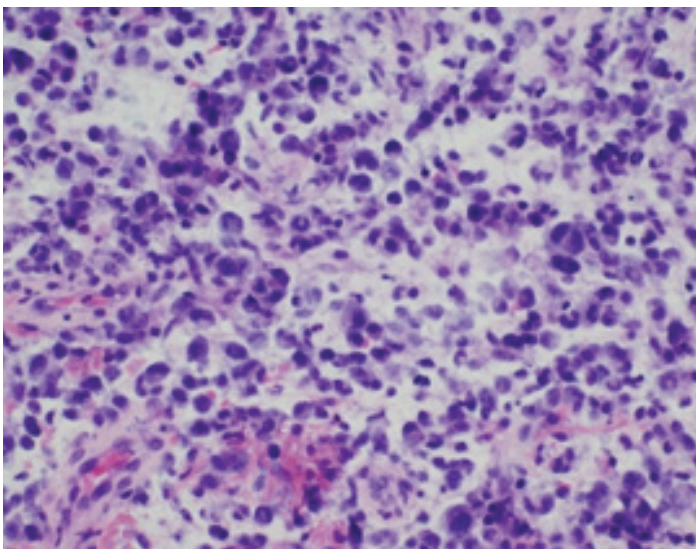


Figure 2. Diffuse dermal infiltrate of atypical lymphocytes that are characterized by enlarged nuclei with irregular nuclear contours and coarse chromatin.

DIAGNOSIS: Skin-limited relapse of systemic anaplastic large-cell lymphoma

Discussion

Anaplastic large-cell lymphomas (ALCLs) are a group of CD30-positive non-Hodgkin lymphomas (NHLs) linked by common morphologic and immunophenotypic features but with varying clinical and genetic characteristics [1]. The World Health Organization classification currently recognizes three subtypes of ALCL: anaplastic lymphoma kinase-positive (ALK+) ALCL, anaplastic lymphoma kinase-negative (ALK-) ALCL, and primary cutaneous ALCL (pcALCL [2]). The first two are systemic diseases whereas the latter presents in the skin. ALCLs are usually considered peripheral T-cell lymphomas, but some ALCLs lack expression of T-cell antigens and/or detectable gene rearrangements. The cell of origin for these unclassifiable tumors has not been determined [1].

Systemic ALCLs comprise approximately 3% of all adult NHLs and 10 to 20% of childhood lymphomas [3]. ALK+ ALCL is associated with an NPM-ALK t(2;5) translocation, which is highly correlated with the identification of the ALK protein by immunohistochemical analysis [4]. ALK+ ALCL typically occurs in younger patients and has a five-year survival rate of 70 to 90%, while ALK- ALCL occurs in older patients and has a five-year survival rate of 40 to 60% [5]. Emerging data suggest that ALK- ALCL is heterogeneous, with a subset of cases having either a DUSP22 translocation and a survival rate similar to ALK+ ALCL or a less

common but more aggressive P63 translocation [6]. Anthracycline-based regimens, such as cyclophosphamide, doxorubicin, vincristine, and prednisone (CHOP), remain the standard first-line treatment for systemic ALCL, but, in many patients with ALK- ALCL, it is ineffective and followed by autologous stem-cell transplantation [5]. The anti-CD30 antibody drug conjugate, brentuximab vedotin, is associated with an 86% response rate and durable remission in relapsed/refractory ALCL [7].

pcALCL represents one of two types of primary cutaneous CD30-positive T-cell lymphoproliferative disorders; the other is lymphomatoid papulosis (LyP). These two entities are thought to exist along a spectrum in which LyP is more indolent and pcALCL is more aggressive. pcALCL resembles systemic ALCL but arises in the skin. Patients present with cutaneous nodules, with or without ulcers, which are localized in about 80% of patients and multifocal in about 20%. To make the diagnosis of pcALCL, more than 75% of tumor cells must be CD30-positive. Monoclonal arrangement of the T-cell receptor also is usually observed [8]. Histopathologic features of pcALCL include a diffuse non-epidermotropic infiltrate with cohesive sheets of large CD30-positive tumor cells. Typically, these cells have the characteristic morphology of anaplastic cells, with round, oval, or irregularly-shaped nuclei; prominent eosinophilic nucleoli; and abundant cytoplasm [8, 9]. In contrast to systemic ALCL, pcALCL has a favorable prognosis, with a five-year survival rate of 76 to 96% [10]. Locoregional lymph node involvement does not change prognosis when compared to skin-limited disease [11]. Cutaneous relapse occurs in 39% of patients and extracutaneous spread in 13% of patients [12].

Diagnostic evaluation of pcALCL should include a complete blood count and differential analysis; blood chemistries, which include lactate dehydrogenase level; and serology for human T-lymphotropic viruses-1 and 2 (only in endemic

areas) to identify adult T-cell leukemia/lymphoma, which also can be CD30-positive. Radiologic imaging with contrast-enhanced computed tomography scan with or without positron-emission tomography (PET) or whole body integrated positron-emission tomography should be performed to evaluate for systemic involvement [9, 11]. A lymph node biopsy is advised if there is evidence of nodal disease. Recent evidence suggests that bone-marrow examination has limited value in patients with skin-limited disease and should be reserved for those with multifocal tumors, extracutaneous disease, or unexplained abnormal hematologic results [13, 14]. Patients presenting with a solitary lesion or a few lesions should be treated with radiotherapy. However, if a lesion has been excised or spontaneously resolves, no further treatment is necessary. Patients with multifocal skin lesions may be treated with radiotherapy or low-dose methotrexate. Doxorubicin-based, multi-agent chemotherapy should be considered for those with rapidly progressive disease, extracutaneous involvement, or extensive lesions on one or both legs, which is associated with an unfavorable prognosis [10, 11].

This patient had a history of systemic ALK- ALCL in remission following an autologous stem-cell transplant. It is unclear what proportion of such patients relapse with skin-limited disease, as did our patient, since no similar cases have been previously reported. It is of particular interest that neither a PET scan nor bone-marrow analysis showed evidence of systemic disease. Dermatologists and oncologists should be aware of this potential manifestation of relapsed systemic ALCL as it could easily be confused with benign skin conditions, such as pityriasis lichenoides et varioliformis acuta.

References

1. Xing X, Feldman AL. Anaplastic large-cell lymphomas: ALK positive, ALK negative, and primary cutaneous. *Adv Anat Pathol* 2015; 22: 29
2. Swerdlow S, et al. WHO classification of tumours of haematopoietic and lymphoid tissues, 4th ed. France: IARC Press; 2008: 439
3. Mora J, et al. Large-cell non-Hodgkin lymphoma of childhood: analysis of 78 consecutive patients enrolled in 2 consecutive protocols at the Memorial Sloan- Kettering Cancer Center. *Cancer* 2000; 88: 186
4. Cools J, et al. Identification of novel fusion partners of ALK, the anaplastic lymphoma kinase, in anaplastic large-cell lymphoma and inflammatory myofibroblastic tumor. *Genes Chromosomes Cancer* 2002; 34: 354
5. Hapgood G, Savage KJ. The biology and management of systemic anaplastic large cell lymphoma. *Blood* 2015; 126: 17
6. Parrilla Castellar ER, et al. ALK-negative anaplastic large-cell lymphoma is a genetically heterogeneous disease with widely disparate clinical outcomes. *Blood* 2014; 124: 1473
7. Pro B, et al. Brentuximab vedotin (SGN-35) in patients with relapsed or refractory systemic anaplastic large-cell lymphoma: results of a phase II study. *J Clin Oncol* 2012; 30: 2190
8. Perry E, et al. Primary cutaneous anaplastic large-cell lymphoma. *Am J Clin Oncol* 2013; 36: 526
9. Willemze R, et al. WHO-EORTC classification for cutaneous lymphomas. *Blood* 2005; 105: 3768
10. Benner MF, Willemze R. Applicability and prognostic value of the new TNM classification system in 135 patients with primary cutaneous anaplastic large cell lymphoma. *Arch Dermatol* 2009; 145: 1399
11. Bekkenk MW, et al. Primary and secondary cutaneous CD30(+) lymphoproliferative disorders: a report from the Dutch Cutaneous Lymphoma Group on the long-term follow-up data of 219 patients and guidelines for diagnosis and treatment. *Blood* 2000; 95: 3653
12. Liu HL, et al. CD30+ cutaneous lymphoproliferative disorders: the Stanford experience in lymphomatoid papulosis and primary cutaneous anaplastic large cell lymphoma. *J Am Acad Dermatol* 2003; 49: 1049
13. Benner MF, Willemze R. Bone marrow examination has limited value in the staging of patients with an anaplastic large-cell lymphoma first presenting in the skin: retrospective analysis of 107 patients. *Br J Dermatol* 2008; 159: 1148
14. Kempf W, et al. EORTC, ISCL, and USCLC consensus recommendations for the treatment of primary cutaneous CD30-positive lymphoproliferative disorders: lymphomatoid papulosis and primary cutaneous anaplastic large-cell lymphoma. *Blood* 2011; 118: 4024