

# UC Davis

## Dermatology Online Journal

### Title

Modified keystone flap used to repair nose defect after Mohs micrographic surgery

### Permalink

<https://escholarship.org/uc/item/98q9474t>

### Journal

Dermatology Online Journal, 28(4)

### Authors

Lobos, C  
Machado, S  
Bazzano, C  
et al.

### Publication Date

2022

### DOI

10.5070/D328458530

### Copyright Information

Copyright 2022 by the author(s). This work is made available under the terms of a Creative Commons Attribution-NonCommercial-NoDerivatives License, available at <https://creativecommons.org/licenses/by-nc-nd/4.0/>

Peer reviewed

# Modified keystone flap used to repair nose defect after Mohs micrographic surgery

C Lobos<sup>1</sup> MD, S Machado<sup>1</sup> MD, C Bazzano<sup>1,2</sup> MD, J Magliano<sup>1,2</sup> MD MSC

Affiliations: <sup>1</sup>Cátedra de Dermatología, Universidad de la República, Montevideo, Uruguay, <sup>2</sup>Dermatologic Surgery Unit, Department of Dermatology, Hospital de Clínicas "Dr. Manuel Quintela," Montevideo, Uruguay

Corresponding Author: Constanza Lobos MD, Rambla Armenia 1641, Montevideo 11300, Uruguay, Tel: 598-97411435, Email: [constanza.lobos797@gmail.com](mailto:constanza.lobos797@gmail.com)

## Abstract

Mohs micrographic surgery (MMS) is a surgical technique used to remove skin tumors with a complete evaluation of the margins. The keystone flap technique is generally used to repair large surgical defects on limbs. We present a case where a modified keystone flap technique was used to close a large defect after Mohs micrographic surgery in a patient with a basal cell carcinoma on the nose. An excellent functional and aesthetic result was obtained with no complications during or after the procedure. We offer a novel indication for this technique for surgical defects in this area.

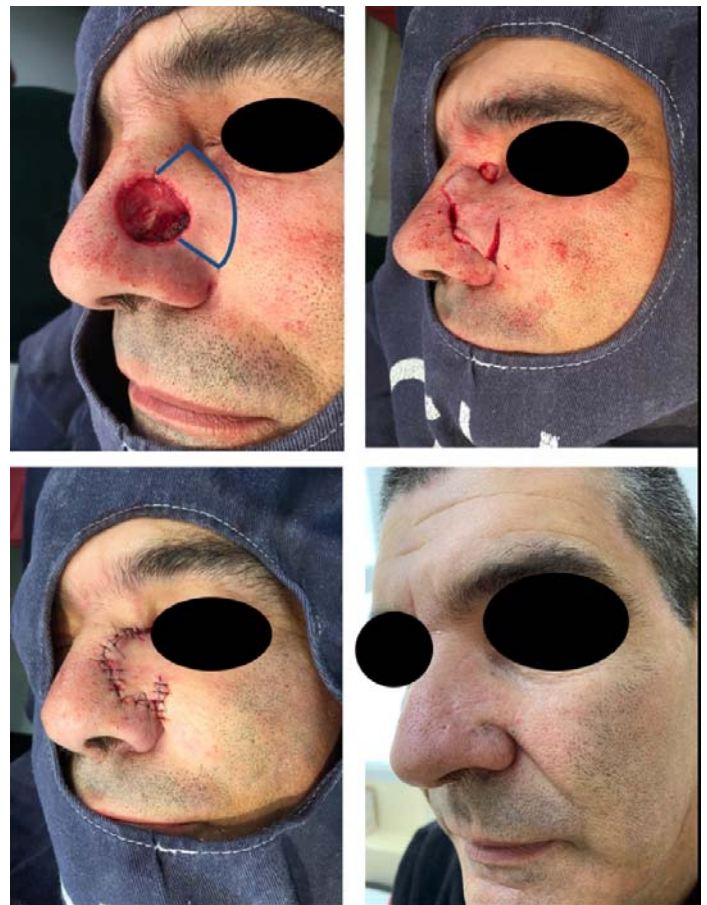*Keywords: basal cell, carcinoma, keystone flap, keystone flap, micrographic surgery, modified, Mohs*

## Introduction

Mohs micrographic surgery (MMS) is the gold standard treatment modality for skin cancers, including basal cell carcinomas (BCC) and squamous cell carcinomas, particularly in high-risk areas. A complete evaluation of the margins grants the highest cure rates while avoiding large deformities of the skin caused by wider margins of excision that can occur with conventional surgery [1].

Large surgical defects can be repaired with different techniques, such as grafts and flaps. With flaps, the keystone flap has been an option most frequently used on limbs when simple closure is not feasible. Modifications of this technique have also been

described with good outcomes. We present a case in which the modified keystone flap is used to repair a MMS surgical defect in a patient with a BCC on the nose.

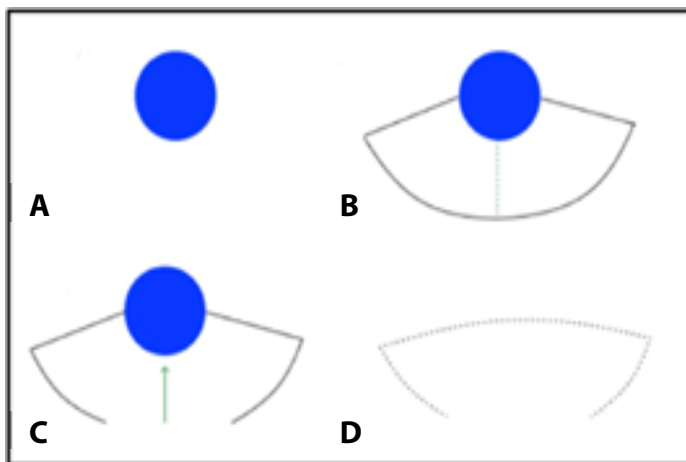


**Figure 1.** **A)** Surgical defect of 2.1 centimeters of diameter and delimitation of modified keystone flap technique. **B)** Advancement of the island that shows how it covers the entire defect with minimal tension. **C)** Immediate post-surgery defect repaired. **D)** Barely-visible scar one year after the procedure.

## Case Synopsis

An otherwise healthy 51-year-old man presented with a nodular BCC on the left nasal dorsum. It measured 1.8 centimeters in diameter and required one stage of MMS to achieve tumor-free margins. The resulting surgical defect had a diameter of 2.1 centimeters (**Figure 1A**). Considering the functional and aesthetic concerns of the patient, we decided to repair it using a modified keystone flap, with a design described in **Figure 2**. The flap was undermined subcutaneously, one centimeter around the design, taking special care not to cut the bridge of intact skin that was left to dissect this area subcutaneously as well. (**Figure 2**).

The closure was generated in a V-Y manner, obtaining more cutaneous laxity, which allows the



**Figure 2.** Schematic diagram of type I modified keystone flap used in our patient. **A)** Surgical defect to be reconstructed. **B)** An arch parallel to the defect was drawn, giving the flap width of 1.5 times the defect's width. Lateral borders joining the arch had approximately  $60.50^\circ$  forming a "V." **C)** Arch's outer thirds and lateral borders were incised, leaving a bridge of intact skin in the central part of the major axis of the flap. This area was subcutaneously dissected. The flap was placed into the surgical defect, and redundant skin was repaired. **D)** Final result after suture.

## References

1. Shriner DL, McCoy DK, Goldberg DJ, Wagner RF. Mohs micrographic surgery. *J Am Acad Dermatol.* 1998;39:79–97. [PMID: 9674401].
2. Behan FC. The keystone design perforator island flap in reconstructive surgery. *ANZ J Surg.* 2003;73:112–120. [PMID: 12608972].
3. Moncrieff MD, Bowen F, Thompson JF, et al. Keystone flap

flap to advance towards the defect. The patient had no post-surgery complications. Cosmetic results were outstanding after a one-year follow-up. (**Figure 1D**).

## Case Discussion

The keystone flap has been used classically to repair surgical defects of limbs. It consists of a fasciocutaneous island advancement flap that can be classified into different types according to location, size, and skin characteristics [2].

The modified keystone flap can have different variations. Type I consists of leaving a skin bridge intact along the greater arch of the flap. This will ensure adequate vascularization of the tissue and also preserve the subdermal lymphatics [3,4].

This modification of the original technique has the advantage of distributing the skin tension throughout the center of the bridge in a more even way, hence reducing the trauma to the underlying blood vessels. The results are less post-operative edema and reduced scarring complications [5].

## Conclusion

We present this case in which one of the variations of the keystone flap technique was used to repair a defect located in the nasal dorsum, achieving excellent functional and aesthetic results with no short- or long-term complications. This method should be considered as an option to close large MMS surgical defects of the nose area.

## Potential conflicts of interest

The authors declare no conflicts of interest.

- reconstruction of primary melanoma excision defects of the leg-the end of the skin graft? *Ann Surg Oncol.* 2008;15:2867–2873. [PMID: 18629589].
4. Moncrieff MD, Thompson JF, Stretch JR. Extended experience and modifications in the design and concepts of the keystone design island flap. *J Plast Reconstr Aesthet Surg.* 2010;63:1359–1363. [PMID: 19910272].

5. Moncrieff MD, Thompson JF, Quinn MJ, et al. Reconstruction after wide excision of primary cutaneous melanomas: part II – the extremities. *Lancet Oncol.* 2009;10:810–815. [PMID: 19647201].