

UC Davis
Dermatology Online Journal

Title

Cutaneous lymphangitis carcinomatosa: a unique presentation of a rare disease

Permalink

<https://escholarship.org/uc/item/925005wh>

Journal

Dermatology Online Journal, 29(2)

Authors

Peterson, H
Desai, M
Tawfik, M
[et al.](#)

Publication Date

2023

DOI

10.5070/D329260772

Copyright Information

Copyright 2023 by the author(s). This work is made available under the terms of a Creative Commons Attribution-NonCommercial-NoDerivatives License, available at <https://creativecommons.org/licenses/by-nc-nd/4.0/>

Peer reviewed

Cutaneous lymphangitis carcinomatosa: a unique presentation of a rare disease

H Peterson¹ BS, M Desai² MD, M Tawfik² MD, J Kerstetter² MD, A Elsensohn² MD, B Furukawa³ MD

Affiliations: ¹Loma Linda University School of Medicine, Loma Linda, California, USA, ²Department of Dermatology, Loma Linda University Medical Center, Loma Linda, California, USA, ³Department of Dermatology, Baylor Scott and White Medical Center, Temple, Texas, USA

Corresponding Author: Mansee Desai MD, 25865 Barton Road, Suite 101, Building D, Loma Linda, CA 92354, Tel: 909-558-2890, Fax: 909-558-2448, Email: mdesai@llu.edu

Abstract

A 75-year-old man with a three-year history of metastatic lung adenocarcinoma was diagnosed with cutaneous lymphangitic carcinomatosa of unique morphology. He was admitted to our hospital for right neck swelling, erythema, and failure to thrive. Skin examination demonstrated an indurated, thickened, firm, hyperpigmented plaque extending from the right neck and chest to the right ear, cheek, and eyelids. Skin biopsy demonstrated poorly differentiated adenocarcinoma, morphologically consistent with metastasis from the patient's known pulmonary adenocarcinoma and showed dermal invasion, perineural invasion, and involvement of dermal lymphatics. The diagnosis was an atypical presentation of cutaneous lymphangitis carcinomatosa from metastatic lung adenocarcinoma. This case presentation affirms that cutaneous lymphangitis carcinomatosa has a variety of atypical presentations, so physicians must maintain a high index of suspicion when evaluating cutaneous lesions in patients with known or suspected internal malignancy.

Keywords: cancer, dermatology, lungs, metastases, oncology

Introduction

Cutaneous lymphangitis carcinomatosa is defined as invasion of the dermis and subcutaneous lymphatic system by malignant cells [1-5]. It is a rare form of cutaneous metastasis with a variety of clinical presentations that can alert healthcare providers to cancer recurrence or even previously undiagnosed

malignancy [2-4]. This case presentation describes a novel atypical presentation of cutaneous lymphangitis carcinomatosa in a patient with previously diagnosed metastatic lung adenocarcinoma.

Case Synopsis

In March 2021, a 75-year-old man with a three-year history of metastatic lung adenocarcinoma was admitted to our hospital due to hypoxemic respiratory failure, right neck swelling, erythema, and failure to thrive. He had initially presented in January 2018 with left cervical adenopathy, a left neck mass causing dysphagia and anorexia, and a hoarse voice. He had a 50-year pack history of smoking tobacco cigarettes. His cancer was diagnosed in February 2018 after a left neck biopsy revealed lung adenocarcinoma metastasis. Starting in March 2018, the patient underwent more than 49 cycles of cancer treatments with pembrolizumab, pemetrexed, and carboplatin. In August 2020, the patient developed right neck lymphadenopathy and a lymph node biopsy in September 2020 was consistent with lung adenocarcinoma. The patient began to develop right neck swelling around November 2020. By February 2021, the patient had developed induration of the right eyelid, rendering him incapable of fully opening the right eye. The patient had no history of radiation or topical medications applied to these areas. The dermatology service was consulted at this time to evaluate the involved area, as the patient's primary team noted that the skin of the right lateral neck and face was extensively thickened. Physical

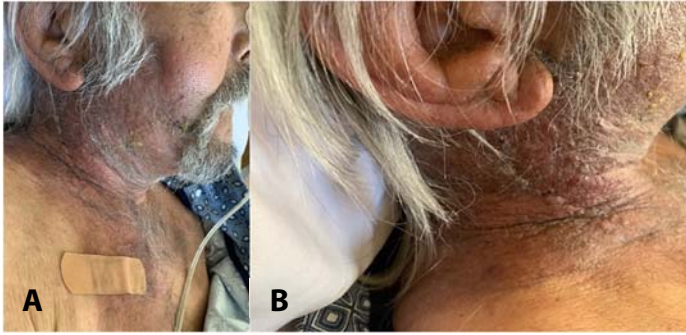

Figure 1. A) Lateral view of the indurated, hyperpigmented plaque on the patient's cheek and neck with extension to the right upper chest. **B)** Photograph of the indurated, hyperpigmented skin of the patient's right ear.

examination demonstrated an extensively indurated, thickened, hyperpigmented plaque spanning the right upper and lower eyelids, ear, cheek, neck, and upper chest; severely limited range of motion of the neck and right eyelid was noted (**Figure 1**). Serial CT scans of the soft tissue of the neck revealed extensive right cervical lymphadenopathy, consistent with known metastatic disease. Regional inflammatory fat stranding, skin thickening, and fascial thickening were also noted, along with asymmetric enlargement of the right sternocleidomastoid. A 4mm punch biopsy of the right chest plaque demonstrated metastatic, poorly-differentiated adenocarcinoma with micropapillary features invading the dermis, perineurium, and dermal lymphatics (**Figure 2**). The morphology of the tumor cells was consistent with the patient's known pulmonary adenocarcinoma. A diagnosis of cutaneous lymphangitis carcinomatosa was made. Given his metastatic disease and rapid decline of functional status, the patient was discharged from the hospital to hospice in April 2021 and passed away 11 days later.

Case Discussion

Cutaneous lymphangitis carcinomatosa, a rare form of cutaneous metastasis in less than 5% of cases, and occurs when malignant cells invade the dermis and the subcutaneous lymphatics [1-5]. In general, cutaneous metastases are a sign of advanced disease in patients, as they often signify late recurrence of

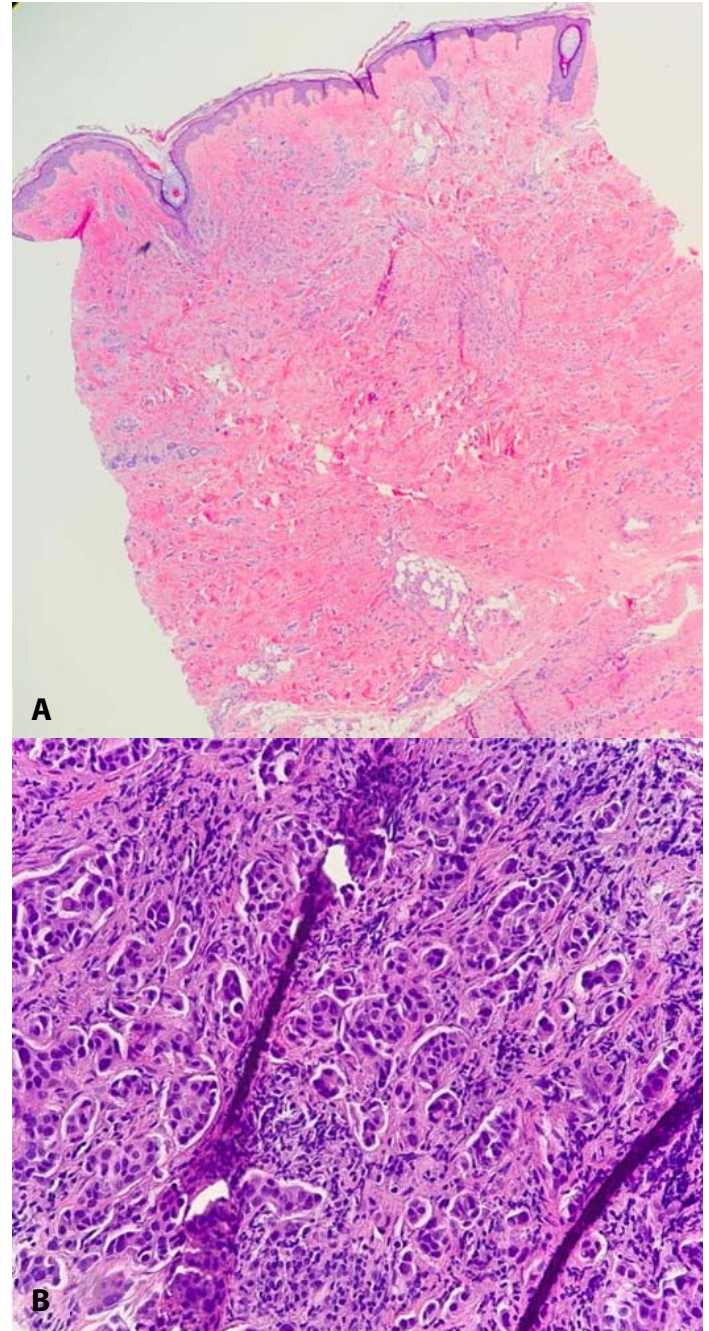


Figure 2. H&E histopathology. A) Right chest punch biopsy demonstrating metastatic poorly differentiated adenocarcinoma invading the dermis, morphologically consistent with the patient's known pulmonary adenocarcinoma, 4x. **B)** Right chest punch biopsy showing tumor dermal invasion, perineural invasion, and involvement of dermal lymphatics, 20x.

the primary cancer and are associated with metastases to other organs [2-4,6,7]. The likelihood of developing cutaneous metastases depends on the primary cancer; breast cancer is the most common cause of cutaneous metastases overall, whereas lung cancer is the second-most common cause overall

and the most common cause in men [1,4,7]. Debate exists over which histological type of lung cancer is most associated with cutaneous metastases, with some literature reviews concluding that lung adenocarcinoma is the top cause and some case series have reported squamous cell carcinoma or large cell carcinoma as top causes instead [4,7-9]. Regardless of the primary tumor type, the prognosis for patients with cutaneous lymphangitis carcinomatosa and cutaneous metastases in general is poor, with demise typically occurring within months after diagnosis of skin involvement [1,4,8,10].

No single clinical presentation reliably diagnoses any form of cutaneous metastasis, as they can present in a variety of ways and may mimic other inflammatory or infectious processes, often emerging a few years after successful treatment of the primary tumor [2,6,7,11]. The most common presentations are dome-shaped, firm, erythematous, sometimes painful nodules in the dermis or subcutaneous tissue [1,2,10]. Cutaneous lymphangitic carcinomatosa in the setting of lung cancer has been reported 10 times in the literature with four described morphologies: erysipeloid (3 cases), eczematous (2 cases), zosteriform appearance (4 cases), and cervicofacial edema (1 case), [1,5]. Additionally, lymphedema is usually present due to lymphatic involvement [5]. Notably, whenever cutaneous lymphangitic carcinomatosa is suspected, other conditions with similar underlying histology but different nuances in clinical morphology such as carcinoma erysipeloides, carcinoma telangiectoides, carcinoma hemorrhagiectoides, and carcinoma en cuirasse [12-18]. A comparison of the clinical morphology and histology of these conditions is listed in **Table 1**; as may be noted, a wide variety of terms exist to describe the underlying pathologic finding of malignant cell invasion [10].

Like all cutaneous metastases, a punch or excisional biopsy is required to diagnose cutaneous lymphangitis carcinomatosa; the histology will resemble that of the primary tumor and immunohistochemistry may be required for confirmation [2,11]. Cutaneous lymphangitis carcinomatosa demonstrates cords of malignant cells infiltrating the dermal and subcutaneous lymphatic system on histology [5,10]. A high index of

suspicion is required to correctly diagnose cutaneous lymphangitis carcinomatosa, especially when the presentation is atypical. A 2009 literature review found that up to 45% of cutaneous metastases that were eventually identified were not initially suspected to be malignant because of an unusual presentation [1,11]. Additionally, the lymphedema of cutaneous lymphangitis carcinomatosa can be difficult to distinguish from lymphedema secondary to cancer treatment. One key difference in presentation of these conditions is that lymphedema secondary to malignant infiltration of the lymphatics is of sudden onset and painful whereas lymphedema secondary to damaged lymphatics has an indolent onset and is painless [10]. It is crucial to diagnose skin involvement expediently and correctly as it can be the first sign of malignancy or recurrence of malignancy [2-4,6,7,11]. Even if the primary cancer has already been identified, correctly diagnosing cutaneous lymphangitis carcinomatosa can lead to adjustments of the patient's treatment plan that improve quality of life, as the lymphedema of cutaneous lymphangitis carcinomatosa is often symptomatic, hinders movement, and is psychologically distressing [6,10,11]. Unfortunately, cutaneous lymphangitis carcinomatosa itself is often progressive and not highly responsive to its only known treatment, systemic chemotherapy, with a survival time of often less than three months after appearance of the metastases [5,10]. Apart from local excision of any discrete symptomatic lesions, the main treatment is systemic chemotherapy or radiation to decrease the primary tumor burden or palliative care [2,6,9].

Conclusion

Cutaneous lymphangitis carcinomatosa is a rare form of cutaneous metastasis from internal malignancies with variable presentations that mimic inflammatory and infectious processes. This elusive diagnosis becomes even more difficult to correctly identify when the presentation is atypical, as with our patient. Yet, an accurate diagnosis of cutaneous lymphangitis carcinomatosa can alert providers to a previously unknown malignancy or cancer recurrence. Early diagnosis enables physicians to

Table 1. Clinical and pathological features of select forms of cutaneous metastases.

	Clinical features	Pathologic features
Cutaneous lymphangitis carcinomatosa	Lymphoedema [10] Diffusely erythematous, tender, indurated lesion without fever, chills, or leukocytosis, mimicking herpes zoster infection or eczema [1,5]	Tumor cells infiltrating dermal and subcutaneous lymphatics, as well as dermis and hypodermis [5,10]
Carcinoma erysipeloides	Fixed, erythematous patch or plaque, +/- distinct, raised edges, induration, erythema and lymphoedema, mimicking erysipelas or cellulitis but without fever [12,13] Polarized dermatoscopy shows erythematous telangiectasias with dyspigmentation on an orange background [13]	Tumor cells infiltrating the dermal and subcutaneous lymphatics, as well as dermis and hypodermis [12] Absence of neutrophilic involvement or other acute inflammatory changes [12] Malignant invasion of dermal vascular channels can occur [12]
Carcinoma telangiectoides	Almost exclusively seen in breast cancer [13] Erythematous patch with prominent telangiectasias [13,14] Red papules/papulovesicles [13,15]	Tumor cells infiltrating blood vessels with minimal invasion of dermis [14] Tumor cells in superficial lymphatics and blood vessels only [15]
Carcinoma hemorrhagiectoides	Indurated, violaceous, purpuric plaque, classically in a distribution of a medieval knight's shield (positive "shield sign"), [14]	Tumor cells infiltrating blood vessels and/or lymphatic vessels, with diffuse invasion of dermis as well [14]
Carcinoma en cuirasse	Almost exclusively seen in breast cancer [13,16] Scattered, flesh-colored nodules on an erythematous background that progress to a coalesced, diffuse sclerodermoid plaque [16,17] Peau d'orange appearance resembling morphea, radiation dermatitis, Paget's disease of the breast, or infection [13,16] Spread is slower and more discontinuous than that of carcinoma erysipeloides [18]	Dense infiltration of the dermis by tumor cells in single file lines or small clusters [13,17] Distinguished from postirradiation morphea by presence of tumor cells [17]

form an effective treatment plan that will best reduce tumor burden, improve the patient's quality of life, and help them to achieve goals of care.

Potential conflicts of interest

The authors declare no conflicts of interest.

References

- Prat L, Chouaid C, Kettaneh A, Fardet L. Cutaneous lymphangitis carcinomatosa in a patient with lung adenocarcinoma: case report and literature review. *Lung Cancer*. 2013;79:91-3. [PMID: 23164553].
- Wong CY, Helm MA, Kalb RE, Helm TN, Zeitouni NC. The presentation, pathology, and current management strategies of cutaneous metastasis. *N Am J Med Sci*. 2013;5:499-504. [PMID: 24251266].
- Lookingbill DP, Spangler N, Sexton FM. Skin involvement as the presenting sign of internal carcinoma. A retrospective study of 7316 cancer patients. *J Am Acad Dermatol*. 1990;22:19-26. [PMID: 2298962].
- Molina Garrido MJ, Guillén Ponce C, Soto Martínez JL, Martínez YSC, Carrato Mena A. Cutaneous metastases of lung cancer. *Clin Transl Oncol*. 2006;8:330-3. [PMID: 16760007].
- Kashihara E, Kanai O, Okamura M, Mio T. Cutaneous lymphangitis carcinomatosa made cervicofacial oedema intractable in a patient with superior vena cava syndrome. *BMJ Case Rep*. 2018;2018. [PMID: 29674402].
- Teyateeti P, Ungtrakul T. Retrospective review of cutaneous metastasis among 11,418 patients with solid malignancy: A tertiary cancer center experience. *Medicine (Baltimore)*. 2021;100:e26737. [PMID: 34398051].
- Wong CY, Helm MA, Helm TN, Zeitouni N. Patterns of skin metastases: a review of 25 years' experience at a single cancer center. *Int J Dermatol*. 2014;53:56-60. [PMID: 23432658].
- Marcovall J, Penín RM, Llatjós R, Martínez-Ballarín I. Cutaneous metastasis from lung cancer: retrospective analysis of 30 patients. *Australas J Dermatol*. 2012;53:288-90. [PMID: 23157780].
- Hidaka T, Ishii Y, Kitamura S. Clinical features of skin metastasis from lung cancer. *Intern Med*. 1996;35:459-62. [PMID: 8835596].
- Damstra RJ, Jagtman EA, Steijlen PM. Cancer-related secondary lymphoedema due to cutaneous lymphangitis carcinomatosa: clinical presentations and review of literature. *Eur J Cancer Care (Engl)*. 2010;19:669-75. [PMID: 20030691].
- Nashan D, Muller ML, Braun-Falco M, et al. Cutaneous metastases of visceral tumours: a review. *J Cancer Res Clin Oncol*. 2009;135:1-14. [PMID: 18560891].
- Al Ameer A, Imran M, Kaliyadan F, Chopra R. Carcinoma erysipeloides as a presenting feature of breast carcinoma: A case

- report and brief review of literature. *Indian Dermatol Online J.* 2015;6:396-8. [PMID: 26753138].
13. Alexis F, Leggett LR, Agarwal N, Bakhtin Z, Farabi B. Carcinoma Erysipeloides With Clinical and Dermatoscopic Features: An Overlooked Clinical Manifestation of Breast Cancer. *Cureus.* 2022;14:e23445. [PMID: 35494933].
 14. Cohen PR, Kurzrock R. Cutaneous Metastatic Cancer: Carcinoma Hemorrhagictoides Presenting as the Shield Sign. *Cureus.* 2021;13:e12627. [PMID: 33585116].
 15. Patra S, Khandpur S, Khanna N, Jain D. Angioma like carcinoma telangiectoides: An unusual presentation of breast carcinoma metastasis. *Indian J Dermatol Venereol Leprol.* 2018;84:83-5. [PMID: 29271367].
 16. Alani A, Roberts G, Kerr O. Carcinoma en cuirasse. *BMJ Case Rep.* 2017;2017. [PMID: 29197843].
 17. Wang H, Bao C, Gong T, Ji C. Case Report: Carcinoma en Cuirasse in a Middle-Aged Woman Mimicking Postirradiation Morphea. *Front Oncol.* 2021;11:747123. [PMID: 34745972].
 18. Resetkova E. Pathologic aspects of inflammatory breast carcinoma: part 1. Histomorphology and differential diagnosis. *Semin Oncol.* 2008;35:25-32. [PMID: 18308143].