

UC Davis

Dermatology Online Journal

Title

Sporotrichoid chromomycosis

Permalink

<https://escholarship.org/uc/item/913521rt>

Journal

Dermatology Online Journal, 19(11)

Authors

Kawtar, Inani
Salim, Gallouj
Mariame, Meziane
et al.

Publication Date

2013

DOI

10.5070/D31911020394

Copyright Information

Copyright 2013 by the author(s). This work is made available under the terms of a Creative Commons Attribution-NonCommercial-NoDerivatives License, available at <https://creativecommons.org/licenses/by-nc-nd/4.0/>

Peer reviewed

Case Report

Sporotrichoid chromomycosis

Inani Kawtar¹, Gallouj Salim¹, Meziane Mariame¹, Mernissi Fatimazahra¹, Tlamçani Imane², Benjelloun Salma², El Hassani Imane², Errami Mohamed²

Dermatology Online Journal 19 (11): 3

¹Dermatology Department, Chu Hassan II Fez, Morocco

²Laboratory of Parasitology, Moulay Ismail Military Hospital. Meknes, Morocco

Correspondence:

Inani Kawtar
Dermatology Department,
Chu Hassan II Fez Morocco
docteurkawtar@gmail.com,
telephone: +212661503450

Tlamçani Imane
Laboratory of Parasitology,
Moulay Ismail Military Hospital
Meknes, Morocco
tlemcanimane@hotmail.com

Abstract

Chromomycosis is a chronic fungal skin infection. It manifests frequently by warty or vegetative lesions in exposed areas, most often secondary to trauma. The diagnosis, nevertheless, is confirmed by the presence of fungi in the mycological examination. In fact, the treatment remains a challenge given its recalcitrant nature.

Keywords: chromomycosis, sporotrichoid, terbinafine, cryotherapy

Introduction

Chromomycosis is a deep mycosis that is exceptional in Morocco. In this context, we will report a case of sporotrichoid chromomycosis of the upper limb, which improved with terbinafine and cryotherapy.

Case synopsis

A 70-year old-farmer, without significant pathological history, presented with 12 years of nodules of the right upper limb. The nodules had been increasing in size and number gradually. Prior to presentation to our institution, initial skin biopsy detected leishmaniasis; the patient was treated with intralesional glucantime but without improvement. A second biopsy was suggestive of tuberculosis, for which the patient received anti-bacillary treatment for 2 years, but without improvement.

The clinical examination revealed vegetative nodules and plaques on the fingers, dorsal hand, and forearm of the right upper limb in a sporotrichoid arrangement, associated with significant lymphedema (Figure 1, 2, 3). The rest of the examination, however, did not detect any additional skin lesions. Radiology examination of the affected limb was normal; HIV status was negative.

A skin biopsy with three fragments was performed and histological study revealed a non-specific chronic granulomatous dermatitis. Bacteriological study identified *Staphylococcus epidermidis*. Mycological study showed fungal cells (Figure 4). Culture was carried out in Sabouraud media with chloramphenicol and was incubated at +28 ° C. After ten days, downy and blackish colonies appeared (Figure 5). Further examination of colonies showed the presence of septate and pigmented hyphae,

which were derived from short branches with elongated spores at the ends. Short chains of spores or sometimes apical serrations were present (Figure 6). These aspects were suggestive of *Fonsecaea pedrosoi* species.

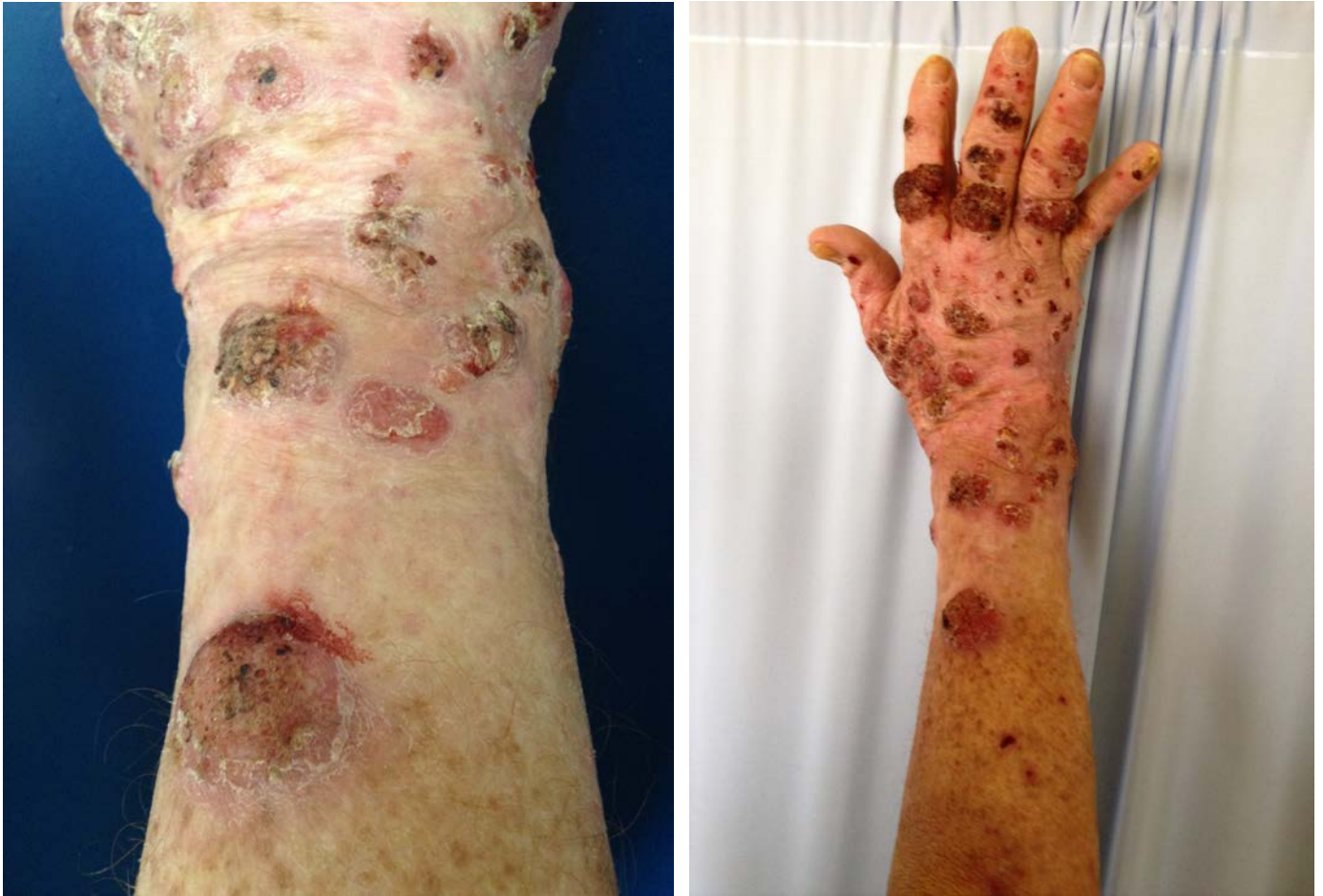

Figure 1. Vegetative nodules and plaques on right dorsal hand and forearm

Figure 2. Nodules and vegetations of the right upper limb in a sporotrichoid arrangement

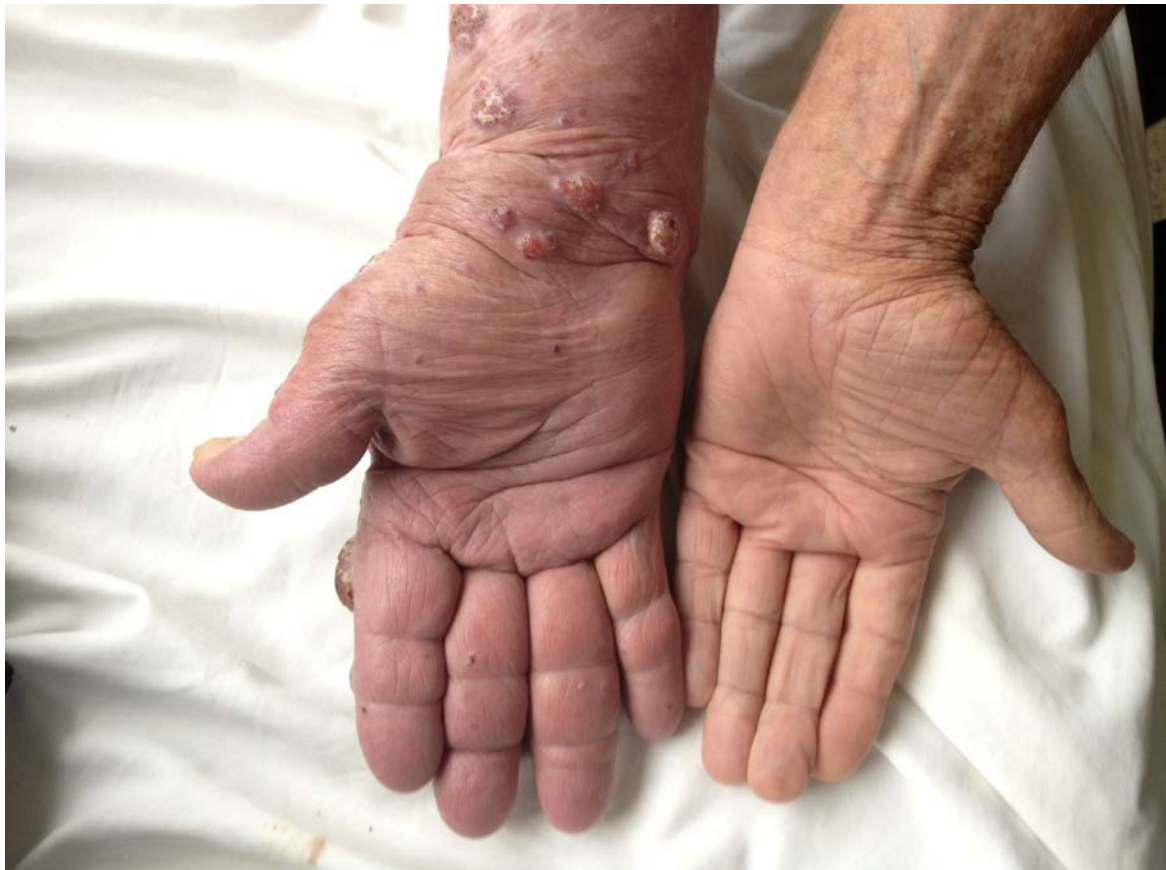

Figure 3. Nodules and lymphedema of the right upper limb

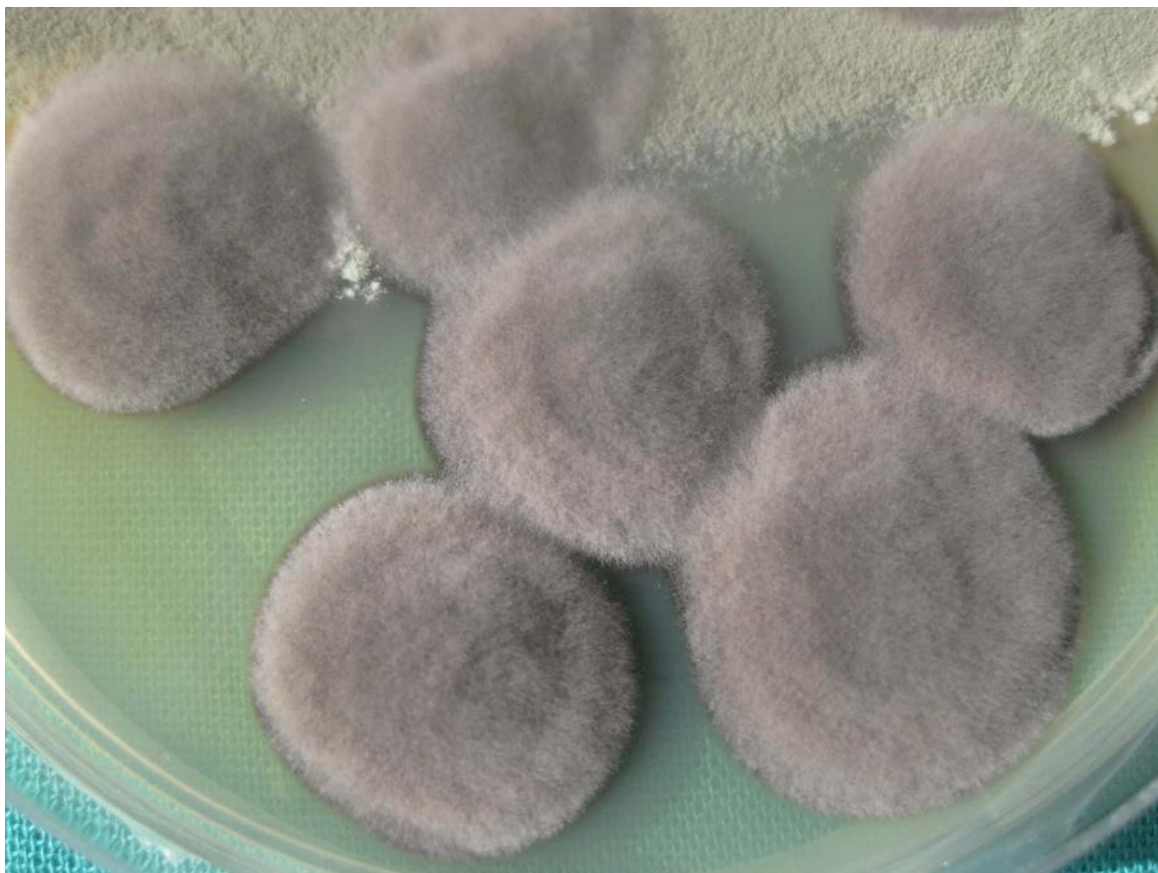

Figure 4. Examination of colonies in potash at 20% showed fungal cells

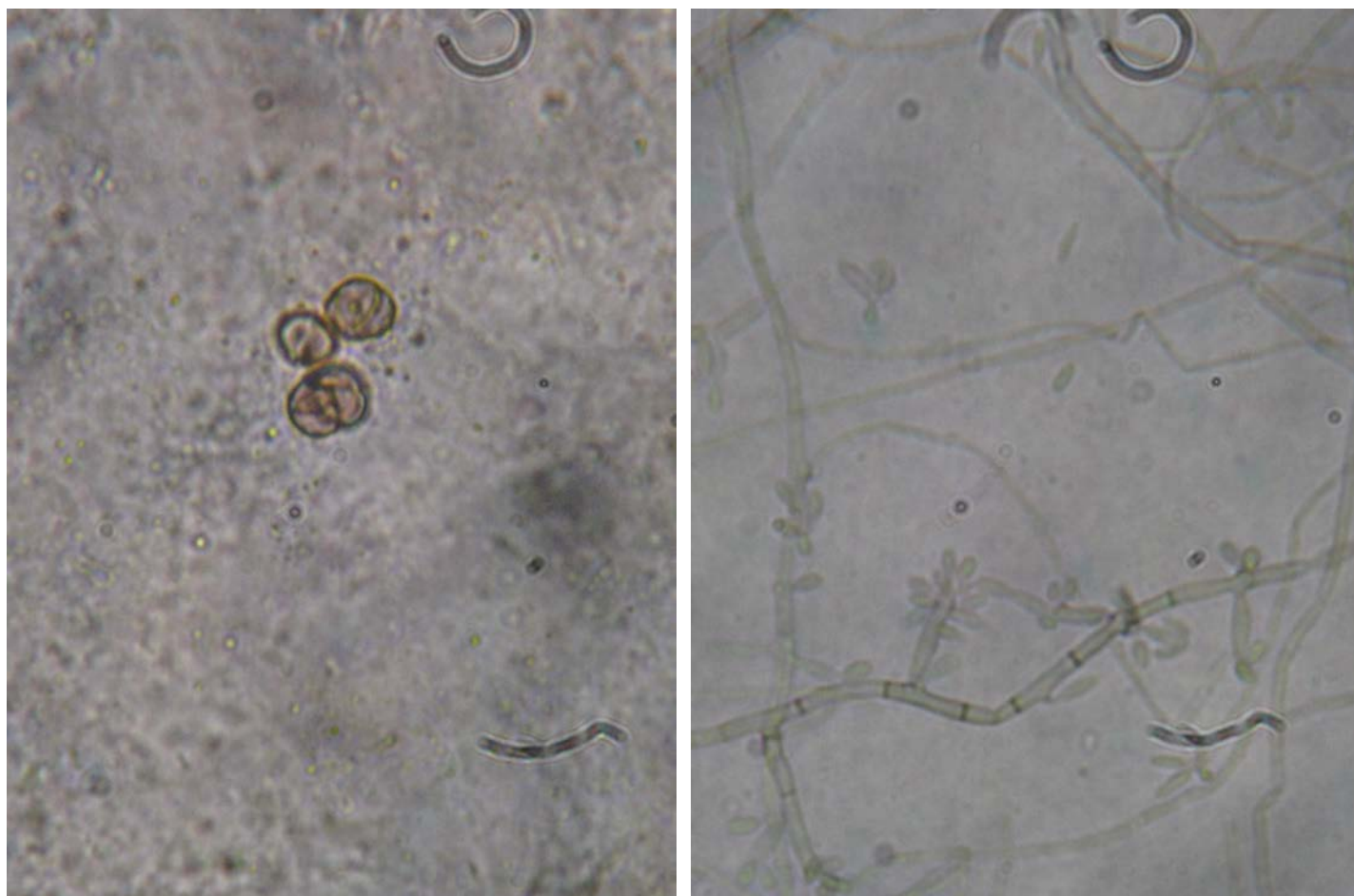


Figure 5. The culture in Sabouraud chloramphenicol at +28 ° C, showed after ten days, downy and blackish colonies

Figure 6. Examination of these colonies showed the presence of septate and pigmented hyphae, which were derived from short branches with spores at ends. Short chains of spores or sometimes apical serrations were present.

The diagnosis of chromomycosis related to *Fonsecaea pedrosoi* was made. The patient was placed on terbinafine 500 mg/ per-day associated with repeated cryotherapy. A significant regression of lesions after three months of treatment was achieved (Figure 7,8).

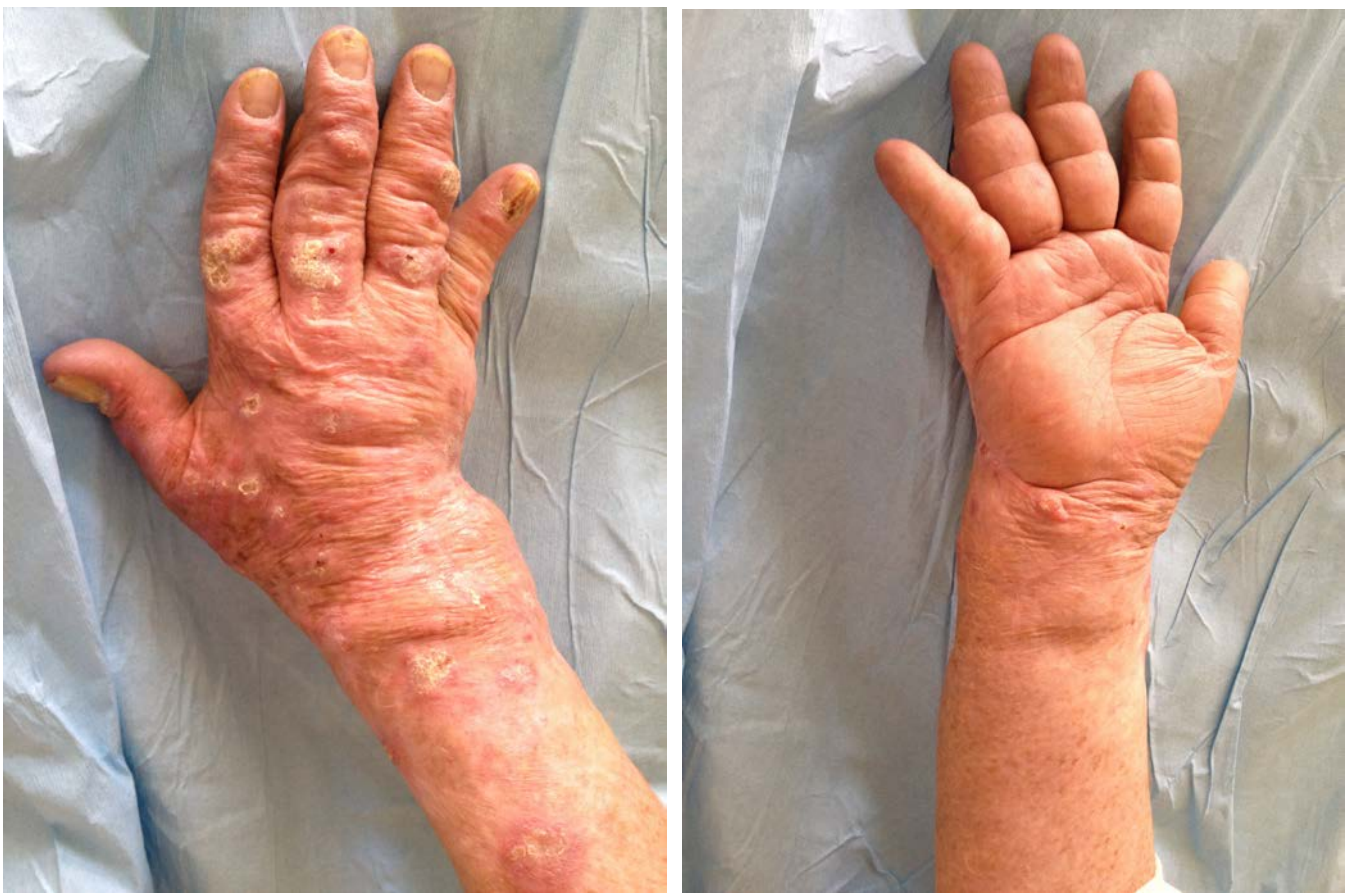

Figure 7. regression of vegetated lesions on back of hand and forearm of the right upper limb

Figure 8. regression of vegetated lesions in the posterior side of the forearm with persistent of lymphedema

Discussion

Chromomycosis is a mycosis caused by pigmented fungi of the family of dematiaceous fungi as was described first by Rudolph in 1914. There are 5 species: *Fonsecaea pedrosoi*, *Carrionii Cladosporium*, *Phialophora verrucosa*, *Fonsecaea Compacta*, and *Rhinochrysiella aquaspersa*. [1, 2]

Chromomycosis is a cosmopolitan disease, but mainly prevalent in tropical and subtropical regions. Chromomycosis is exceptional in North Africa; only ten cases have been reported in Morocco between 1989 and 2010, nine of which were related to *F. pedrosoi*. Seven cases have been described in Algeria and two in Tunisia. [1, 2, 3]

The infection affects mostly men in rural areas as a result of skin injury by plant thorns or contaminated wood chips. This explains the frequency of involvement of the lower limb, but other locations, such as upper limbs, buttocks, trunk and face, have been reported. [1, 2, 4]

Clinically, nodules,, patches, warty plaques,, tumors, and scars have been described [1, 3, 5]. Our patient did not recall trauma but was engaged in an occupation associated with frequent trauma. He presented with warty nodules on the upper limb in a sporotrichoid arrangement associated with significant lymphedema.

Mycological examination of skin biopsy allows the correct diagnosis to be made. Histology can also show fungus. However, the histological examination may only identify pseudoepitheliomatous epidermal hyperplasia, intraepidermal neutrophilic microabscesses, and granulomas. In our case, histology was suggestive, but the mycological examination identified *Fonsecaea pedrosoi*. [1, 3, 5, 6]

Treatment remains a challenge, given the recalcitrant nature of the disease. Local treatment (surgical excision, laser therapy, and cryotherapy) is proposed for localized forms. Systemic antifungal medications (itraconazole, terbinafine, 5-fluorocytosine) are proposed for more extensive forms. These treatments, however, may be offered alone or in combination.

Before beginning itraconazole and terbinafine, local treatment was recommended. Actually, terbinafine and itraconazole are the most effective.. In some cases, forms highly resistant to itraconazole have been reported. Terbinafine is a useful first-line treatment in chromomycosis; the dosage of terbinafine ranges from 250 mg to 1 g per-day, for 6 months to one year, until achievement of a negative mycological examination. [1, 2, 3, 6, 7, 8]

Our patient was placed on combined therapy with terbinafine 500 mg per day and cryotherapy with significant regression of lesions after three months (Figure 7,8), thus confirming the efficacy of terbinafine and combination therapy.

Conclusion

Chromomycosis is a chronic, slowly evolving infection, which may be confused with leishmaniasis and tuberculosis. Herein we report chromomycosis of the upper limb with a sporotrichoid arrangement and the presence of significant lymphedema.

References

1. Queiroz-Telles F, Esterre P, Perez-Blanco M, Vitale RG, Salgado CG, Bonifaz A. Chromoblastomycosis: an overview of clinical manifestations, diagnosis and treatment. *Med Mycol*. 2009 Feb; 47(1):3-15 [PMID: 19085206]
2. Levang J, Muller P, Marreel A, Nicolas M, Puzenat E, Aubin F, Humbert P. Chromomycosis in Guadeloupe. *Ann Dermatol Venereol*. 2008 Feb; 135(2):111-5. [PMID: 18342091]
3. Radouane N, Hali F, Khadir K, Soussi M, Ouakadi A, Marouane S, Zamiaty S, Benchikhi H. Generalized chromomycosis caused by *Phialophora verrucosa*. *Ann Dermatol Venereol*. 2013 Mar; 140(3):197-201. [PMID: 23466152]
4. Patel U, Chu J, Patel R, Meehan S. Subcutaneous dematiaceous fungal infection. *Dermatol Online J*. 2011 Oct 15; 17(10):19. [PMID: 22031645]
5. Chandran V, Sadanandan SM, Sobhanakumari K. Chromoblastomycosis in Kerala, India. *Indian J Dermatol Venereol Leprol*. 2012 Nov-Dec; 78(6):728-33. [PMID: 23075642]
6. Vollum DI. Chromomycosis: a review. *Br J Dermatol*. 1977 Apr; 96(4):454-8. [PMID: 861185]
7. Calvo E, Pastor FJ, Mayayo E, Hernández P, Guarro J. Antifungal therapy in an athymic murine model of chromoblastomycosis by *Fonsecaea pedrosoi*. *Antimicrob Agents Chemother*. 2011 Aug; 55(8):3709-13. [PMID: 21576429]
8. Xibao Z, Changxing L, Quan L, Yuqing H. Treatment of chromoblastomycosis with terbinafine: a report of four cases. *J Dermatolog Treat*. 2005 Apr; 16(2):121-4. [PMID: 16019628]