

UC Davis

Dermatology Online Journal

Title

Atypical rosacea in a male patient: case study

Permalink

<https://escholarship.org/uc/item/8x65r1kx>

Journal

Dermatology Online Journal, 22(2)

Authors

Debroy Kidambi, A
Tiffin, NJ
Ramsay, HM

Publication Date

2016

DOI

10.5070/D3222030101

Copyright Information

Copyright 2016 by the author(s). This work is made available under the terms of a Creative Commons Attribution-NonCommercial-NoDerivatives License, available at <https://creativecommons.org/licenses/by-nc-nd/4.0/>

Letter

Atypical rosacea in a male patient: case study

A Debroy Kidambi¹, NJ Tiffin², HM Ramsay¹

Dermatology Online Journal 22 (2): 16

¹Department of Dermatology, Royal Hallamshire Hospital, Sheffield, UK

²Department of Dermatology, Royal Hallamshire Hospital, Sheffield, UK

Correspondence:

Dr Arpita Debroy Kidambi
Department of Dermatology,
Royal Hallamshire Hospital,
Sheffield, United Kingdom
Phone: 0114 271 1900
Email: arpita.debroy-kidambi@sth.nhs.uk

Abstract

Rosacea fulminans is a rare disorder of unknown cause, almost exclusively affecting women. There are only a few reported cases in men. The condition is characterized by the abrupt onset of pustules and nodules predominantly affecting the cheeks or chin without any systemic upset. We report the case of a 37-year-old man who presented with papulopustules, predominantly localized to his nose. Histopathological features were consistent with rosacea fulminans. The patient was managed with treatments including oral prednisolone, isotretinoin, and trimethioprime.

Keywords: Rosacea Fulminans, Men

Case synopsis

A 37-year-old previously fit and well man presented with a three-week history of a painful erythematous facial rash unresponsive to aciclovir, flucloxacillin, and penicillin V prescribed by his primary care physician. He was systemically well. There was no history of flushing or seborrhoea. He gave a history of an acne-like eruption on the beard area 4 years prior that had responded to minocycline. Examination revealed numerous tender pustules, erythematous papules, and crusting on the nose, with a few lesions scattered on the cheeks and glabellar region (Figure 1). No comedones, telangiectasia, or ocular involvement were described.

Laboratory findings included white blood cell count $12 \times 10^9/L$, neutrophils $11 \times 10^9/L$, erythrocyte sedimentation rate 25 mm/hr, C-reactive protein 46 mg/L. Blood glucose, liver enzymes, and renal function tests were normal. HIV serology was negative. Chest x-ray was unremarkable. Pending further results, intravenous penicillin and flucloxacillin were started, without significant clinical improvement.

Bacterial and viral swabs were negative. Skin biopsies were taken. Tissue culture for bacteria, atypical mycobacteria, and fungi were unremarkable.

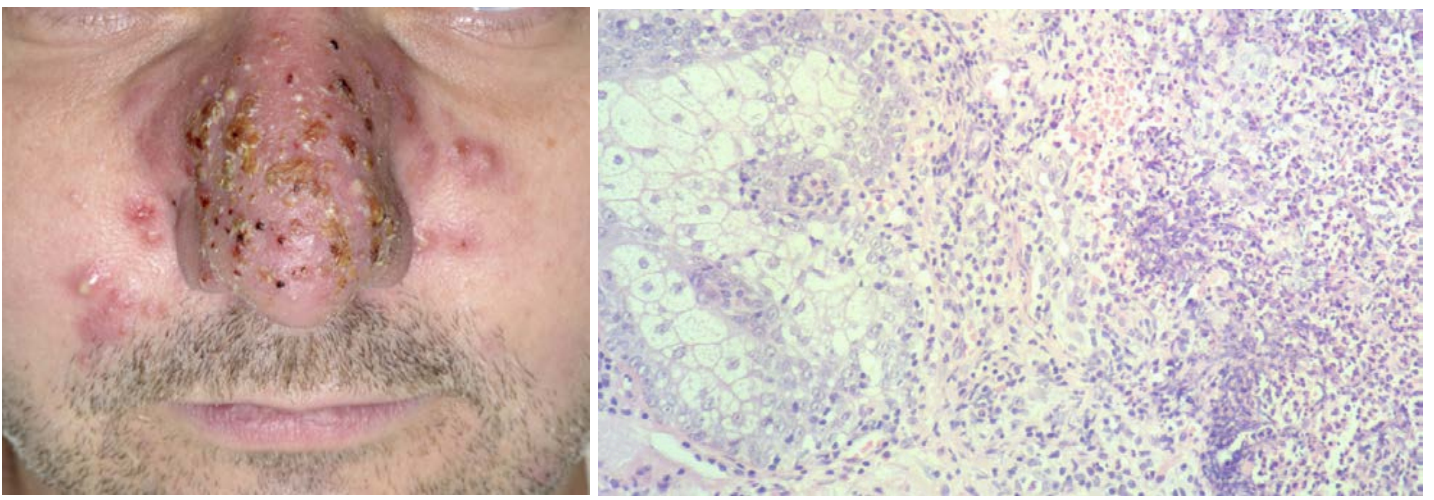


Figure 1. Clinical and histopathology findings

Histopathological findings

The skin biopsy showed an acute, suppurative folliculitis. The follicles appeared mildly plugged with Demodex mites. A Gram stain demonstrated only small numbers of gram-positive cocci in intact follicles, of doubtful significance. No fungal spores, hyphae, or mycobacteria were identified. There was no evidence of vasculitis, and although histiocytes were present in the dermal infiltrate, well-formed granulomas were not conspicuous.

Diagnosis

Rosacea Fulminans

Clinical progress

The patient was commenced on oral prednisolone 35 mg once daily (0.5 mg/kg/day) producing a marked improvement in the erythema, edema, and pustules noted clinically. Isotretinoin 20 mg once daily was commenced after one week and the prednisolone dosage was reduced. Owing to ongoing development of inflammatory lesions, the patient's isotretinoin was increased to 60 mg once daily (~1 mg/kg/day) and subsequently trimethoprim 300 mg twice daily was introduced. Six months after his diagnosis, the patient's skin was completely clear and isotretinoin was stopped, but maintenance treatment with trimethoprim was continued. One year following his diagnosis, the patient's skin remained clear and all treatments were stopped.

Discussion

Rosacea fulminans (RF) is a rare condition of unknown aetiology, first described in 1940 by O'Leary and Kierland [1]. RF has been reported almost exclusively in post-adolescent women; there are rare reports in men in the literature with only one previous case where the eruption was confined to the nose [2].

RF is characterized by the abrupt onset of a severe facial eruption of cysts, nodules, and abscesses in otherwise healthy skin. Constitutional symptoms are generally absent. Easy flushing and telangiectasia have been described. Ocular involvement is rare. Some patients give a past history of acne and seborrhoea.

RF has only rarely been biopsied. However, in the absence of any demonstrable infective organisms, the presence of a dermal infiltrate including neutrophils, lymphocytes and histiocytes, with preferential involvement of the follicles and sebaceous glands can be of great assistance in determining the diagnosis. As RF is uncommon, and the histological features are only rarely encountered in dermatopathology, it is recommended that a pathologist with a special interest in skin disease report these specimens.

Treatment options include systemic and/or potent topical corticosteroids, isotretinoin, antibiotics, and dapsone [3,4]. Generally systemic prednisolone is used to control the acute phase with the gradual introduction of oral isotretinoin some 2-3 weeks after the acute inflammation has subsided. As the prednisolone dosage is reduced and withdrawn, the isotretinoin dosage is gradually increased. A total cumulative dose of isotretinoin of approximately 150 mg/kg has been suggested as optimal [4].

The majority of cases subside within a course of one year. Scarring may ensue but is not invariable. Relapse is rare.

References

1. O'Leary PA, Kierland RR. Pyoderma faciale. Arch Dermatol Syphilol 1940; 41 (3): 451-462. [No PMID]
2. Patterson CR, Wilkinson JD, Lewis FM. Rosacea fulminans confined to the nose. Journal of European Academy of Dermatology and Venerology 2009; 23 (9): 1101-1102. [PMID: 19368613]
3. Bettoli V, Mantovani L, Boccia S et al. Rosacea Fulminans Related to Pegylated Interferon Alpha-2b and Ribavirin Therapy. Acta Dermato-Venerologica 2006; 86 (3): 258-259. [PMID: 16710591]
4. Strauss JS. Rosacea fulminans. Journal of European Academy of Dermatology and Venereology 2001; 15(5): 385. [PMID: 11763373]