

UC Davis

Dermatology Online Journal

Title

Erosive pustular dermatosis of the scalp induced by gefitinib: case and review of the literature

Permalink

<https://escholarship.org/uc/item/8w87m82r>

Journal

Dermatology Online Journal, 27(2)

Authors

Nazzaro, Gianluca
Giacalone, Serena
Bortoluzzi, Paolo
et al.

Publication Date

2021

DOI

10.5070/D3272052385

Copyright Information

Copyright 2021 by the author(s). This work is made available under the terms of a Creative Commons Attribution-NonCommercial-NoDerivatives License, available at <https://creativecommons.org/licenses/by-nc-nd/4.0/>

Peer reviewed

Erosive pustular dermatosis of the scalp induced by gefitinib: case and review of the literature

Gianluca Nazzaro¹ MD, Serena Giacalone² MD, Paolo Bortoluzzi² MD, Stefano Veraldi² MD, Angelo Valerio Marzano^{1,2} MD

Affiliations: ¹Dermatology Unit, Fondazione IRCCS, Ca' Granda Ospedale Maggiore Policlinico, Milan, Italy, ²Department of Pathophysiology and Transplantation, Università degli Studi, Foundation IRCCS, Cà Granda Ospedale Maggiore Policlinico, Milan, Italy

Corresponding Author: Paolo Bortoluzzi MD, Department of Pathophysiology and Transplantation, Università degli Studi, Foundation IRCCS, Cà Granda Ospedale Maggiore Policlinico, Milan, Italy, Tel: 39-3494182187, Email: paolobortoluzzi.1@gmail.com

Abstract

Gefitinib is a selective tyrosine kinase inhibitor of epidermal growth factor receptor (EGFR) used for the treatment of malignant neoplasms. The most frequent skin complication during gefitinib therapy is an acneiform papulopustular eruption, usually distributed in the seborrheic areas but occasionally widespread. We report a patient with erosive pustular dermatosis of the scalp, a neutrophil-mediated skin disease presenting with sterile pustules evolving into erosions and crusts on the scalp, during treatment with the EGFR inhibitor gefitinib for lung cancer. A literature review of the drug-induced cases of this rare entity is provided.

Keywords: erosive pustular dermatosis of the scalp, gefitinib, epidermal growth factor receptor

Introduction

Gefitinib is a selective tyrosine kinase inhibitor of the epidermal growth factor receptor (EGFR) used for the treatment of some malignant neoplasms [1]. The EGFR family regulates the tyrosine kinase signaling pathway, which is responsible for cell cycle progression, division, and differentiation. EGFR has been found to be overexpressed in some solid tumors, such as colon, lung, breast, and pancreas [2]. Gefitinib and erlotinib were the first EGFR tyrosine kinase inhibitors to be approved by the US Food and

Drug Administration for the treatment of non-small cell lung carcinoma [3].

The most frequent skin complication during gefitinib therapy is an acneiform papulopustular eruption, most commonly involving the seborrheic regions. Uncommonly these eruptions may be more extensive. The median time to onset is generally 7-10 days after the start of the treatment; other cutaneous adverse reactions include xerosis, vitiligo, paronychia, mucositis, and hair changes, such as scalp alopecia, curling of the hair, and facial hypertrichosis [4,5]. The acronym PRIDE syndrome (Papulopustules and/or paronychia, Regulatory abnormalities of hair growth, Itching, Dryness caused by EGFR) has been proposed to refer to the most common skin side effects [6]. We report a patient with erosive pustular dermatosis of the scalp (EPDS) during treatment with gefitinib for non-small cell lung cancer and perform a review of the literature of the drug-induced cases.

Case Synopsis

An 84-year-old man with non-small cell lung cancer and multiple brain and liver metastases started treatment with gefitinib (250mg once daily). After four weeks of treatment, the patient developed a pustular rash on his scalp, which was already affected by multiple actinic keratoses (AKs). The oncologists suggested to continue the treatment that was otherwise well tolerated by the patient. At the three-

month follow-up appointment the brain and liver masses were stable but the patient's scalp was completely covered by yellowish pustules and crusts that had dried, forming a thick crust layer (**Figure 1**). Gentle curetting of the scalp revealed the presence of numerous coalescent pustules, draining purulent material (**Figure 1** inset).

A swab and culture from a pustule grew no pathogenic bacteria. The histological examination showed an eroded epidermis and a dense dermal infiltrate consisting of lymphocytes, neutrophils, and plasma cells above a thick stratum of solar elastosis (**Figure 2**).

The diagnosis was thus EPDS induced by gefitinib. Treatment with gefitinib was continued and the patient was subsequently treated with chlorhexidine soaks for ten days and with a 0.05% clobetasol propionate cream applied twice daily for two weeks, then once a day for four weeks. After two months complete resolution was achieved.

Case Discussion

Erosive pustular dermatosis of the scalp is an uncommon condition mainly affecting elderly Caucasian men with prolonged sun exposure on the scalp. The course is slow and progressive over months or years. The patient generally presents with sterile pustules involving large areas of the scalp and

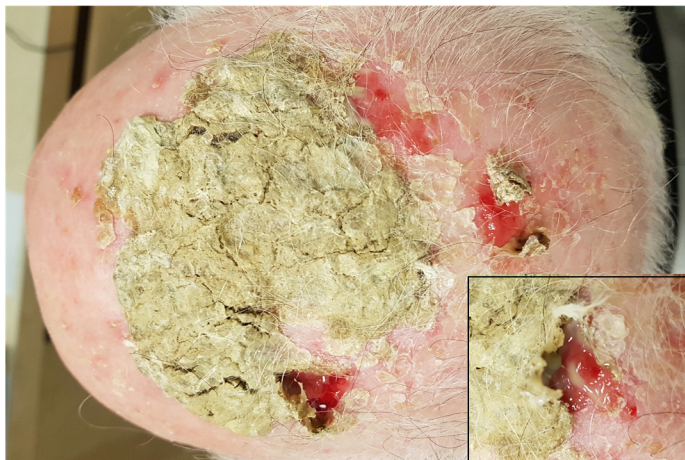

Figure 1. Thick hyperkeratotic yellowish plaque on the scalp of our patient, after three months of treatment with gefitinib 250mg once daily for metastatic non-small cell lung cancer. Inset, the gentle curetting of the scalp revealed numerous coalescent pustules, draining purulent material.

resolving sometimes with scarring alopecia, particularly in long-standing cases. Among the predisposing factors, local trauma [7], autoimmune diseases [8], skin grafting, sun exposure [9], and physical or chemical treatment for AKs have been reported. Such treatments reported include cryotherapy [10], photodynamic therapy [11], imiquimod [12], and ingenol mebutate [13]. Furthermore, EPDS has also been described following therapies for androgenetic alopecia [14-15] and after hair transplantation [16]. Finally, surgical trauma during cochlear implantation and/or the skin inflammation near the magnet required for the procedure were considered triggering factors for the development of EPDS [17].

Patton [18] considered atrophy to be the major predisposing factor of EPDS and erosive pustular dermatosis of the legs, the latter regarded as the same entity involving lower extremities. Actinic damage is the predisposing factor in the scalp and stasis dermatitis and edema of venous insufficiency are the predisposing factors for involvement of the legs. According to Laffitte [19], EPDS represents delayed wound healing because of skin atrophy and chronic inflammation. Some authors suggested that it may be included in the neutrophilic dermatoses (ND) spectrum [20, 21], in which pathergy plays a pathogenetic role. Including this entity in the classification of ND among the epidermal/superficial forms, one of our authors, AVM, suggested to rename it as "amicrobial pustulosis of the scalp" [22],

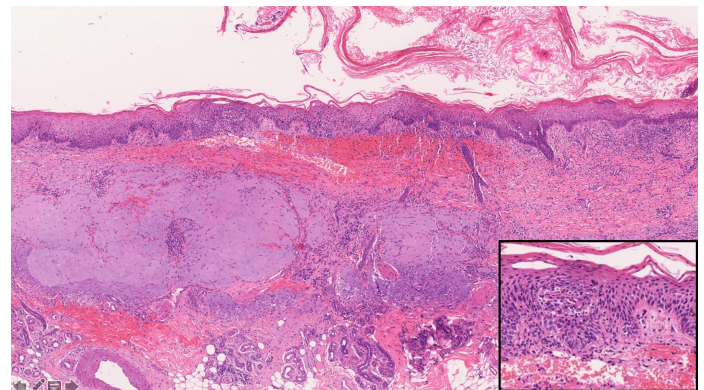


Figure 2. Histological examination showed hyperkeratosis and focal erosions of the epidermis. A dense dermal infiltrate consisting of lymphocytes, neutrophils and plasma cells above a thick stratum of solar elastosis was also visible, H&E, 40x. Inset, close-up of an epidermal pustule, H&E, 200x.

Table 1. Erosive pustular dermatosis of the scalp induced by gefitinib.

Case Reference	Age and Sex	Underlying Disease	Time of resolution	Site	Local Trauma	Treatment	Cutaneous swab	Outcome
Wu et al. [24]	69/F	LC	9 months	Frontal/Parietal	Radiation	Discontinuation + topical steroid	Not mentioned	Improve with scar
Toda et al. [25]	69/F	NSCLC	3 years	Parietal	Radiation	Discontinuation + oral steroids and antibiotics	Not mentioned	Improve with scar
Fukui et al. [26]	57/F	NSCLC	11 months	Frontal/Parietal/Temporal	Not mentioned	Discontinuation + oral antibiotics and topical steroid	Positive	Improve with scar
Present case	84/M	NSCLC	11 months	Frontal/Parietal/Temporal	AK	Discontinuation + topical steroids and salicylic acid	Negative	Improve with scar

LC= lung cancer, NSCLC= non-small-cell lung cancer, AK= actinic keratosis

stressing the sterile nature of the pustules. Neutrophilic dermatoses encompass a large group of conditions related to the accumulation of mature neutrophils in the skin and rarely in internal organs; they are regarded as autoinflammatory in their origin [21-23]. They are clinically characterized by polymorphic, neutrophilic pustules, plaques, and nodules.

Erosive pustular dermatosis of the scalp occurring during gefitinib treatment has been reported only three times (**Table 1**), [24-26]. Three of four patients were female with a median age of 70 years. Underlying diseases were non-small cell lung cancer in three cases and non-specified lung cancer in the other. The parietal scalp was the most frequently involved area (4/4), followed by the forehead (3/4) and the temporal area (2/4). The mean duration of disease at the time of diagnosis was 17 months, ranging from 9 months to three years. In all patients, discontinuation of gefitinib led to the regression of erythema and pustules with scarring alopecia. All these cases were treated with high-potency topical corticosteroids and tacrolimus 0.1% ointment during the active phase. These topical medications are effective and safe and considered first line therapy in EPDS [27]. In particular, clobetasol is the most used topical corticosteroid with a 93% rate of improvement or resolution [28]. In one case, topical medication was implemented with the use of salicylic acid to thin the hyperkeratotic plaques,

whereas another required oral corticosteroids. Oral corticosteroids and dapsone have been proposed as second line treatment; they are sometimes needed to accelerate the healing process and reduce the risk of recurrence [27].

A cutaneous swab for culture was performed two times. Fukui [26] described secondary infection in his patient and recommended treatment with oral antibiotics. Although microbes such as *Staphylococcus aureus* are often isolated, they are an expression of secondary superinfection and do not play a pathogenetic role: therefore, EPDS is usually unresponsive to antibiotics alone [28].

It is of interest that three of these four cases underwent previously local trauma. In particular, the patients reported by Wu and Toda [24,25] received radiotherapy in combination with chemotherapy. In our case, a number of physical treatments for AKs had been given.

EGFR is expressed in the outer root sheath of the hair follicle: stimulation of the receptor is associated with the progression from the G1 phase to the S phase of the cell cycle. Therefore, the interruption of the signal mediated by EGFR leads to the blockade of hair transition from the anagen to the telogen phase. In addition, the inhibition of EGFR also strengthens UV-induced keratinocyte apoptosis [29]. This has been demonstrated by the increased level of keratinization markers and disintegration of

intercellular connections, an expression of a damaged barrier. Finally, the result is the loss of the hair follicle immune privilege with increase in the expression of genes that stimulate inflammatory processes, apoptosis, and occlusion of the ducts, leading to their rupture [26].

Conclusion

Herein, we report a rare patient with EPDS during gefitinib therapy and we describe similar cases in the literature. Pathogenetic mechanisms associated with EPDS onset most likely involve both inflammation

and atrophy. Although the exact mechanism of scalp inflammation associated with EGFR inhibitors is not fully understood, skin atrophy is an important predisposing factor and could be the consequence of local trauma, such as radiotherapy or actinic damage. Identification of these triggers during the history could be a useful tool to identify patients prone to develop EPDS during treatment with EGFR inhibitors.

Potential conflicts of interest

The authors declare no conflicts of interests.

References

- Culy CR, Faulds D. Gefitinib. *Drugs*. 2002;62:2237-48; discussion 2249-50. [PMID: 12381224].
- Park SJ, Gu MJ, Lee DS, et al. EGFR expression in pancreatic intraepithelial neoplasia and ductal adenocarcinoma. *Int J Clin Exp Pathol*. 2015;8:8298-304. [PMID: 26339400].
- Campbell L, Blackhall F, Thatcher N. Gefitinib for the treatment of non-small-cell lung cancer. *Expert Opin Pharmacother*. 2010;11:1343-57. [PMID: 20426712].
- Wnorowski MA, d Souza A, Chachoua A and Cohen DE. The management of EGFR inhibitor adverse events: a case series and treatment paradigm. *Int J Dermatol* 2012;51:223-232. [PMID: 22250636].
- Jalalat SZ, Cohen PR. Gefitinib-associated vitiligo: report in a man with parotid squamous cell carcinoma and review of drug-induced hypopigmentation. *Dermatol Online J*. 2013;19:20020 [PMID: 24139363].
- Lacouture ME, Lai SE. The PRIDE (Papulopustules and/or paronychia, Regulatory abnormalities of hair growth, Itching, and dryness due to epidermal growth factor receptor inhibitors) syndrome. *Br J Dermatol* 2006;155:852-854. [PMID: 16965448].
- Grattan CE, Peachey RD, Boon A. Evidence for a role of local trauma in the pathogenesis of erosive pustular dermatosis of the scalp. *Clin Exp Dermatol* 1988;13:7-10. [PMID: 3061689].
- Watanabe S, Takizawa K, Hashimoto N, Ishibashi Y. Pustular dermatosis of the scalp associated with autoimmune diseases. *J Dermatol* 1989;16:383-387. [PMID: 2574730].
- Aigner B, Legat FJ, Schuster C, El Shabrawi-Caelen L. Sun-induced pustular dermatosis of the scalp. A new variant of erosive pustular dermatosis of the scalp? *Acta Derm Venereol* 2014;94:457-458. [PMID: 24284942].
- Rongioletti F, Delmonte S, Rossi ME, Strani GF, Rebora A. Erosive pustular dermatosis of the scalp following cryotherapy and topical tretinoin for actinic keratoses. *Clin Exp Dermatol* 1999;24:499-500. [PMID: 10681175].
- Guarneri C, Vaccaro M. Erosive pustular dermatosis of the scalp following topical methylaminolaevulinate photodynamic therapy. *J Am Acad Dermatol* 2009;60:521-522. [PMID: 19231656].
- Vaccaro M, Barbuzza O, Guarneri B. Erosive pustular dermatosis of the scalp following treatment with topical imiquimod for actinic keratosis. *Arch Dermatol* 2009;145:1340-1341. [PMID: 19917978].
- Brambilla L, Toulaki A, Nazzaro G. Erosive pustular dermatosis of the scalp induced by ingenol mebutate. *G Ital Dermatol Venereol* 2018;153:743-745. [PMID: 28895376].
- Guarneri C, Cannavò SP. Erosive pustular dermatosis of the scalp from topical minoxidil 5% solution. *Int J Dermatol*. 2013;52:507-509. [PMID: 22040279].
- Vaccaro M, Barbuzza O, Borgia F, Cannavò SP. Erosive pustular dermatosis of the scalp following topical latanoprost for androgenetic alopecia. *Dermatol Ther* 2015;28:65-67. [PMID: 25627907].
- Shahmoradi Z, Abtahi-Naeini B, Pourazizi M. Erosive pustular dermatosis of the scalp following hair transplantation. *Adv Biomed Res*. 2014;3:176. [PMID: 25250290].
- Marzano AV, Ghislanzoni M, Zaghis A, Spinelli D, Crosti C. Localized erosive pustular dermatosis of the scalp at the site of a cochlear implant: successful treatment with topical tacrolimus. *Clin Exp Dermatol* 2008;34:157-159. [PMID: 19094119].
- Patton D, Lynch PJ, Fung MA, Fazel N. Chronic atrophic erosive dermatosis of the scalp and extremities: a recharacterization of erosive pustular dermatosis. *J Am Acad Dermatol*. 2007;57:421-427. [PMID: 17532096].
- Laffitte E, Panizzon RG, Saurat J-H. Delayed wound healing on the scalp following treatment of actinic keratoses: erosive pustular dermatosis of the scalp. *Dermatol Surg* 2004;30:1610. [PMID: 15606863].
- Tomasini C, Michelerio A. Erosive pustular dermatosis of the scalp: A neutrophilic folliculitis within the spectrum of neutrophilic dermatoses: A clinicopathologic study of 30 cases. *J Am Acad Dermatol*. 2019;81:527-533. [PMID: 30617027].
- Marzano AV, Borghi A, Wallach D, Cugno M. A comprehensive review of neutrophilic diseases. *Clin Rev Allergy Immunol*. 2018;54:114-130. [PMID: 28688013].
- Marzano AV, Fanoni D, Antiga E, et al. Expression of cytokines, chemokines and other effector molecules in two prototypic autoinflammatory skin diseases, pyoderma gangrenosum and Sweet's syndrome. *Clin Exp Immunol*. 2014;178:48-56. [PMID: 24903614].
- Marzano AV, Ortega-Loayza AG, Heath M, Morse D, Genovese G, Cugno M. Mechanisms of inflammation in neutrophil-mediated skin diseases. *Front Immunol*. 2019;10:1059. [PMID: 31139187].
- Wu CY, Chen GS, Lan CC. Erosive pustular dermatosis of the scalp after gefitinib and radiotherapy for brain metastases secondary to

- lung cancer. *Clin Exp Dermatol* 2008;33:106-107 [PMID: 17983449].
25. Toda N, Fujimoto N, Kato T, Fujii N, Nakanishi G, Nagao T et al. Erosive pustular dermatosis of the scalp-like eruption due to gefitinib: case report and review of the literature of alopecia associated with EGFR inhibitors. *Dermatology* 2012;225:18-21. [PMID: 22922680].
 26. Fukui T, Kitamura H, Harada K, Nakano H, Sawamura D. Trichoscopic findings of erosive pustular dermatosis of the scalp associated with Gefitinib. *Case Rep Dermatol*. 2017;9:44-49. [PMID: 28690518].
 27. Starace M, Iorizzo M, Trüeb RM, et al. Erosive pustular dermatosis of the scalp: a multicentre study. *J Eur Acad Dermatol Venereol*. 2020;34:1348-1354. [PMID: 31954062].
 28. Lee KH, Carley SK, Kraus CN, Mesinkovska NA. Treatment of erosive pustular dermatosis: a systematic review of the literature. *Int J Dermatol*. 2020;59:770-786. [PMID: 31904115].
 29. Owczarek W, Słowińska M, Lesiak A, et al. The incidence and management of cutaneous adverse events of the epidermal growth factor receptor inhibitors. *Postepy Dermatol Alergol*. 2017;34:418-428. [PMID: 29507555].