

UC Davis

Dermatology Online Journal

Title

Ichthyosis follicularis with alopecia and photophobia syndrome (IFAP): A Case Report

Permalink

<https://escholarship.org/uc/item/8vx6n6n1>

Journal

Dermatology Online Journal, 23(2)

Authors

Ferrari, Bruno
Morita, Lucila
Choate, Keith
[et al.](#)

Publication Date

2017

DOI

10.5070/D3232033967

Copyright Information

Copyright 2017 by the author(s). This work is made available under the terms of a Creative Commons Attribution-NonCommercial-NoDerivatives License, available at <https://creativecommons.org/licenses/by-nc-nd/4.0/>

Peer reviewed

Ichthyosis follicularis with alopecia and photophobia syndrome (IFAP): A Case Report

Bruno Ferrari MD¹, Lucila Morita MD¹, Margarita Larralde MD PhD^{1,2}, Keith Choate MD PhD³, Rong-Hua Hu MD PhD³

Affiliations: ¹Pediatric Dermatology Section, Hospital Ramos Mejía. Buenos Aires, Argentina, ²Dermatology Service, Hospital Alemán. Buenos Aires, Argentina, ³Dermatology, Genetic and Pathology Department, Yale University. New Haven, Connecticut, USA

Corresponding Author: Bruno Ferrari, Email: brunoferraripiel@gmail.com

Abstract

IFAP syndrome is a rare autosomal recessive X-linked disease characterized by the triad of alopecia universalis, severe photophobia, and follicular ichthyosis. It is caused by loss of function of the gene MBTPS2. Its severity varies and there are only a few reports in the literature. We present a patient with characteristic clinical features and a mutation not previously reported.

Keywords: Ichthyosis, alopecia; photophobia

Introduction

IFAP syndrome is an unusual autosomal recessive X-linked disease characterized by the triad of alopecia universalis, severe photophobia, and follicular ichthyosis [1-4]. Other findings may determine variations in its clinical presentation [1,4,5]. It is caused by loss of function of the gene MBTPS2, essential for cholesterol homeostasis. Twenty different mutations of this gene have been reported [2]. Treatment is based on emollients and retinoids [1,5].

Case Synopsis

An 18-month-old boy with a history of collodion baby and congenital hypothyroidism was referred for cutaneous signs present since birth. These were characterized by spiny hyperkeratotic papules localized on scalp, ears, cheeks, elbows, and knees and periungual erythema on his hands associated with generalized alopecia and photophobia (**Figure 1**).

He also showed facial dysmorphism, atopic dermatitis-like lesions, and plantar keratoderma (**Figure 2**).

The patient's height was below normal for his age. Dysgeusia was also observed. Ophthalmic examination revealed keratitis and corneal neovascularization. The pathology of follicular papules showed follicular keratosis. The genetic study found a mutation in the gene MBTPS2 E11 homozygous c. 1433 C> A, p. 478 A>D. This mutation had not been reported previously. These data confirmed the presumptive diagnosis of IFAP syndrome. The patient was treated with levothyroxine, general humectant measures, and eye lubrication.



Figure 1. A, B) Spiny hyperkeratotic papules localized on the scalp and left arm. C) Dystrophic nail with periungual erythema.

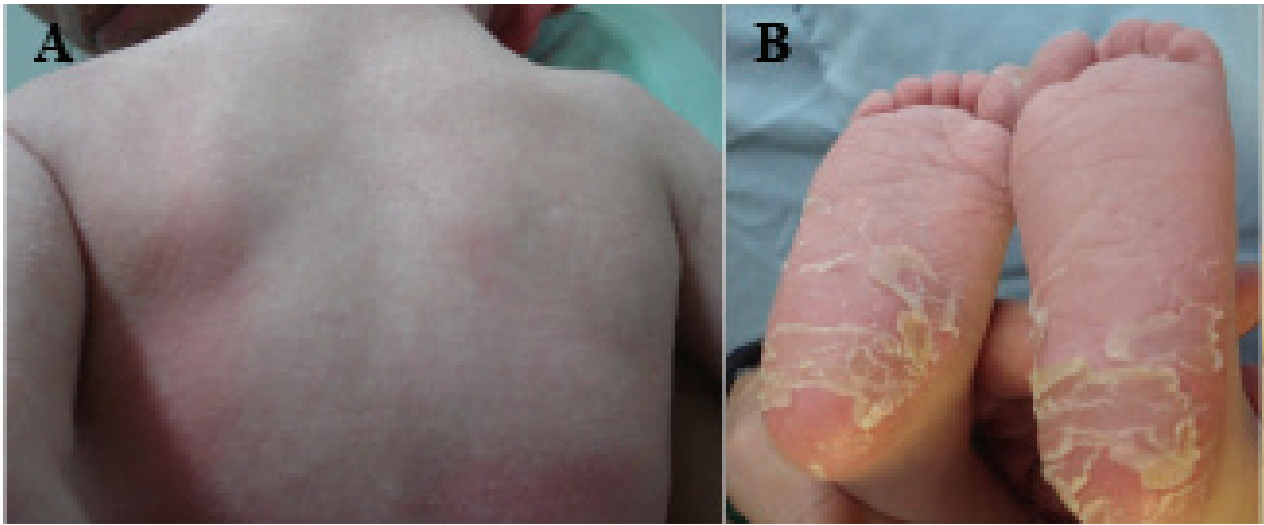


Figure 2. A) Atopic dermatitis like lesions in dorsum, and B) keratoderma.

Case Discussion

IFAP syndrome is a rare autosomal recessive X-linked disease [1-4]. It is characterized by the triad of alopecia universalis, severe photophobia, and spiny keratotic follicular papules distributed symmetrically on scalp and along the extensor surfaces of the extremities [5]. At birth, patients may present as collodion babies. Alopecia is non scarring, congenital [5], non-progressive, and widespread. Up to 40% of patients also have psoriasiform plaques, cheilitis, hypohydrosis, nail dystrophy, atopic dermatitis, and rarely, keratoderma [4,5]. Photophobia may be congenital or develop later in life. It is owing to corneal defects: erosion, ulcers, scars, and neo-vascularization [1]. Blindness and myopia are common [1,5]. Mental retardation, seizures, and hypotonia are frequent [1,4,5]. Nevertheless, our patient did not show neurologic involvement. Other findings include asthma, allergic reactions, recurrent infections, and enteropathy [4,5]. Histopathology of skin lesions is nonspecific [4,5].

Loss of function of the MBTPS2 gene is the cause of this disease. This gene encodes a zinc metalloproteinase intramembrane essential for cholesterol homeostasis and response of the endoplasmic reticulum to stress [3]. Clinical severity ranges from mild to severe cutaneous forms [2]. At present, 20 different mutations of this gene [2] have been reported. In our patient, a previously unreported mutation was found. Treatment for follicular ichthyosis is based on urea emollients, local corticosteroids, and retinoids [1,5]. Photophobia and seizures may improve

spontaneously [1], although sometimes antiseizure drugs are required [5]. Life expectancy varies between death in the neonatal period and a normal survival [4,5].

References

1. Höpker L.M., Ribeiro C.G., Oliveira L.M., Moreira A.T. Ichthyosis follicularis, alopecia and photophobia syndrome (IFAP): report of the first case with ocular and cutaneous manifestations in Brazil with a favorable response to treatment, *Arq. Bras.Oftalmol.*, 2011, 74: 55-57. [PMID: 21670910]
2. Fong K, Takeichi T, Liu L et al. Ichthyosis follicularis, atrichia, and photophobia syndrome associated with a new mutation in MBTPS2. *Clinical and Experimental Dermatology* 2015. 40: 529–532. [PMID: 25683132]
3. Bornholdt D., Atkinson T.P., Bouadjar B., Catteau B., et al. Genotype-phenotype correlations emerging from the identification of missense mutations in MBTPS2. *Hum.Mutat*, 2013, 34: 587-594. [PMID: 23316014]
4. Mégarbané H., Mégarbané A. Ichthyosis follicularis, alopecia, and photophobia (IFAP) syndrome, *Orphanet. J. Rare. Dis.*, 2011, 6: 29. [PMID: 21600032]
5. Chauhan S., Gahalaut P., Chandra K. Ichthyosis follicularis alopecia and photophobia syndrome: transient improvement with oral isotretinoin, *Indian. J. Paediatr. Dermatol.*, 2015, 16: 39-41.