

UC Davis

Dermatology Online Journal

Title

Mycobacterium haemophilum infection in a renal transplant patient with inflammatory bowel disease

Permalink

<https://escholarship.org/uc/item/8vs8509k>

Journal

Dermatology Online Journal, 23(9)

Authors

Krueger, Steven
Rork, Jillian
Lee, Jennifer
et al.

Publication Date

2017

DOI

10.5070/D3239036487

Copyright Information

Copyright 2017 by the author(s). This work is made available under the terms of a Creative Commons Attribution-NonCommercial-NoDerivatives License, available at <https://creativecommons.org/licenses/by-nc-nd/4.0/>

Peer reviewed

***Mycobacterium haemophilum* infection in a renal transplant patient with inflammatory bowel disease**

Steven Krueger¹ BS, Jillian Rork² MD, Jennifer Lee¹ MD, Kristine Cornejo³ MD, Laura Gibson⁴ MD, Jennifer S Daly⁴ MD, Nikki A Levin² MD PhD

Affiliations: ¹University of Massachusetts Medical School, Worcester, Massachusetts ²Department of Dermatology, University of Massachusetts Medical School, Worcester, Massachusetts ³Department of Pathology, University of Massachusetts Medical School, Worcester, Massachusetts ⁴Infectious Diseases and Immunology, Departments of Medicine and Pediatrics, University of Massachusetts Medical School, Worcester, Massachusetts

Corresponding Author: Nikki A. Levin, Department of Dermatology, University of Massachusetts Medical School, 281 Lincoln St., Worcester, MA 01605, Tel: 508-334-5588, Fax: 508-334-5981, Email: nikki.levin@umassmemorial.org

Abstract

A 61-year-old immunosuppressed renal transplant patient with inflammatory bowel disease presented with tender pink nodules on the trunk and extremities. An initial biopsy was suggestive of metastatic Crohn disease, but after disease persistence, a second biopsy revealed disseminated *Mycobacterium haemophilum*. Atypical mycobacterial infections should be considered in immunosuppressed patients. This case highlights the complexities of diagnosing such infections in patients with an underlying granulomatous condition and the particular growth requirements of *M. haemophilum*.

Keywords: *Mycobacterium haemophilum*, atypical mycobacterial infections, immunosuppression, inflammatory bowel disease

Case Synopsis

A 61-year-old woman with a history of Crohn disease and renal transplantation on immunosuppressive medication presented to the emergency department with skin lesions and intermittent fevers. She reported tender pink nodules on her left breast and right wrist for 5 months and a similar eruption on her arms, legs, and abdomen for 1 week. She was admitted and treated with intravenous vancomycin for presumed cellulitis. This treatment did not completely clear her lesions and a dermatology consult was requested for further evaluation.

Past medical history was significant for Crohn disease, status-post ileostomy and colectomy, chronic obstructive pulmonary disease, chronic venous stasis dermatitis, and end-stage renal disease from acute tubular necrosis. She was status-post renal transplantation complicated by *Candida glabrata* infection. Daily medications included sirolimus, prednisone, hydrochlorothiazide, doxepin, gabapentin, escitalopram, and atorvastatin.

Prior to admission, she was seen by an outpatient dermatologist. A punch biopsy of a tender pink nodule on the right medial thigh was performed, which showed superficial and deep perivascular interstitial infiltrates composed of lymphocytes and small aggregates of histiocytes forming granulomas. The process extended into the subcutis showing panniculitis, but the sample size limited the ability to determine a septal versus lobular process. Stains

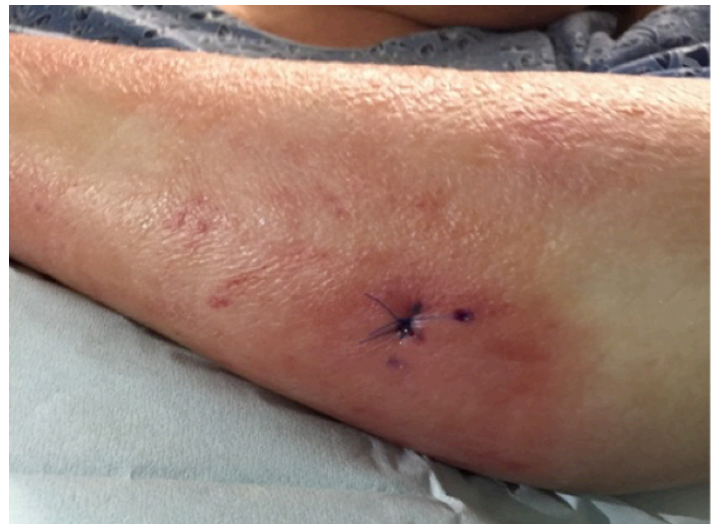

Figure 1. Tender erythematous nodule at biopsy site on left forearm.

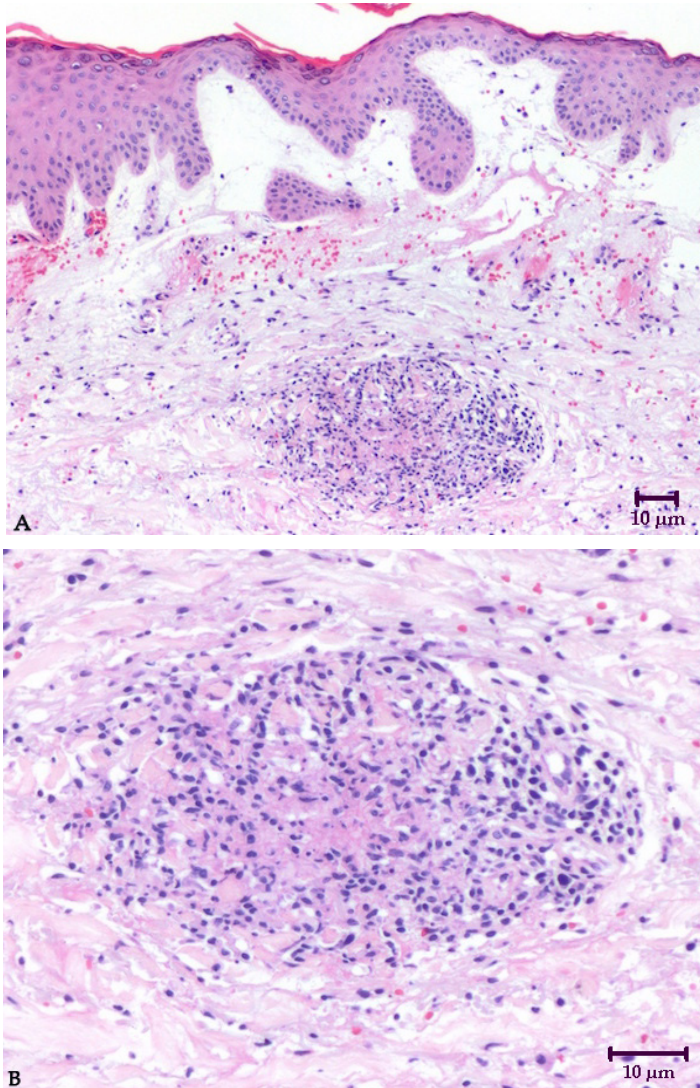


Figure 2. A) H&E stain of left forearm biopsy, 100x. B) H&E stain of left forearm biopsy, 200x.

for bacteria, fungi, and mycobacteria showed no pathogenic organisms. These findings were thought likely to be related to her inflammatory bowel disease, potentially metastatic Crohn disease. Her prednisone was temporarily increased with improvement of nodules; however, they quickly recurred after tapering.

In the hospital, physical examination revealed generalized edema of the extremities. There were several firm, edematous, erythematous nodules on her left upper extremity (**Figure 1**) with a peau d'orange appearance. On her left breast and upper and lower extremities were scattered well-circumscribed, indurated erythematous plaques. The differential diagnosis was broad and included cellulitis, panniculitis, vasculitis, metastatic Crohn disease, and an opportunistic infection.

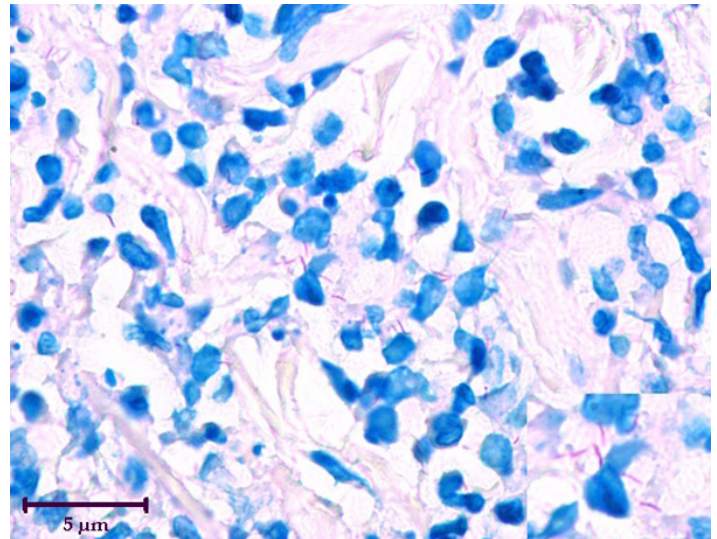


Figure 3. Mycobacteria highlighted by Fite stain, 600x.

Relevant laboratory testing revealed elevated C-reactive protein at 32.7mg/L and elevated erythrocyte sedimentation rate at over 120mm/h. Her white blood cell count was within normal limits with a neutrophil predominance.

A punch biopsy from the left forearm was performed (**Figure 2**) and revealed a dense perivascular lymphocytic and interstitial granulomatous infiltrate with scattered nuclear dust and focal microabscesses. Acid-fast bacillus (AFB) and Fite stains showed many mycobacteria within and outside granulomas (**Figure 3**). Another punch biopsy for tissue culture was performed and polymerase chain reaction (PCR) and culture subsequently allowed diagnosis of *M. haemophilum*.

Given the diagnosis of disseminated cutaneous *M. haemophilum*, the patient was treated initially with ciprofloxacin 500 mg daily, azithromycin 250 mg daily, and rifabutin 300 mg daily. Ciprofloxacin was discontinued after two months once susceptibility results showed resistance to the drug. Within several weeks of treatment, nodules became less swollen and tender, and eventually resolved. The treatment was continued for approximately seven months; azithromycin was continued at 250 mg every other day for prophylaxis. The patient has had no recurrence for almost two years.

Case Discussion

In this case, we present an immunosuppressed renal transplant patient with Crohn disease who

was ultimately found to have disseminated *M. haemophilum*. Atypical mycobacterial infections are often in the differential diagnosis in immunosuppressed patients. This case highlights the complexities of diagnosing such infections in a patient with an underlying granulomatous condition and the challenge of identifying atypical mycobacteria.

M. haemophilum, a slow-growing acid-fast bacillus, was first described in 1978 [1]. Generally, there is no person-to-person transmission [2] and water reservoirs are believed to be a possible environmental source [3]. *M. haemophilum* had been reported 218 times worldwide as of 2011 [3] and there have been another 36 cases reported to date. However, the incidence of infection is likely underestimated owing to its distinct growth requirements [4, 5]. *M. haemophilum* grows optimally at 30 to 32 degrees Celsius [3]. Standard isolation techniques used for other mycobacteria, which typically grow best at 37 degrees Celsius, are not adequate for isolation of this organism. A diagnostic regimen described in the literature includes acid-fast staining, culture with iron-supplemented media at two temperatures, and molecular detection [3, 6].

M. haemophilum is not only challenging to culture, but also difficult to identify by acid-fast staining. Three reported cases of *M. haemophilum* bacilli were found only after a second acid-fast bacilli stain was obtained [4]. Our case was similar in that the initial stains were negative. These collective experiences underscore the need for a high clinical suspicion when interpreting negative stains and cultures, particularly when atypical mycobacteria are in the differential diagnosis.

Our case was additionally complicated by the fact that our patient had Crohn disease. The original biopsy showing dermal granulomas and panniculitis was reasonably considered to be metastatic Crohn disease. Our patient was then treated with further immunosuppression, a potentially harmful choice in the setting of a disseminated infection. Although it is certainly possible that the original biopsy was in fact metastatic Crohn disease, in hindsight, these findings were likely *M. haemophilum*.

There is a wide spectrum of cutaneous manifestations of *M. haemophilum* infections. Common lesions include tender nodules, papules, and ulcers, but others include purpura, abscesses, and open fistulas draining purulent material [2, 4, 6]. These cutaneous lesions are usually multiple and most commonly involve the extremities, but occasionally may be found on the face, abdominal wall, gluteal areas, and breast regions [2]. In a prior case report, the clinical findings have been described to mimic the skin lesions of leprosy [6]. *M. haemophilum* has reportedly caused disseminated skin infections in severely immunocompromised adults, including recipients of renal transplantation [7]. It can also occur in otherwise healthy children who develop cervical and perihilar lymphadenitis [3, 4].

There is also a range of histologic patterns associated with *M. haemophilum* infection. In one case series, the most common histologic pattern was a mixed suppurative and granulomatous reaction that was either limited to the dermis or extended into the subcutis [4]. When the subcutis was involved, it was in the pattern of a mixed lobular and septal panniculitis. Other histologic patterns included well-formed epithelioid granulomas that tended to be located near sweat glands, an interface dermatitis with a perivascular and periadnexal lymphocytic infiltrate, a necrotizing lymphocytic small vessel vasculitis that lacked a granulomatous tissue reaction altogether, and abscesses. This variety suggests one cannot rely on the presence of granulomas alone to consider a potential atypical mycobacterial etiology, especially in an immunocompromised patient [4].

At present, there are no standard treatments for this rare infection. It appears to be susceptible to ciprofloxacin, clarithromycin, rifabutin, and clofazimine, but resistant to isoniazid and ethambutol [3]. Published literature generally supports the use of multiple antibiotics for a duration of 12 to 24 months, with the therapeutic regimen modified to fit the individual's disease presentation and underlying immunosuppression [5].

Conclusion

In summary, our case highlights the potential challenge of diagnosing *M. haemophilum* and the importance of considering atypical mycobacteria

in the differential diagnosis of granulomatous skin lesions, particularly in an immunosuppressed patient. *M. haemophilum* is difficult to culture and often hard to identify even with special stains, and thus may require multiple biopsies and tissue culture for diagnosis.

References

1. Sompolinsky, D., A. Lagziel, and I. Rosenberg. Further studies of a new pathogenic mycobacterium (*M. haemophilum* sp. nov.). *Can J Microbiol.* 1979; 25:217-226. [PMID: 436017].
2. Woods GL, Washington JA, 2nd. Mycobacteria other than *Mycobacterium tuberculosis*: review of microbiologic and clinical aspects. *Rev Infect Disease.* 1987 Mar-Apr;9(2):275-94. [PMID: 3296098].
3. Lindeboom JA, Bruijnesteijn van Coppenraet L, Van Soolingen D. Clinical manifestations, diagnosis, and treatment of mycobacterium haemophilum infections. *Clin Microbiol Rev.* 2011; 24(4): 701-717. [PMID: 21976605].
4. Busam KJ, Kiehn TE, Salob SP, Myskowski PL. Histologic reactions to cutaneous infections by *Mycobacterium haemophilum*. *Am J Surg Pathol.* 1999 Nov;23(11):1379-85. [PMID: 10555006].
5. Rajpara A, Sri J, Driscoll M. Mycobacterium haemophilum: Cutaneous nodules in a renal transplant patient. *Dermatol Online J.* 2010; 16(7). [PMID: 20673531].
6. CopelandNK, AroraNS, FergusonTM. Mycobacterium haemophilum masquerading as leprosy in a renal transplant patient. *Case Rep Dermatol Medicine.* 2013; 2013:1-3. [PMID: 24369511].
7. Castro-Silva AN, Freire AO, Grinbaum RS, et al. Cutaneous mycobacterium haemophilum infection in kidney transplant recipient after acupuncture treatment. *Transpl Infect Dis.* 2011; 13(1): 33-37. [PMID: 20534038].