

# UC Davis

## Dermatology Online Journal

### Title

Paraneoplastic Pemphigus in a 34-year-old

### Permalink

<https://escholarship.org/uc/item/8sf4c5xn>

### Journal

Dermatology Online Journal, 23(12)

### Authors

Melnick, Laura E  
Beasley, Jenna M  
Kim, Randi  
[et al.](#)

### Publication Date

2017

### DOI

10.5070/D32312037677

### Copyright Information

Copyright 2017 by the author(s). This work is made available under the terms of a Creative Commons Attribution-NonCommercial-NoDerivatives License, available at <https://creativecommons.org/licenses/by-nc-nd/4.0/>

Peer reviewed

# Paraneoplastic Pemphigus in a 34-year-old

Laura E Melnick MD, Jenna M Beasley MD, Randi Kim MD PhD, Dr Nooshin Brinster MD, Kristen Lo-Sicco MD

Affiliations: New York University Health, New York

## Abstract

Paraneoplastic Pemphigus (PNP) is a rare and often fatal autoimmune mucocutaneous blistering disease associated with an underlying malignancy. It is thought to be caused by antibodies to tumor antigens cross-reacting with epithelial antigens, specifically desmosomal and hemidesmosomal antigens. There are at least five clinical morphologic variants of PNP, with the earliest and most consistent finding being severe stomatitis. Diagnosis of PNP requires direct immunofluorescence of perilesional skin and indirect immunofluorescence. Treatment of PNP is difficult and largely limited to glucocorticoids, steroid-sparing immunomodulators, rituximab and intravenous immunoglobulin (IVIG). Despite therapies, prognosis is poor. We report a case of paraneoplastic pemphigus in a 34-year old male with severe stomatitis and lichen planus-like cutaneous lesions.

*Keywords: paraneoplastic pemphigus, pemphigus*

## Introduction

**HISTORY:** A 34-year-old man with a 6-year history of a partially-resected abdominal desmoid tumor presented to the Skin and Cancer Unit for the evaluation of a progressive skin and mucous membrane eruption of six-months duration.

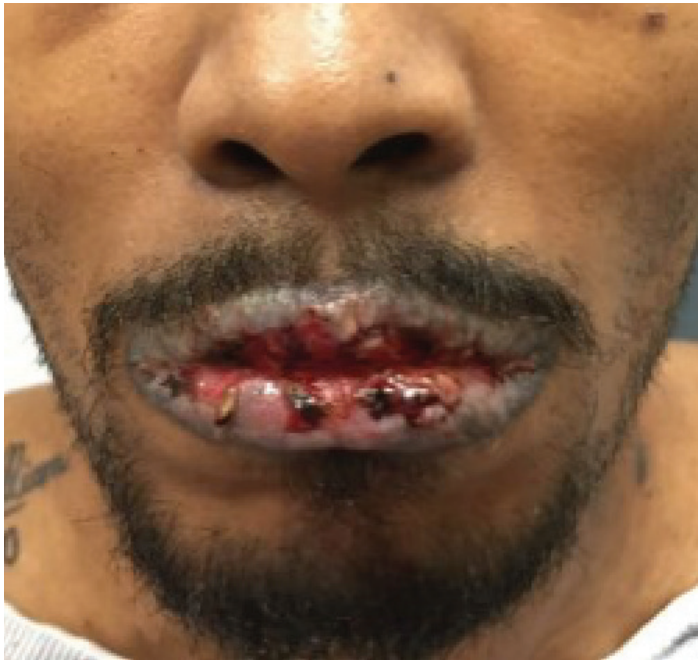The eruption began with development of painful erosions and ulcerations on the lips and tongue. Gradually over the following months, the eruption progressed to involve the chest, back, abdomen, arms, legs and genitals. The cutaneous lesions were described as dark, pruritic papules and plaques that

frequently developed painful erosions within them. At time of presentation, the patient denied fevers, chills, cough or shortness of breath.

Approximately six months prior to presentation, the patient was admitted to an outside hospital for hematemesis. At that time, he was noted to have significant hepatosplenomegaly and portal hypertension of unclear etiology, for which he underwent a transjugular intrahepatic portosystemic shunt (TIPS) procedure. Inpatient laboratory work was notable for leukopenia, a low CD4 count and anemia of unclear etiology. Imaging was notable for significant hepatosplenomegaly, diffuse lymphadenopathy and an undiagnosed mesenteric mass in the right upper quadrant. Core biopsy of the mass in the right upper quadrant was preformed, which showed lymphoid tissue with a rich vascular network, findings favoring a reactive process. The abdominal desmoid tumor, which was diagnosed six years earlier and was treated with chemotherapy and partially resected, remained stable in size.

At the time of hospital discharge, the patient remained immunocompromised, and there continued to be no unifying diagnosis. Mucocutaneous lesions were present during admission; however, gradual progression and worsening of them did not occur until after discharge. Dermatology was not consulted during hospitalization. The patient was seen by an outside dermatologist and subsequently referred to the Skin and Cancer Unit.

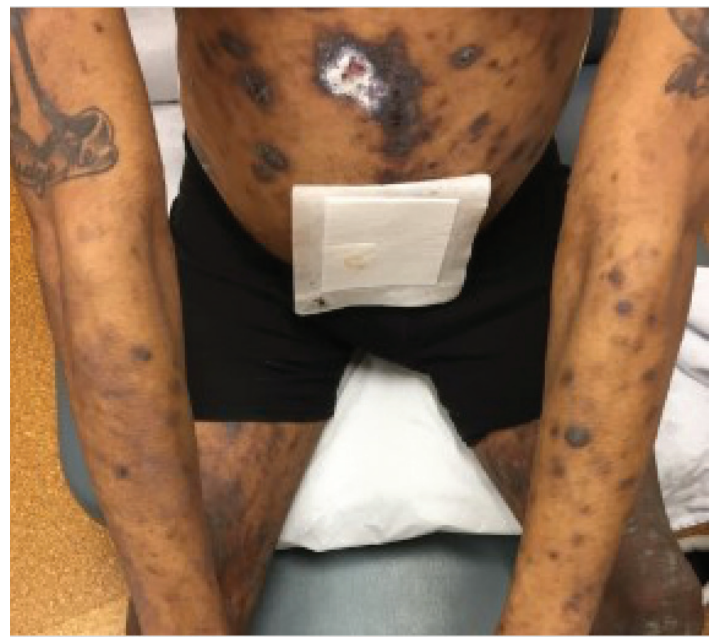**PHYSICAL EXAMINATION:** There were widespread violaceous papules and plaques, some with a fine, adherent, greyish-white scale, over the abdomen, back, upper extremities, lower extremities, palms and soles. Within a large plaque on the back and a



**Figure 1.** Hemorrhagic erosions extending from the cutaneous to the mucosal lips, buccal mucosa and tongue.

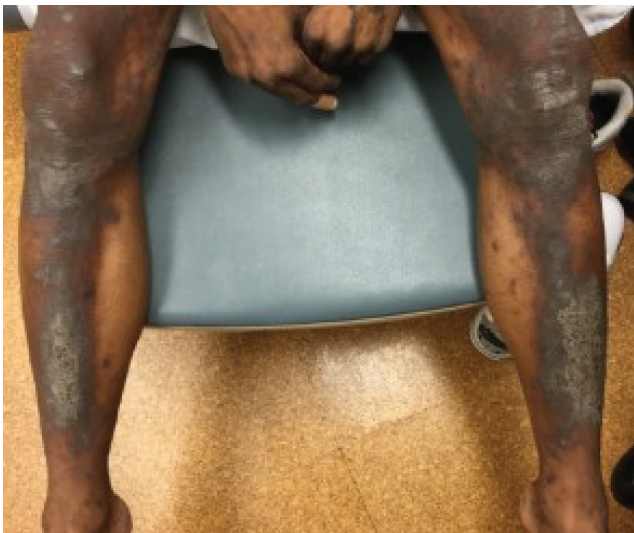
large plaque on the abdomen, there were superficial erosions. On the upper and lower cutaneous lips there were hemorrhagic erosions that extended from the cutaneous to mucosal lips, buccal mucosa and tongue. Erosions were present surrounding the urethral meatus and the corona of the glans penis. Nikolsky's sign was negative.

**LABORATORY DATA:** A complete blood count with differential at time of presentation demonstrated pancytopenia with a low white blood count of  $2.0 \times 10^9/L$ , low CD4 count of less than 20 cells/mm<sup>3</sup>, low hemoglobin of 6.9 g/dL and low platelets of 100

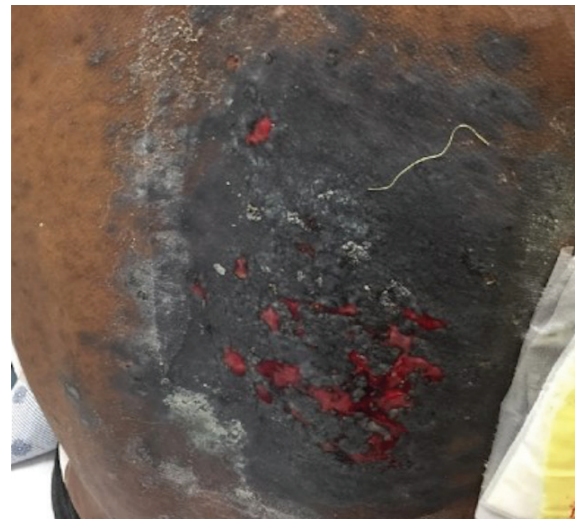

**Figure 2.** Violaceous papules and plaques, some with a fine, adherent, greyish-white scale and erosions, over the abdomen and upper extremities.

$\times 10^9/L$ . The absolute neutrophil count was normal. The erythrocyte sedimentation rate and C-reactive protein level were elevated at 70 mm/hr and 2.4 mg/L, respectively. A complete metabolic panel was unremarkable with the exception of an elevated alkaline phosphatase of 384 IU/L, low albumin of 2.4 g/dL and low calcium of 7.8 mg/dL, which normalized when corrected for hypoalbuminemia. Hepatitis A, B, and C serologies and human immunodeficiency virus testing were negative. Bone marrow biopsy was normal.

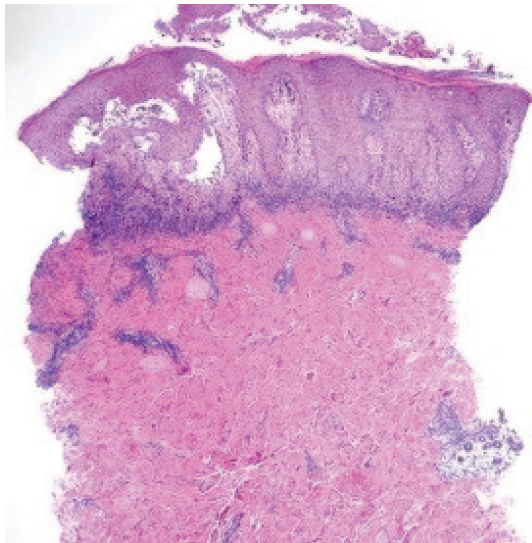


**Figure 3.** Violaceous plaques, with a fine, adherent, greyish-white scale, over the lower extremities.

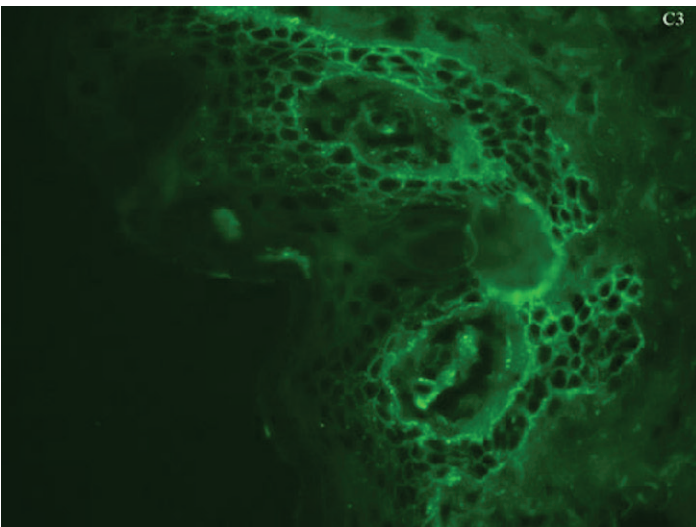


**Figure 4.** Large violaceous plaque on the back with superficial erosions.

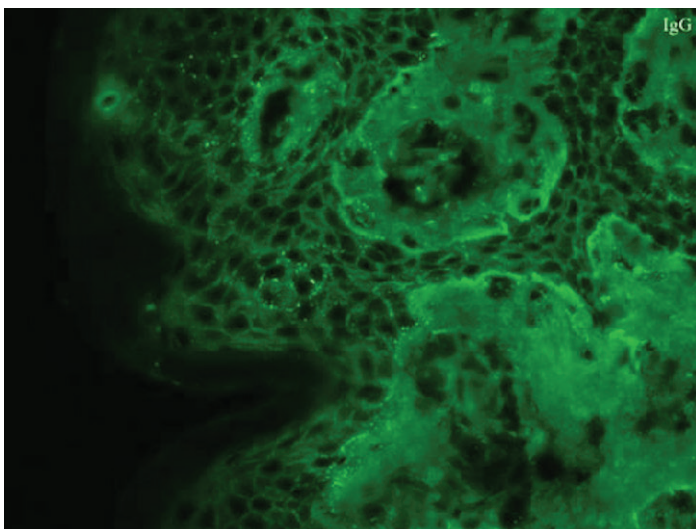




**Figure 5.** Hematoxylin and Eosin.



**Figure 6.** Direct immunofluorescence, C3 deposition.



**Figure 7.** Direct immunofluorescence, IgG deposition.

Indirect immunofluorescence for paraneoplastic pemphigus demonstrated positive IgG titers to rat bladder substrate, mouse bladder substrate, mouse heart substrate and mouse liver substrate. Additionally, there were positive IgG titers to monkey esophagus and intact human skin. IgG antibodies to desmoglein 1 were negative. IgG antibodies to desmoglein 3 were borderline/indeterminate.

**HISTOPATHOLOGY:** Two punch biopsies of the right lowerback, onelesionalforhematoxylinandeosin(H&E) and one perilesional for direct immunofluorescence, were performed. On H&E, there was epidermal acanthosis with hypergranulosis and orthokeratosis associated with a band-like lymphoplasmacytic infiltrate, with occasional eosinophils, melanophages and interface inflammation along the dermal-epidermal junction. In addition, there were necrotic keratinocytes in the lower to mid-portion of the epidermis, as well as suprabasilar acantholysis. Direct immunofluorescence demonstrated intracellular deposition of IgG between the keratinocytes in the lower epidermis and along the dermal-epidermal junction. There was weak deposition of C3 and no significant deposition of IgA, IgM or fibrinogen.

**Conclusion:** Paraneoplastic pemphigus (PNP) is a rare and often fatal autoimmune mucocutaneous blistering disease [1]. This disease was first recognized in 1990 by Anhalt et al, who described five cases of atypical pemphigus that were associated with neoplasia [2]. PNP typically affects adults between the ages of 45-70 [3], but has also been reported in children and adolescents [4, 5].

At least five clinical morphologic variants of PNP exist. Cutaneous lesions may be classified as pemphigus-like, bullous pemphigoid-like, erythema multiforme-like, graft-versus-host disease or lichen planus-like [1, 6-8]. In all variants, the earliest and most consistent finding is stomatitis, which is frequently hemorrhagic and spreads to involve the entire vermillion and tongue [1, 6, 8]. In contrast to other forms of pemphigus, PNP may involve the mucous membranes of the gastrointestinal tract and the pulmonary epithelium. As a result, patients with PNP can develop life threatening, irreversible bronchiolitis obliterans [3, 9].

Diagnosis of PNP is based on clinical, histological and immunofluorescence findings. The most common histopathologic findings include suprabasal acantholysis, keratinocyte necrosis and a lichenoid interface dermatitis, though the histology will often vary based on the morphology of the skin eruption, and thus diagnosis may be challenging [10, 11]. Direct immunofluorescence (DIF) examination will reveal intracellular deposits of C3 and IgG and linear deposits of C3 and IgG along the dermal-epidermal junction. Indirect immunofluorescence (IIF) reveals IgG antibodies that not only bind with stratified epithelium of monkey esophagus, but also with the transitional and cylindrical epithelium of urinary bladder, bronchi, small intestine, colon, myocardium and skeletal muscles in rats and mice [1, 8, 12]. IIF is particularly useful for differentiating PNP from pemphigus vulgaris, with the latter only binding with stratified epithelium of monkey esophagus.

PNP is associated with both benign and malignant neoplasms, with the most frequently reported malignancies being non-Hodgkin lymphoma, followed by chronic lymphocytic leukemia, Castleman's disease, sarcoma, thymoma and Waldenstrom's macroglobulinemia, Hodgkin lymphoma, monoclonal gammopathy and melanoma. [1, 13]. In up to one-third of patients, the diagnosis of PNP occurs prior to the discovery of an underlying malignancy [1, 7]. To date, the pathogenesis of PNP is not fully understood. Cutaneous and mucocutaneous lesions are thought to be caused by antibodies to tumor antigens cross-reacting with epithelial antigens, specifically desmosomal and hemidesmosomal antigens [1].

Treatment of PNP is a challenge and involves suppression of the disease manifestations, management of patient's symptoms and treating the underlying malignancy. The best outcomes have been reported with benign neoplasms that have been surgically excised [14]. In inoperable or malignant neoplasms, several interventions have demonstrated efficacy in reducing PNP symptoms. These therapies include glucocorticosteroid therapy in combination with a steroid sparing agent such as cyclosporine, cyclophosphamide, azathioprine and mycophenolate mofetil [15]. Rituximab and intravenous immunoglobulin (IVIG) are being

used more often in patients with PNP due to the reduced tumorigenicity and immunosuppressive risk. Unfortunately, PNP is often resistant to treatment and may progress independent of the status of the underlying malignancy [16].

Traditionally, PNP has been thought to carry a mortality rate of 75-90% and a mean survival of less than one year, with the major cause of death being respiratory failure [12, 17]. In 2012, a French multicenter retrospective study of 53 patients with PNP, who received a variety of therapies, suggested the prognosis of PNP may be better than once thought, with one, three and five-year overall survival rates of 49, 41 and 38 percent, respectively [12].

Our patient was initially managed with 40mg of oral prednisone daily. Prednisone was slowly tapered after initiation of IVIG. The patient has had improvement in his skin eruption; however, no underlying malignancy has been discovered. To date, there are no reports in the literature of a desmoid tumor association with PNP. The patient continues to follow with hematology and oncology and is actively being worked up for a hematologic malignancy or lymphoproliferative disorder.

## References

1. Wieczorek M, Czernik A. Paraneoplastic pemphigus: a short review. *Clin Cosmet Investig Dermatol*. 2016;9:291-295. [PMID: 27729809].
2. Anhalt GJ, Kim SC, Stanley JR, et al. Paraneoplastic pemphigus. An autoimmune mucocutaneous disease associated with neoplasia. *N Engl J Med* 1990; 323:1729. [PMID: 2247105].
3. Czernik A, Camilleri M, Pittelkow MR, Grando SA. Paraneoplastic autoimmune multiorgan syndrome: 20 years after. *Int J Dermatol* 2011; 50:905. [PMID: 21781058].
4. Mimouni D, Anhalt GJ, Lazarova Z, et al. Paraneoplastic pemphigus in children and adolescents. *Br J Dermatol* 2002; 147:725. [PMID: 12366419].
5. Lane JE, Woody C, Davis LS, et al. Paraneoplastic autoimmune multiorgan syndrome (paraneoplastic pemphigus) in a child: case report and review of the literature. *Pediatrics* 2004; 114:e5 [PMID: 15466078].
6. Ohzono A, Sogame R, Li X, et al. Clinical and immunological findings in 104 cases of paraneoplastic pemphigus. *Br J Dermatol* 2015; 173:1447. [PMID: 26358412].
7. Sehgal VN, Srivastava G. Paraneoplastic pemphigus/paraneoplastic autoimmune multiorgan syndrome. *Int J Dermatol* 2009; 48:162. [PMID: 19200194].
8. Joly P, Richard C, Gilbert D, et al. Sensitivity and specificity of clinical, histologic, and immunologic features in the diagnosis of paraneoplastic pemphigus. *J Am Acad Dermatol* 2000; 43:619. [PMID: 11004616].
9. Nguyen VT, Ndoye A, Bassler KD, et al. Classification, clinical manifestations, and immunopathological mechanisms of the epithelial variant of paraneoplastic autoimmune multiorgan

- syndrome: a reappraisal of paraneoplastic pemphigus. *Arch Dermatol* 2001; 137:193. [PMID: 11176692].
10. Billet SE, Grando SA, Pittelkow MR. Paraneoplastic autoimmune multiorgan syndrome: review of the literature and support for a cytotoxic role in pathogenesis. *Autoimmunity* 2006; 39:617. [PMID: 17101506].
  11. Weedon D. The vesicobullous reaction pattern. In: *Weedon's Skin Pathology*, 3rd ed, Elsevier Limited, Edinburgh 2010. p.123.
  12. Leger S, Picard D, Ingen-Housz-Oro S, et al. Prognostic factors of paraneoplastic pemphigus. *Arch Dermatol* 2012; 148:1165. [PMID: 22801794].
  13. Kaplan I, Hodak E, Ackerman L, et al. Neoplasms associated with paraneoplastic pemphigus: a review with emphasis on non-hematologic malignancy and oral mucosal manifestations. *Oral Oncol* 2004; 40:553. [PMID: 15063382].
  14. Fang Y, Zhao L, Yan F, et al. A critical role of surgery in the treatment for paraneoplastic pemphigus caused by localized *Castleman's disease*. *Med Oncol* 2010; 27:907. [PMID: 19763912].
  15. Frew JW, Murrell DF. Current management strategies in paraneoplastic pemphigus (paraneoplastic autoimmune multiorgan syndrome). *Dermatol Clin* 2011; 29:607. [PMID: 21925005].
  16. Anhalt GJ. Paraneoplastic pemphigus. *J Investig Dermatol Symp Proc* 2004; 9:29. [PMID: 14870982].
  17. Zhu X, Zhang B. Paraneoplastic pemphigus. *J Dermatol* 2007; 34:503. [PMID: 17683379].