

# UC Davis

## Dermatology Online Journal

### Title

A case of disseminated superficial porokeratosis in a patient with chronic graft-versus-host disease

### Permalink

<https://escholarship.org/uc/item/8s8156r7>

### Journal

Dermatology Online Journal, 26(10)

### Author

Irie, Kinuko

### Publication Date

2020

### DOI

10.5070/D32610050475

### Copyright Information

Copyright 2020 by the author(s). This work is made available under the terms of a Creative Commons Attribution-NonCommercial-NoDerivatives License, available at <https://creativecommons.org/licenses/by-nc-nd/4.0/>

Peer reviewed

# A case of disseminated superficial porokeratosis in a patient with chronic graft-versus-host disease

Kinuko Irie, Toshiyuki Yamamoto

Affiliations: Department of Dermatology, Fukushima Medical University, Fukushima, Japan

Corresponding Author: Kinuko Irie, Department of Dermatology, Fukushima Medical University, Fukushima 960-1295, Japan, Tel: 81-245471309, Fax: 81-245485412, Email: [kinuko07@fmu.ac.jp](mailto:kinuko07@fmu.ac.jp)

*Keywords: graft-versus-host disease, GvHD, porokeratosis, immunosuppression*

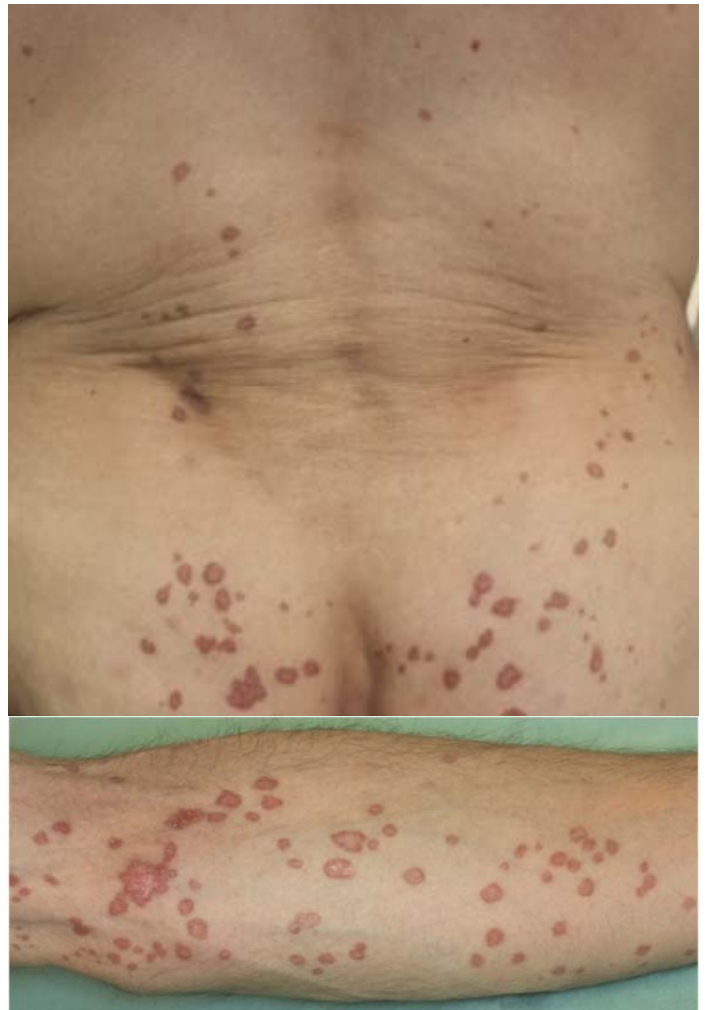
To the Editor:

Immunosuppressive state, trauma, infections, gene mutation, radiation/ultraviolet exposure, and internal malignancy reported factors related to porokeratosis. We report porokeratosis associated with chronic GvHD, along with the relevant literature.

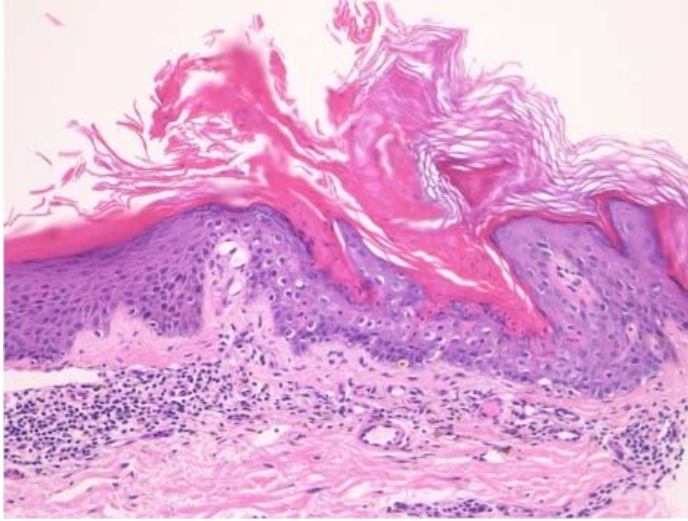
A 50-year-old man had a history of myelodysplastic syndrome and received an allogeneic hematopoietic stem cell transplantation from his younger brother 17 years prior to presentation. Thereafter, the patient suffered from chronic graft-versus-host disease (GvHD) manifesting as skin sclerosis of the lower extremities despite treatment with tacrolimus. Topical psoralen and ultraviolet therapy (PUVA) therapy was utilized for about two years approximately 8 years prior to the onset of disseminated porokeratosis. During the time he developed porokeratosis he was being treated with oral prednisolone (8mg/day).

Physical examination showed a number of red or brown keratotic plaques on the arms, buttocks, and lower extremities. The eruptions were well-circumscribed, round or oval plaques with a diameter of 5-20mm. They had slightly elevated rims (**Figure 1**). A skin biopsy taken from one of the plaques on the arms revealed hyperkeratosis and a narrow stack of parakeratotic corneocytes (cornoid lamella), (**Figure 2**) confirming the diagnosis of disseminated superficial porokeratosis. Neither

topical corticosteroid nor vitamin D3 ointment was effective. Subsequently, oral etretinate (Tigason®) was administered at a dose of 40mg/day, which resulted in partial improvement of existing keratoses and cessation of the development of new lesions.



**Figure 1.** Red or brown keratotic papules with elevated rims on **A)** the buttocks, and **B)** upper arm.



**Figure 2.** Histological features showing hyperkeratosis and cornoid lamella. H&E, 200x.

Our patient and his donor, the patient's brother, do not have family histories of disseminated superficial porokeratosis. He was not infected with hepatitis C virus (HCV).

There are many skin diseases that are associated with chronic GvHD including skin sclerosis, lichen planus, hyperpigmentation, alopecia, and poikiloderma. Our patient developed skin sclerosis of the lower extremities and thereafter developed an eruptive onset of porokeratosis. Kanitakis J et al. reported 63 patients with various clinical forms of porokeratosis occurring after organ transplantation including 45 kidney, 9 heart, 5 bone marrow, three lung, and one liver graft recipients [1], suggesting that more cases

were related to renal transplantation (71%). Cases developing after bone marrow transplantation were few (8%) in that study. The incidence of post-transplant porokeratosis was reported to vary from 0.34 to 3.4% [1]. There are a few reports of multiple porokeratosis, either disseminated or of eruptive onset, in association with GvHD after autologous [2] or allogeneic [3,4] bone marrow transplant. The duration between transplantation and onset of porokeratosis ranged from 2 to 5 years [2-4].

Immunosuppressive state, trauma, infections, gene mutation, radiation/ultraviolet exposure, and internal malignancy are known as inducing factors of porokeratosis [5,6]. In addition, previous studies suggested that HCV may act as a trigger for the development of porokeratosis in patients with immunosuppression and autoimmune diseases [7]. The present patient did not have HCV infection; however, he had been treated with prednisolone, tacrolimus, and PUVA for substantial periods of time.

Immunosuppression, immunosuppressant therapy, and phototherapy could be related to the onset of porokeratosis in the present case. Eruptive porokeratosis is a rare skin condition associated with chronic GvHD.

## Potential conflicts of interest

The authors declare no conflicts of interests.

## References

1. Kanitakis J, Euvrard S, Claudy A. Porokeratosis in organ transplant recipients. *J Am Acad Dermatol.* 2001;44:144-146. [PMID: 11148496]
2. Bernard R, Campos M, A. Le Tourneau, et al. Disseminated superficial porokeratosis after autologous bone marrow transplantation. *Bone Marrow Transplant.* 1997;19:77-79. [PMID: 9012935].
3. Cha SH, Park HJ, Lee JY, Cho BK, Atypical porokeratosis developing following bone marrow transplantation in a patient with myelodysplastic syndrome. *Ann Dermatol.* 2010;22:206-208. [PMID: 20548916].
4. Marks E, Dorokhova O, Amin B, Jacobson M. Eruptive angiokeratomas and porokeratosis in the setting of sclerodermatous graft-vs.-host disease. *J Cutan Pathol.* 2016;43:516-519. [PMID: 26957361].
5. Kanitakis J. Porokeratoses: an update of clinical, aetiopathogenic and therapeutic features. *Eur J Dermatol.* 2014;24:533-544. [PMID: 25115203].
6. Kanitakis J, Euvrard S, Faure M, Claudy A. Porokeratosis and immunosuppression. *Eur J Dermatol.* 1998;8:459-465. [PMID: 9854155].
7. Mizukawa Y, Shiohara T. Porokeratosis in patients with hepatitis C virus infection: does HCV infection provide a link between porokeratosis and immunosuppression? *Br J Dermatol.* 1999;14:163-164. [PMID: 10417540].