

# UC Davis

## Dermatology Online Journal

### Title

Eosinophilic dermatosis of hematologic malignancy

### Permalink

<https://escholarship.org/uc/item/8467m0j9>

### Journal

Dermatology Online Journal, 22(12)

### Authors

Martires, Kathryn  
Callahan, Shields  
Terushkin, Vitaly  
[et al.](#)

### Publication Date

2016

### DOI

10.5070/D32212033398

### Copyright Information

Copyright 2016 by the author(s). This work is made available under the terms of a Creative Commons Attribution-NonCommercial-NoDerivatives License, available at <https://creativecommons.org/licenses/by-nc-nd/4.0/>

Peer reviewed

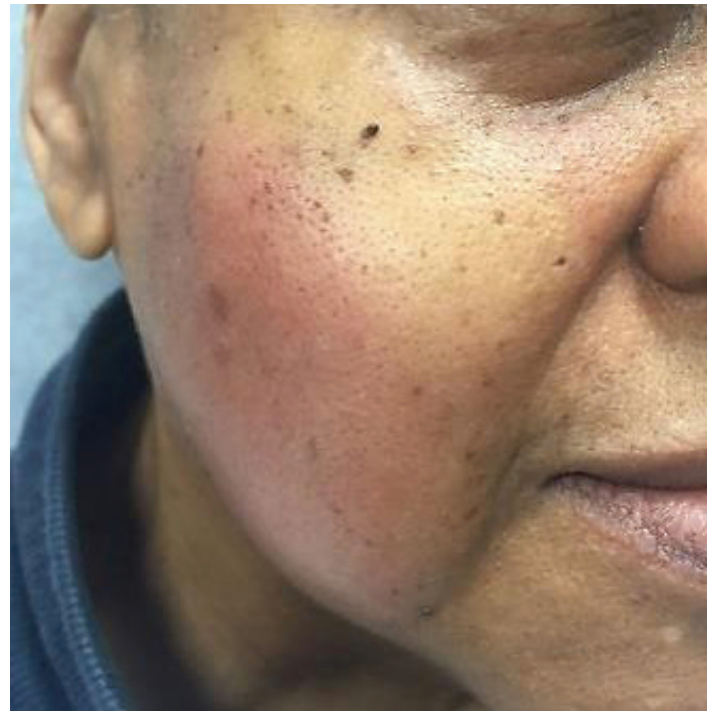# Eosinophilic dermatosis of hematologic malignancy

Kathryn Martires, MD, Shields Callahan, MD, Vitaly Terushkin, MD, Nooshin Brinster MD, Marie Leger, MD, PhD, Nicholas A. Soter, MD

Ronald O. Perelman Department of Dermatology, NYU School of Medicine, NYU Langone Medical Center

## Abstract

We report a 68-year-old woman with chronic lymphocytic leukemia, who developed numerous, pruritic, edematous, and vesicobullous skin lesions of the face and extremities over the course of several months. The diagnosis of eosinophilic dermatosis of hematologic malignancy (EDHM) was made based on the clinical history and histopathologic features. Owing to the possible link between EDHM and a more aggressive underlying CLL, she was started again on chemotherapy. This case serves as a reminder that, although the precise pathogenesis of EDHM remains unclear, the paraneoplastic disorder is the result of immune dysregulation. Patients who develop EDHM should undergo prompt hematologic/oncologic evaluation.



**Figure 1.** Right cheek with extensive dermal edema and erythema.

## Case Presentation

**PATIENT:** 68-year-old woman

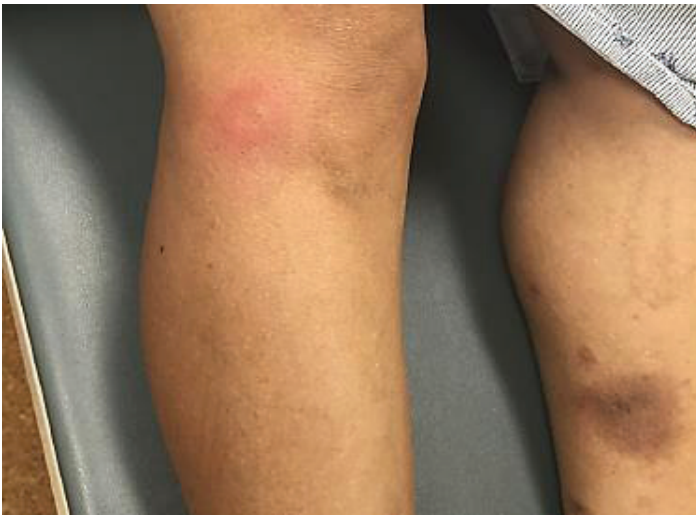
**DURATION:** Five months

**DISTRIBUTION:** Face and extremities

**HISTORY:** A 68-year-old woman presented to the Skin and Cancer Unit for a five-month history of intermittent, vesiculobullous skin lesions of her face and extremities. The patient had experienced approximately nine episodes over the five-month period of pruritic, edematous, and bullous lesions that resolved within one week. Previous treatments included methylprednisolone, prednisone, and high-potency topical glucocorticoids. Although these treatments increased the rate of resolution for the individual lesions, she continued to develop

new lesions. She denied any new topical products or medications. She denied affected contacts, travel, outdoor hobbies, and pets. She denied any systemic complaints, which included fevers, chills, night sweats, and weight loss.

Past medical history included breast cancer, diabetes mellitus, and chronic lymphocytic leukemia (CLL) for which she was treated with rituximab in 2011 and with rituximab and bendamustin in 2013 for tonsillar involvement secondary to the CLL. She was followed regularly by an oncologist, and, at presentation, her disease was considered in remission. Two punch biopsies were obtained from the lateral aspect of the right knee.



**Figure 2.** 5 cm edematous, erythematous nodule with central 2 mm vesicle on the lateral aspect of the right knee

**PHYSICAL EXAMINATION:** Extensive dermal edema and erythema of the entire right cheek were noted (**Figure 1**). On the lateral aspect of the right knee, there was 5-cm, edematous, erythematous nodule with a central 2-mm vesicle (**Figure 2**). In addition to these two active lesions, numerous, hyperpigmented patches were present on the extremities at sites of previous lesions.

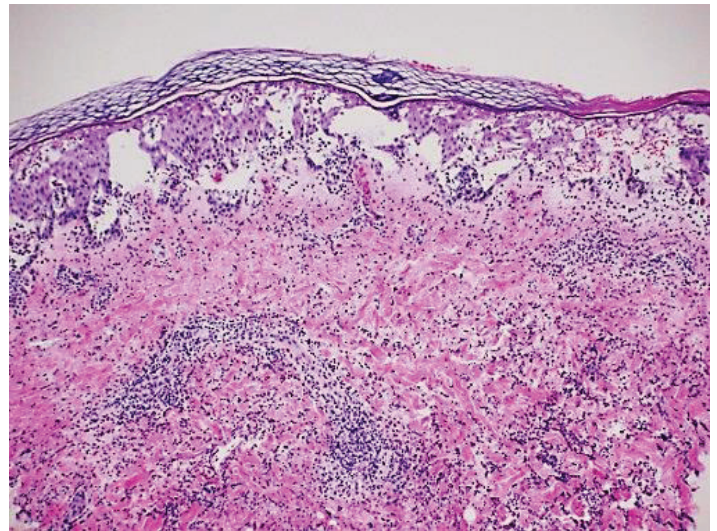
**LABORATORY DATA:** Positron emission tomography computed tomography (PET-CT) showed no evidence of transformation to a high-grade lymphoma.

**HISTOPATHOLOGY:** There is marked epidermal spongiosis and vesiculation that is associated with a superficial and deep, perivascular and interstitial, mixed infiltrate of eosinophils, neutrophils, and lymphocytes. Numerous eosinophils are present within the epidermis (**Figure 3**).

**DIAGNOSIS:** Eosinophilic dermatosis of hematologic malignancy

## Discussion

Eosinophilic dermatosis of hematologic malignancy (EDHM) is an uncommon paraneoplastic process that arises in patients with an underlying hematologic malignant condition, most commonly CLL. It was first described in 1965 by Weed, who reported eight patients with CLL, who demonstrated



**Figure 3.** Biopsy showing marked epidermal spongiosis and vesiculation associated with a superficial and deep, perivascular and interstitial, mixed infiltrate of eosinophils, neutrophils and lymphocytes. Numerous eosinophils are present within the dermis.

an exaggerated delayed hypersensitivity to mosquito bites [1]. He differentiated this cutaneous eruption from leukemia cutis based on the spontaneous resolution of the lesions as well as on the appreciable eosinophilia that was observed on histopathologic examination [1].

Today, EDHM is recognized as a rare, eosinophilic cutaneous reaction pattern that arises in the setting of hematologic malignant conditions. In addition to CLL, it has been described in mantle-cell lymphoma, large-cell lymphoma, myelofibrosis, and CLL [2]. The lesions most commonly arise in patients with a known lymphoma or leukemia; however, they may precede the diagnosis of the malignant condition in rare cases [2].

On histopathologic examination, EDHM shows a superficial and deep, dense, perivascular infiltrate of eosinophils and lymphocytes. Intraepidermal and subepidermal edema may result in vesicles and bullae [2]. Flame figures also may be noted [3].

Although the clinical features and histopathologic features of EDHM are indistinguishable from an exuberant arthropod bite reaction, most patients deny any exposures to insects, and, therefore, the term insect bite-like reaction is the preferred nomenclature [4]. There is controversy regarding whether this represents an aberrant immune response to an insect bite or a truly *de novo*

cutaneous eruption. Most lesions arise on exposed body sites, such as the extremities and face, as occurred in our patient, which raises the possibility of an arthropod bite assault in this case.

The pathogenesis of EDHM is unknown; however, an excess of eosinophil-promoting chemokines, particularly IL-3, IL-4, and IL-5, are postulated to play a role [3]. Studies have demonstrated that eosinophils obtained from lesional skin in patients with EDHM have an increased survival [3]. IL-5, which is the major eosinophil-recruiting cytokine, likely plays an important role in the pathogenesis. Eosinophilic folliculitis in patients with human immunodeficiency virus (HIV) may represent an analogous response, whereby an insect bite reaction sets off an aberrant response in the setting of a dysregulated immune system [5].

There is no specific treatment for EDHM. Numerous treatment modalities have been used, which include topical and systemic glucocorticoids, but the results often are disappointing [2]. EDHM may be associated with a more aggressive form of CLL [2]. Therefore, careful monitoring and aggressive management of the underlying hematologic malignant condition is warranted. The decision was made with our patient, along with her oncology team, to start again rituximab infusions. She is currently undergoing treatment and what, if any, skin improvement she experiences remains to be seen.

## References

1. Weed R. Exaggerated delayed hypersensitivity to mosquito bites in chronic lymphocytic leukemia. *Blood* 1965;26:257
2. Farber MJ, et al. Eosinophilic dermatosis of hematologic malignancy. *J Cutan Pathol* 2012;39:690
3. Davis MD, et al. Exaggerated arthropod-bite lesions in patients with chronic lymphocytic leukemia: a clinical, histopathologic, and immunopathologic study of eight patients. *J Am Acad Dermatol* 1998;39:27
4. Barzilai A, et al. Insect bite-like reaction in patients with hematologic malignant neoplasms. *Arch Dermatol* 1999;135:1503
5. Sundharam JA. Pruritic skin eruption in the acquired immunodeficiency syndrome: arthropod bites? *Arch Dermatol* 1990;126:539