

UC Davis

Dermatology Online Journal

Title

Metastatic calcinosis cutis in a patient with Hodgkin's lymphoma

Permalink

<https://escholarship.org/uc/item/7z73b3kk>

Journal

Dermatology Online Journal, 24(11)

Authors

Dennin, Margaret H
Dulmage, Brittany O
Yazdan, Pedram
et al.

Publication Date

2018

DOI

10.5070/D32411042005

Copyright Information

Copyright 2018 by the author(s). This work is made available under the terms of a Creative Commons Attribution-NonCommercial-NoDerivatives License, available at <https://creativecommons.org/licenses/by-nc-nd/4.0/>

Peer reviewed

Metastatic calcinosis cutis in a patient with Hodgkin's lymphoma

Margaret H Dennin¹ BS, Brittany O Dulmage² MD, Pedram Yazdan² MD, Emily Keimig² MD

Affiliations: ¹University of Chicago, Pritzker School of Medicine, Chicago, Illinois, USA, ²Northwestern University, Department of Dermatology, Chicago, Illinois, USA

Corresponding Author: Emily Keimig MD, Northwestern University, Department of Dermatology, 676 North St. Clair, Suite 1600, Chicago, IL 60611, Tel: 312-695-8106, Email: Emily.Keimig@nm.org

Abstract

Calcinosis cutis results from the deposition of insoluble calcium salts in the skin and subcutaneous tissue. Herein, we report a case of extensive metastatic calcinosis cutis in an 18-year-old woman with stage IV Hodgkin lymphoma with skeletal involvement. With combination therapy including radiation directed at her lymphoma and diltiazem, her lesions improved dramatically. This case demonstrates the previously unreported association between calcinosis cutis and Hodgkin lymphoma.

Keywords: calcinosis cutis, Hodgkin lymphoma, radiation

Introduction

Calcinosis cutis is caused by aberrant calcium deposition in the skin that is classified as dystrophic, metastatic, idiopathic, or iatrogenic. Metastatic calcinosis cutis is related to abnormal calcium and/or phosphorus metabolism that precipitates the deposition of calcium salts in normal skin. Hypercalcemia may occur as a complication of hematological malignancies resulting in calcinosis of the skin or other organs. Although hypercalcemia is seen in 5% of Hodgkin lymphoma cases, calcinosis cutis in the setting of Hodgkin lymphoma has not been reported [1]. Herein we report the case of a young adult presenting with hypercalcemia and metastatic calcinosis cutis in the setting of Hodgkin lymphoma.

Case Synopsis

An 18-year-old woman presented to the dermatology clinic for evaluation of painful axillary lesions. Five months prior, the patient was diagnosed with stage IVB classical Hodgkin lymphoma of multiple sites, including skeletal involvement. She completed four months of chemotherapy (doxorubicin, bleomycin, vincristine, etoposide, prednisone, cyclophosphamide) and was due to start radiation targeting the anterior half of her body. Three months prior to presentation she developed dilated cardiomyopathy and was hospitalized for acute kidney injury (AKI) requiring continuous renal replacement therapy in the setting of fluid overload.

Two to three months prior to presentation to our clinic she began experiencing extremely painful bumps in the axilla, elbows, knees, and buttocks. The

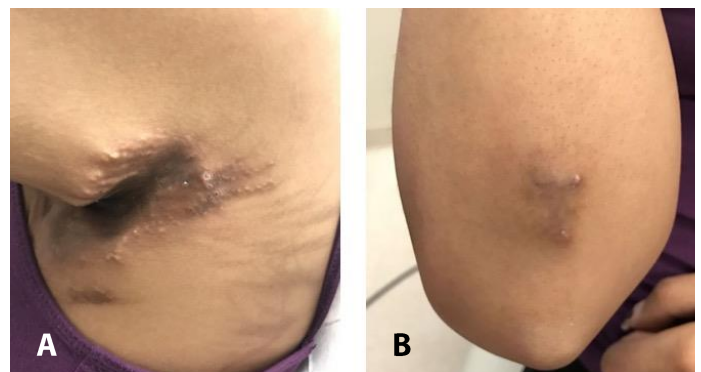


Figure 1. Clinical findings. **A)** Left axillae demonstrating rock-hard indurated plaque with rim of comedo-like openings. **B)** Right elbow demonstrating small hyperpigmented hard plaque with focal hard papules.

axillary lesions were the most problematic limiting her ability to raise her arms. She reported no drainage.

Examination revealed bilateral axillae with rock-hard indurated plaques with peripheral comedo-like openings measuring 10×4cm (right) and 12×5cm (left). The bilateral extensor elbows had smaller hyperpigmented hard plaques with focal hard papules. The buttocks had scattered hyperpigmented firm papules. The trunk was notable for flagellate hyperpigmented patches (**Figure 1**). Range of motion of the bilateral shoulders was limited, with the right shoulder able to elevate to 70 degrees and the left to 80 degrees.

The differential diagnosis included calcinosis cutis, other deposition or perforating disorders with secondary calcification, and much less likely, lymphoma cutis. Two 4mm skin punch biopsies of lesions on the right elbow and buttock were performed. Both biopsies demonstrated deposits of amorphous basophilic aggregates in the dermis. A Von Kossa stain highlighted these aggregates, confirming calcium deposition (**Figure 2**). CT scan showed extensive calcification of the axillary subcutaneous soft tissue. Additionally, imaging demonstrated calcifications along the internal iliac

and femoral vessels much more advanced than expected given the patient's young age. These clinical and histopathologic findings were consistent with a diagnosis of calcinosis cutis.

Extensive laboratory investigation initiated by the endocrinology consultant showed elevated serum phosphorus of 6.1 mg/dL (normal= 3.9-4.6 mg/dL) and elevated ionized calcium of 1.6mM (normal= 1.08-1.34mM). Normal laboratory tests included parathyroid hormone-related protein (PTHrP), urine phosphorus, urine calcium, total serum calcium, parathyroid hormone (PTH), creatinine, and 25-hydroxyvitamin D₃.

The patient was started on diltiazem 180mg daily. A plastic surgery consultation was requested for potential surgical management of the lesions. The plastic surgeon recommended surgery of one extremity at a time with plans for wide local excision and primary closure of the smaller elbow lesions and excision with subsequent skin grafting or a local flap for the larger axillary lesions. Prior to planned surgical intervention, she underwent radiation therapy of 21Gy divided in 14 doses to the liver and mantle field, which included lymph node areas in the neck, chest, and axilla. Remarkably, after three months on diltiazem and completion of radiation

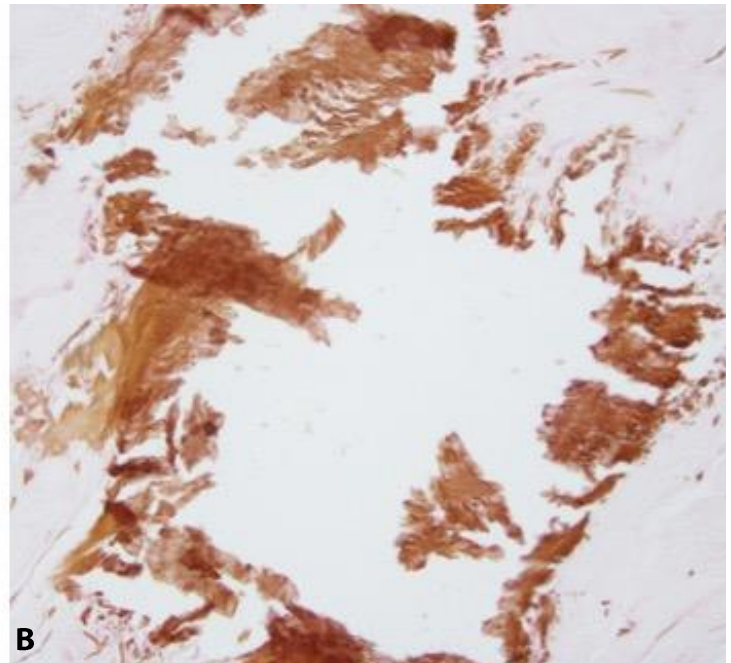
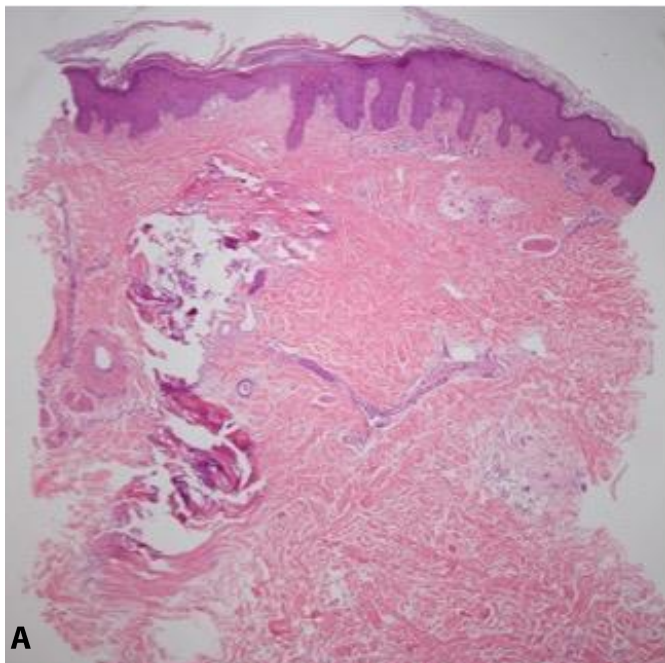


Figure 2. Histopathologic examination. **A)** Hematoxylin and eosin stain of elbow site biopsy shows epidermal acanthosis, amorphous basophilic material in the dermis, a mild inflammatory reaction, and calcium deposits. **B)** Von Kossa stain highlights dermal calcium.

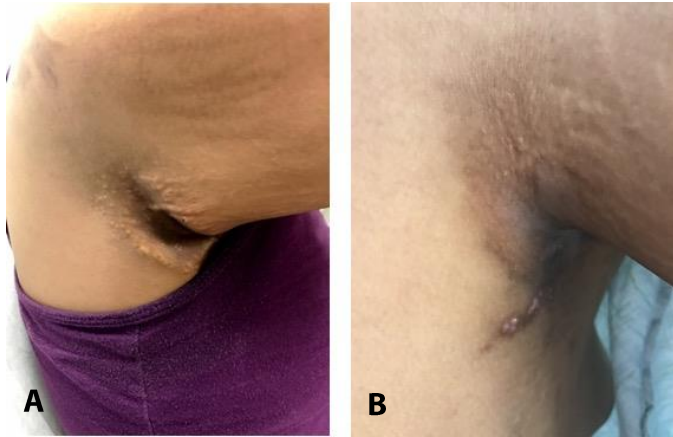


Figure 3. Treatment response. A) Right axilla prior to treatment demonstrating an indurated plaque. B) After radiation therapy and treatment with diltiazem she demonstrated near complete resolution of the plaque with post-inflammatory hyperpigmentation.

therapy, her calcinosis cutis lesions had decreased appreciably leaving only a few small papules in the bilateral axillae allowing return of full range of motion of the upper extremities and little ongoing pain (**Figure 3**). She continued diltiazem and resumed chemotherapy.

Case Discussion

The four subtypes of calcinosis cutis include dystrophic, idiopathic, iatrogenic, and metastatic. Dystrophic calcinosis cutis is the most common and results from deposition of insoluble calcium salts in previously damaged tissue with normal systemic calcium metabolism. The idiopathic subtype occurs most commonly in childhood or adolescence in the absence of tissue damage with normal calcium and phosphorus levels [2]. Iatrogenic calcinosis cutis occurs following treatment with intravenous calcium or inorganic phosphate, tumor lysis syndrome, or long-term application of calcium containing gels. Tumor lysis syndrome leads to hyperphosphatemia, hyperuricemia, hyperkalemia, and secondary hypocalcemia owing to the rapid release of potassium and phosphorus [3].

Metastatic calcinosis cutis (MCC) occurs in the setting of abnormal calcium and phosphate metabolism leading to hypercalcemia and/or hyperphosphatemia. Cutaneous involvement results most commonly in nodular calcifications in a

periarticular distribution [2]. Calcification in these cases may be widespread and affect not only the cutaneous and subcutaneous tissues, but also blood vessels, muscles, and internal organs [4]. Underlying defects in MCC include chronic renal failure, hypervitaminosis D, milk-alkali syndrome, and diseases with bony destruction, including Paget disease, lymphomas, leukemias, multiple myeloma, and metastatic carcinoma [5].

Hypercalcemia is a frequent complication of malignancies. Responsible mechanisms include increased bone resorption by skeletal involvement or factors produced by tumors such as PTHrP, osteoclast-activating factor, and ectopic calcitriol production [6]. Hypercalcemia is rarely seen in patients with Hodgkin lymphoma and most cases are related to ectopic 1-alpha-hydroxylation of 25-hydroxyvitamin D causing elevated calcitriol [7]. There have been reports of lymph node calcification and calciphylaxis in Hodgkin lymphoma but no reports of calcinosis cutis [8, 9].

The etiology of calcinosis cutis in this patient with Hodgkin lymphoma is likely multifactorial. Her calcinosis cutis is primarily metastatic driven by inappropriate calcium metabolism in the setting of osteolytic skeletal metastases. Additionally, she was hospitalized for AKI requiring continuous renal replacement therapy after which her calcinosis cutis lesions became symptomatic. This suggests that her hypercalcemia may have acutely worsened in the setting of AKI and contributed to worsening calcinosis cutis. Additionally, tumor lysis syndrome in the setting of chemotherapy may have been an additional driver of calcium dysregulation. Of note, her laboratory tests demonstrated no evidence of hyperparathyroidism, pseudohyperparathyroidism, or ectopic calcitriol production.

Treatment for calcinosis cutis is not standardized given the rarity and heterogeneity of the syndrome. Treatments are based on case reports and small case series as clinical trials are lacking. Localized lesions can be treated surgically with curettage, surgical excision, and carbon dioxide lasers, or medically with warfarin, ceftriaxone, and intravenous immunoglobulin. More extensive lesions may be

treated successfully with probenecid, diltiazem, aluminum hydroxide, and bisphosphonates [10].

Our patient's clinical response after radiation therapy and medical treatment with diltiazem was significant. Although this is only an anecdotal report of calcinosis cutis treatment in the setting of a hematologic malignancy, it does suggest that further studies of combination therapy aimed at treating both the cancer and correcting calcium metabolism are warranted.

References

1. Burt ME, Brennan MF. Incidence of hypercalcemia and malignant neoplasm. *Archives of surgery* (Chicago, Ill: 1960). 1980;115(6):704-7. [PMID: 7387355].
2. Reiter N, El-Shabrawi L, Leinweber B, Berghold A, Aberer E. Calcinosis cutis: part I. Diagnostic pathway. *Journal of the American Academy of Dermatology*. 2011;65(1):1-12; quiz 3-4. [PMID: 21679810].
3. Gulen H, Kazanci E, Ozek DG, Erbay A, Yamaci S, Aktas S, Vergin C. Calcinosis cutis in a pediatric patient with Burkitt's lymphoma. *Turkish journal of haematology: official journal of Turkish Society of Haematology*. 2005;22(3):151-4. [PMID: 27264837].
4. Castanedo-Cazares JP, Reyes-Herrera A, Hernandez-Blanco D, Oros-Ovalle C, Torres-Alvarez B. Metastatic Calcinosis Cutis: A Case in a Child with Acute Pre-B Cell Lymphoblastic Leukemia. *Case reports in hematology*. 2015;2015:384821. [PMID: 26346120].
5. Walsh JS, Fairley JA. Calcifying disorders of the skin. *Journal of the American Academy of Dermatology*. 1995;33(5 Pt 1):693-706; quiz 7-10. [PMID: 7593766].
6. Lestringant GG, Masouye I, El-Hayek M, Girardet C, Revesz T, Frossard PM. Diffuse calcinosis cutis in a patient with congenital leukemia and leukemia cutis. *Dermatology* (Basel, Switzerland). 2000;200(2):147-50. [PMID: 10773706].
7. Brizendine K, Wells JM, Flanders SA, Saint S, Centor RM. Clinical problem-solving. In search of. *The New England journal of medicine*. 2010;363(23):2249-54. [PMID: 21121838].
8. Aksoy S, Kilickap S, Abali H, Erman M. Calcified lymph nodes in Hodgkin's lymphoma. *Leukemia & lymphoma*. 2006;47(5):952-4. [PMID: 16753891].
9. Sibai H, Ishak RS, Halawi R, Otroock ZK, Salman S, Abu-Alfa A, Kharfan-Dabaja MA. Non-uremic calcific arteriopathy (calciophylaxis) in relapsed/refractory Hodgkin's lymphoma: a previously unreported association. *Journal of clinical oncology: official journal of the American Society of Clinical Oncology*. 2012;30(7):e88-90. [PMID: 22231039].
10. Reiter N, El-Shabrawi L, Leinweber B, Berghold A, Aberer E. Calcinosis cutis: part II. Treatment options. *Journal of the American Academy of Dermatology*. 2011;65(1):15-22; quiz 3-4. [PMID: 21679811].

Conclusion

To our knowledge, this case is the first report of calcinosis cutis presenting in a patient with Hodgkin lymphoma. This case will increase awareness amongst dermatologists and other physicians caring for patients with hematologic malignancy that firm papules may be calcinosis cutis. Further, this case highlights the often multifactorial etiology of calcinosis and a successful combination and multi-discipline treatment approach.