

UC Davis

Dermatology Online Journal

Title

Gyrate erythema in the setting of tinea pedis

Permalink

<https://escholarship.org/uc/item/7b45z8z9>

Journal

Dermatology Online Journal, 22(12)

Authors

Myers, Kathryn
Terushkin, Vitaly
Meehan, Shane A
et al.

Publication Date

2016

DOI

10.5070/D32212033382

Copyright Information

Copyright 2016 by the author(s). This work is made available under the terms of a Creative Commons Attribution-NonCommercial-NoDerivatives License, available at <https://creativecommons.org/licenses/by-nc-nd/4.0/>

Peer reviewed

Gyrate erythema in the setting of tinea pedis

Kathryn Myers, MD, Vitaly Terushkin, MD, Shane A. Meehan, MD, and David E. Cohen, MD MPH

Ronald O. Perelman Department of Dermatology, NYU School of Medicine, NYU Langone Medical Center

Abstract

Gyrate erythema, which also is known as erythema annulare centrifugum (EAC), is a reactive dermatitis that is thought to occur in response to an underlying trigger. The superficial form is characterized by the typical, centrifugally-expanding, annular, erythematous patches or plaques with a distinct trailing scale. The deep form also is a centrifugally-expanding, erythematous plaque but with indurated borders and absence of scale. These cutaneous findings are thought to be reactive, most often in response to infections or drugs and, less likely, to underlying malignant conditions.

Case Presentation

PATIENT: 53-year-old-man

DURATION: Fourteen months

DISTRIBUTION: Abdomen, flanks, lower back, and feet

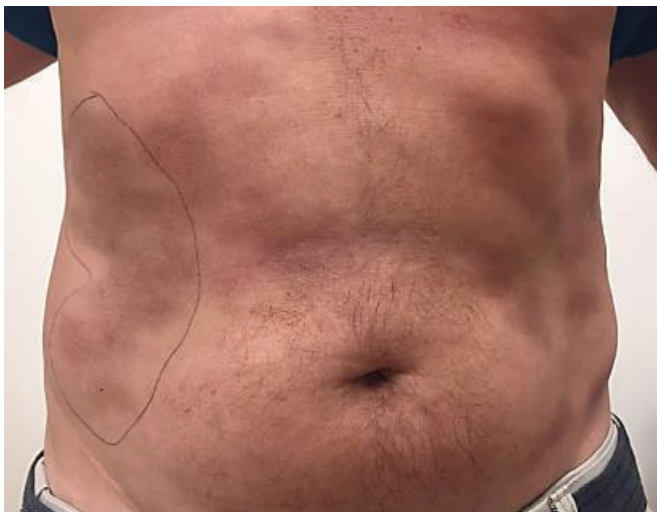

Figure 1. On the abdomen, flanks, and lower back, there were many, ill-defined, coalescing, erythematous-to-hyperpigmented, atrophic plaques, with overlying epidermal wrinkling and slight induration at the periphery

HISTORY: A 53-year-old man was referred to the Skin and Cancer Unit for evaluation of an eruption on the abdomen and back. The patient first noticed the eruption in the summer of 2014. He denied associated symptoms, which included pruritus. He had been evaluated previously by two dermatologists and underwent two biopsies that showed a perivascular and interstitial dermatitis with eosinophils. He was treated with topical glucocorticoids without improvement. He continued to develop new lesions. Patch tests by a previous dermatologist showed positive reactions to p-phenylenediamine, nickel, isothiazolinone, and imidazolidinyl urea. There was no change in his eruption with avoidance of these allergens over several months. The clinical morphology of the lesions with hyperpigmentation, subtle atrophy, and epidermal wrinkling raised concern for possible morphea, specifically atrophoderma of Pasini and Pierini versus less likely mycosis fungoides. Two additional broad shave biopsies were obtained.

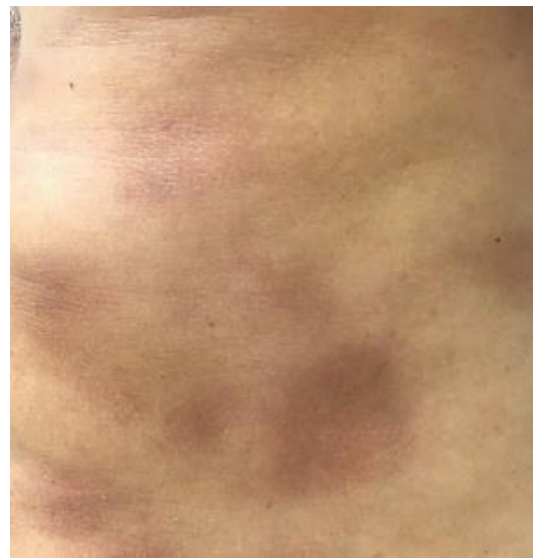

Figure 2. Ill-defined, coalescing, erythematous-to-hyperpigmented, atrophic plaques, with overlying epidermal wrinkling and slight induration at the periphery

Patch tests with the North American Standard Series showed positive reaction to nickel only. The patient was up-to-date with age-appropriate cancer screenings, and a comprehensive review of systems was negative.

PHYSICAL EXAMINATION: On the abdomen, flanks, and lower back, there were many, ill-defined, coalescing, erythematous-to-hyperpigmented, atrophic plaques, with overlying epidermal wrinkling and slight induration at the periphery (**Figures 1 and 2**). On the plantar surfaces, there was serpiginous scale along with interdigital maceration between the third and fourth toes and the fourth and fifth toes.

LABORATORY DATA: Anti-nuclear antibody and Lyme western blot panel were negative.

HISTOPATHOLOGY: There is a superficial and mid-perivascular, tightly-cuffed lymphocytic infiltrate with scattered eosinophils (**Figure 3**).

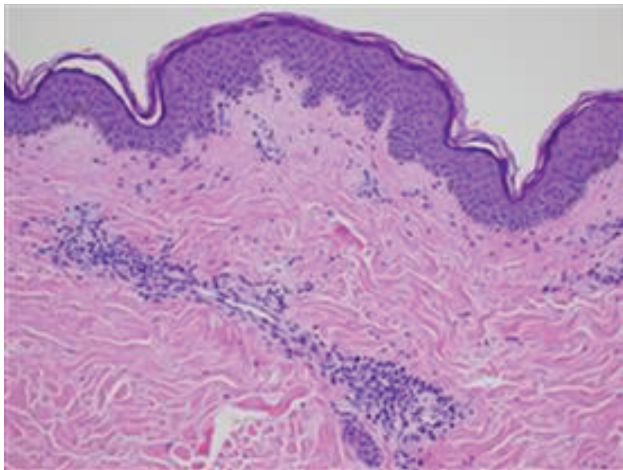


Figure 3. Superficial and mid-perivascular, tightly-cuffed lymphocytic infiltrate with scattered eosinophils.

DIAGNOSIS: Gyrate erythema in the setting of tinea pedis.

Discussion

Gyrate erythema refers to a group of cutaneous findings of annular or cyclic erythematous patches or plaques. The term erythema annulare centrifugum (EAC) is synonymous with superficial

gyrate erythema, deep gyrate erythema, and erythema perstans although clinical appearances vary. Superficial lesions are characterized by centrifugally expanding annular erythema with a trailing edge of scale while deeper lesions often have an infiltrated border without scale [1]. This condition was first described in 1891 and later named erythema annulare centrifugum by Darier in 1916 [2]. Gyrate erythema was further classified as superficial and deep by Ackerman in 1978 [3].

Gyrate erythema is a reactive, cutaneous condition that is thought to occur in response to an underlying trigger. Many triggering factors have been reported in the literature and include infections, medications, and, less likely, malignant conditions. The differential diagnosis of deep gyrate erythema includes erythema chronicum migrans, annular urticaria, granuloma annulare, sarcoidosis, and secondary syphilis. Superficial gyrate erythema may be confused with dermatophytosis and subacute cutaneous lupus erythematosus [4].

A few, small reviews of patients with EAC have shown similar results. The sites most commonly affected are the trunk and the lower extremities. The duration of the eruption ranged from one to three years on average. There are reports of concomitant dermatophyte or other cutaneous infections, medication exposures, and malignant conditions [5,6,7]. Many cases are idiopathic.

The salient histopathologic features of gyrate erythema include a superficial and mid-dermal, perivascular, lymphohistiocytic dermatitis with coat-sleeving or cuffing of the infiltrate around the blood vessels. Superficial forms may show focal epidermal spongiosis and parakeratosis [2, 8].

Gyrate erythema often is self-limited. Elimination or treatment of a potential underlying trigger may result in resolution of the cutaneous eruption. There are reports of successful treatment of gyrate erythema with erythromycin, metronidazole, dapsone, etanercept, calcipotriene, and narrow-band ultraviolet B phototherapy [9-14].

Superficial lesions are characterized by centrifugally expanding annular erythema with a trailing edge of

scale while deeper lesions often have an infiltrated border without scale [1]. This condition was first described in 1891 and later named erythema annulare centrifugum by Darier in 1916 [2] Gyrate erythema was further classified as superficial and deep by Ackerman in 1978 [3].

Gyrate erythema is a reactive, cutaneous condition that is thought to occur in response to an underlying trigger. Many triggering factors have been reported in the literature and include infections, medications, and, less likely, malignant conditions. The differential diagnosis of deep gyrate erythema includes erythema chronicum migrans, annular urticaria, granuloma annulare, sarcoidosis, and secondary syphilis. Superficial gyrate erythema may be confused with dermatophytosis and subacute cutaneous lupus erythematosus [4].

A few, small reviews of patients with EAC have shown similar results. The sites most commonly affected are the trunk and the lower extremities. The duration of the eruption ranged from one to three years on average. There are reports of concomitant dermatophyte or other cutaneous infections, medication exposures, and malignant conditions [5, 6, 7]. Many cases are idiopathic.

The salient histopathologic features of gyrate erythema include a superficial and mid-dermal, perivascular, lymphohistiocytic dermatitis with coat-sleeving or cuffing of the infiltrate around the blood vessels. Superficial forms may show focal epidermal spongiosis and parakeratosis [2, 8].

Gyrate erythema often is self-limited. Elimination or treatment of a potential underlying trigger may result in resolution of the cutaneous eruption. There are reports of successful treatment of gyrate erythema with erythromycin, metronidazole, dapsone, etanercept, calcipotriene, and narrow-band ultraviolet B phototherapy [9-14].

References

1. Espana A. Figurate Erythemas. In: Bologna JL, et al. eds. *Dermatology* 3rd Ed. London: Mosby. 2012:114
2. Darier J. De l'erytheme annulaire centrifuge. *Ann Dermatol Syph* 1916; 6:57
3. Ackerman AB. *Histologic Diagnosis of Inflammatory Skin Diseases: A Method by Pattern Analysis*. Philadelphia: Lea & Febiger 1978: 283
4. Tyring SK. Reactive erythemas: erythema annulare centrifugum and erythema gyratum repens. *Clin Dermatol* 1993;1:135
5. Manhood JM. Erythema annulare centrifugum: a review of 24 cases with special reference to its association with underlying disease. *Clin Exp Dermatol* 1983;4:383
6. Kim KJ, et al. Clinicopathologic analysis of 66 cases of erythema annulare centrifugum. *J Dermatol* 2002;2:61
7. Weyers W, et al. Erythema annulare centrifugum: results of a clinicopathologic study of 73 patients. *Am J Dermatopathol* 2003;6:451
8. Bressler GS, Jones RE Jr. Erythema annulare centrifugum. *J Am Acad Dermatol* 1981;5:597
9. Chuang FC, et al. Erythromycin as a safe and effective treatment option for erythema annulare centrifugum. *Indian J Dermatol* 2015;5:519
10. De Aloe G, et al. Erythema annulare centrifugum successfully treated with metronidazole. *Clin Exp Dermatol* 2005;5:583
11. Sankar R. Erythema annulae centrifugum responding to dapsone. *Indian J Dermatol* 1995;6:385
12. Minni J, Sarro R. A novel therapeutic approach to erythema annulare centrifugum. *J Am Acad Dermatol* 2006;3:S134
13. Gniadecki R. Calcipotriol for erythema annulare centrifugum. *Br J Dermatol* 2002;2:317
14. Reuter J, et al. Erfolgreiche Therapie mit topischem Calcitriol und UVB-Schmalspektrumbestrahlung. *Hautart* 2007;2:146