

# UC Davis

## Dermatology Online Journal

### Title

Adalimumab-induced psoriatic alopecia/alopecia areata-like reaction in a patient with Crohn's disease

### Permalink

<https://escholarship.org/uc/item/79j1d2jv>

### Journal

Dermatology Online Journal, 21(11)

### Authors

Toda-Brito, H  
Lopes, L  
Soares-Almeida, L  
et al.

### Publication Date

2015

### DOI

10.5070/D32111029286

### Copyright Information

Copyright 2015 by the author(s). This work is made available under the terms of a Creative Commons Attribution-NonCommercial-NoDerivatives License, available at <https://creativecommons.org/licenses/by-nc-nd/4.0/>

Peer reviewed

## Case presentation

### Adalimumab-induced psoriatic alopecia/alopecia areata-like reaction in a patient with Crohn's disease

H Toda-Brito<sup>1</sup>, L Lopes<sup>2</sup>, L Soares-Almeida<sup>2</sup>, P Filipe<sup>2</sup>

Dermatology Online Journal 21 (11): 6

<sup>1</sup>Department of Dermatology, Santarém Hospital, Santarém, Portugal

<sup>2</sup>Department of Dermatology, Santa Maria Hospital, Lisboa, Portugal

#### Correspondence:

Helena Toda Brito  
Serviço de Dermatologia e Venereologia  
Hospital Distrital de Santarém  
Avenida Bernardo Santarém, 2005-177 Santarém, Portugal  
E-mail – helenatoda@gmail.com  
Phone number – +351 964 733 284

---

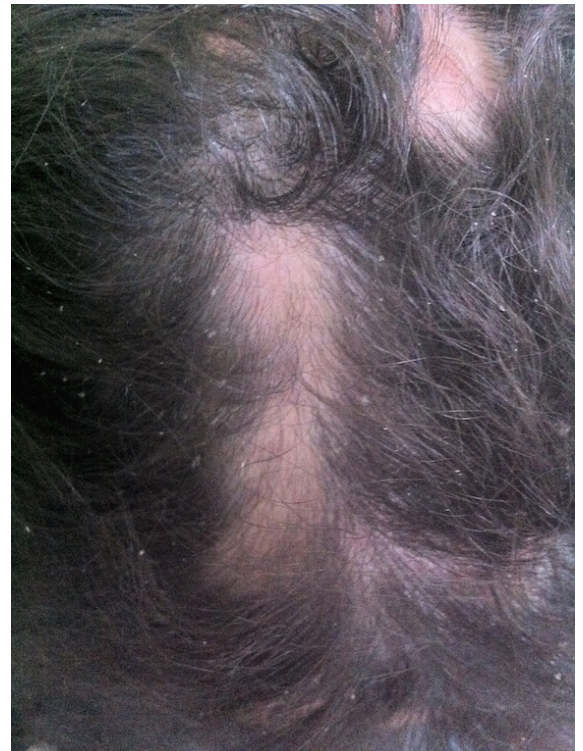## Abstract

Anti-tumor necrosis factor (anti-TNF) agents have been successfully used to treat both chronic idiopathic inflammatory bowel disease and other immune-mediated chronic diseases, but they can also induce a wide array of cutaneous reactions, including new-onset psoriasis and alopecia. We report a case of alopecia associated with psoriasiform skin lesions in a patient on adalimumab treatment for Crohn's disease.

**Keywords:** Adalimumab; Anti-tumor necrosis factor-alpha; Alopecia; Alopecia areata; Psoriasis.

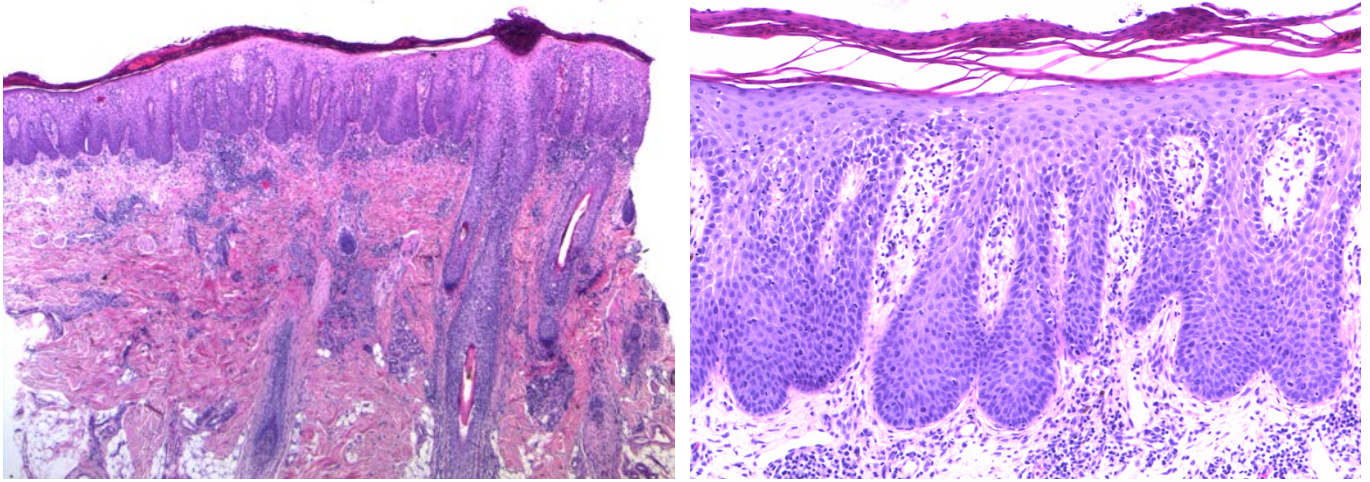
## Case synopsis

A 24-year-old female with a 2-year history of fistulizing Crohn's disease (CD) was started on adalimumab monotherapy (40 mg biweekly) after failing to respond to various therapy regimens, including mesalazine, azathioprine and systemic corticosteroids. Seven months after treatment initiation she developed erythematous patches on the scalp that evolved with exudative discharge and progressive alopecia (Fig. 1). Subsequently several erythematous patches developed on the lower limbs, palms and soles. She denied personal or family history of psoriasis or alopecia. A skin biopsy obtained from the scalp revealed psoriasiform epidermal changes in association with alopecia areata-like changes in the dermis (Figs. 2-4). Periodic Acid-Schiff stain was negative for fungi. As CD was inactive, adalimumab was discontinued and daily treatment was started with topical clobetasol solution and coal tar shampoo. The scalp lesions cleared with complete hair regrowth within 2 months (Fig. 5). She is currently cleared of scalp lesions for 12 months, but presents occasional flares of scaly plaques on the plantar and internal malleolar regions.

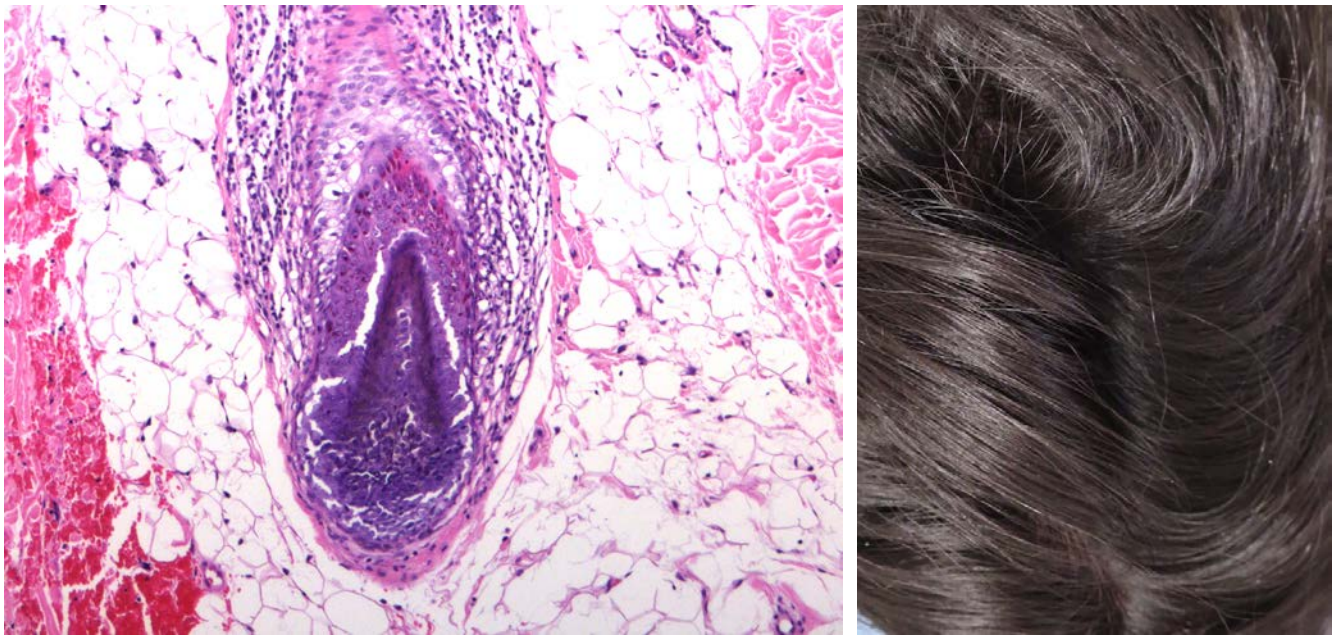


---

Figure 1. Alopecia patches associated with scalp erythema and psoriasiform scaling during adalimumab treatment.



**Figure 2.** Scalp biopsy showing marked psoriasiform epidermal hyperplasia associated with alopecia areata-like changes in the dermis (H&E, 25x). **Figure 3.** Higher power view of the epidermis highlighting the epidermal hyperplasia with elongation of the dermal papillae, hypogranulosis, and confluent parakeratosis containing neutrophils (H&E, 100x).



**Figure 4.** Higher power view illustrating the peribulbar lymphocytic inflammation (H&E, 100x). **Figure 5.** Complete hair regrowth after withdrawal of adalimumab.

## Discussion

Psoriasiform eruptions during anti-TNF- $\alpha$  therapy have an estimated prevalence of 1.5 to 5% [1] and usually present as chronic plaque or guttate psoriasis or palmoplantar pustulosis [2]. Although the pathophysiology of this paradoxical effect is not fully understood, two mechanisms have been proposed. In the first, TNF- $\alpha$  blockade increases interferon- $\alpha$  production by plasmacytoid dendritic cells, resulting in activation and amplification of pathogenic T-cells [1,2]. In the second mechanism, TNF- $\alpha$  blockade induces a Th17 immune response and down-regulation of Treg cells [3]. When affecting the scalp, new-onset psoriasis induced by anti-TNF- $\alpha$  agents can result in nonscarring and scarring alopecia [1,2,4]. Histological findings of psoriatic alopecia include psoriasiform epidermal features, along with perifollicular inflammation and atrophy or loss of the sebaceous glands, and, in late stages, destruction of the hair follicle with perifollicular fibrosis [4].

Alopecia is a less well-known side effect of TNF- $\alpha$  inhibitors that has become more recognized in recent years [1,5]. The causes of alopecia occurring during anti-TNF therapy include alopecia areata, psoriatic alopecia, lichen planopilaris, drug-induced lupus erythematosus, androgenetic alopecia, and telogen effluvium [1]. Recently, Doyle *et al* have described a distinct entity that combines clinical and histopathological features of both alopecia areata and psoriatic alopecia, referred to as "psoriatic alopecia/alopecia areata-like reaction secondary to anti-TNF treatment" [5]. Histologically, this form of alopecia is characterized by the presence of psoriasiform epidermal features (acanthosis, hypogranulosis, confluent parakeratosis, and intracorneal neutrophils) and alopecia areata-like dermal changes (marked increase in catagen/telogen and miniaturized follicles and peribulbar lymphocytic inflammation), along with numerous eosinophils and plasma cells [5]. It remains unclear whether this in fact represents a distinct clinical entity or rather a subset of the aforementioned diseases [1].

There is no consensus regarding management of alopecia induced by TNF- $\alpha$  inhibitors and many treatment strategies come from anecdotal experience [1]. For the recently described psoriatic alopecia/alopecia areata-like reaction secondary to anti-TNF- $\alpha$  treatment, in which category our patient seems to fall, cessation of treatment may not be necessarily mandatory, as alopecia has showed significant improvement with topical treatment alone [5,6]. For psoriasis induced by anti-TNF- $\alpha$ , in the presence of severe scalp involvement anti-TNF- $\alpha$  suspension is recommended, and phototherapy and systemic therapies including methotrexate, acitretin and cyclosporine A may be required [1,2,7]. In patients with less extensive psoriasis, a switch to another anti-TNF- $\alpha$  may result in improvement [7]. In both cases, topical therapies (corticosteroids, vitamin D) can be effective [1,7]. In patients who have limited psoriasiform lesions and prefer not to discontinue or switch to another biologic agent, addition of topical therapies, phototherapy or methotrexate may be effective and avoid a change in biologic therapy [7].

## References:

1. Lindsey SF, Tosti A. Hair loss induced by tumor necrosis factor alpha inhibitors. *J Clin Investigat Dermatol.* 2013;1(1):6.
2. Osório F, Magro F, Lisboa C, Lopes S, Macedo G, Bettencourt H, Azevedo F, Magina S. Anti-TNF-alpha induced psoriasiform eruptions with severe scalp involvement and alopecia: report of five cases and review of the literature. *Dermatology.* 2012;225(2):163-7. [PMID: 23052429]
3. Ma HL, Napierata L, Stedman N, Benoit S, Collins M, Nickerson-Nutter C, Young DA. Tumor necrosis factor alpha blockade exacerbates murine psoriasis-like disease by enhancing Th17 function and decreasing expansion of Treg cells. *Arthritis Rheum.* 2010 Feb;62(2):430-40. [PMID: 20112373]
4. George SM, Taylor MR, Farrant PB. Psoriatic alopecia. *Clin Exp Dermatol.* 2015 Jul 23. doi:10.1111. [PMID: 26202646]
5. Doyle LA, Sperling LC, Baksh S, Lackey J, Thomas B, Vleugels RA, Qureshi AA, Velazquez EF. Psoriatic alopecia/alopecia areata-like reactions secondary to anti-tumor necrosis factor- $\alpha$  therapy: a novel cause of noncicatricial alopecia. *Am J Dermatopathol.* 2011 Apr;33(2):161-6. [PMID: 21317611]
6. Ribeiro LB, Rego JC, Estrada BD, Bastos PR, Piñeiro Maceira JM, Sodré CT. Alopecia secondary to anti-tumor necrosis factor-alpha therapy. *An Bras Dermatol.* 2015 Mar-Apr;90(2):232-5. [PMID: 25830994]
7. Collamer AN, Guerrero KT, Henning JS, Battafarano DF. Psoriatic skin lesions induced by tumor necrosis factor antagonist therapy: a literature review and potential mechanisms of action. *Arthritis Rheum.* 2008 Jul 15;59(7):996-1001. [PMID: 18576309]