

# UC Davis

## Dermatology Online Journal

### Title

Hydroa vacciniforme: a rare photodermatosis

### Permalink

<https://escholarship.org/uc/item/7961b22b>

### Journal

Dermatology Online Journal, 20(8)

### Authors

Haddad, Jebran M  
Monroe, Holly R  
Hardin, Justin  
[et al.](#)

### Publication Date

2014

### DOI

10.5070/D3208023539

### Copyright Information

Copyright 2014 by the author(s). This work is made available under the terms of a Creative Commons Attribution-NonCommercial-NoDerivatives License, available at <https://creativecommons.org/licenses/by-nc-nd/4.0/>

Peer reviewed

**Photo Vignette**

**Hydroa vacciniforme: a rare photodermatosis**

**Jebran M. Haddad MD, Holly R. Monroe MD, Justin Hardin MD, A. Hafeez Diwan MD, Sylvia Hsu MD**

**Dermatology Online Journal 20 (8): 13**

**Baylor College of Medicine, Department of Dermatology**

**Correspondence:**

Sylvia Hsu, M.D.  
Professor of Dermatology  
Baylor College of Medicine  
shsu@bcm.edu

**I. Abstract**

Hydroa vacciniforme (HV) is a rare photodermatosis characterized by a recurrent vesiculopapular eruption with varioliform scarring. The pathogenesis remains unknown. Herein we present a case to emphasize the importance of recognizing this condition and its clinical mimickers, which include other photodermatoses and lymphoma.

**Key Words: hydroa vacciniforme, hydroa vacciniforme-like lymphoma**

**II. Introduction**

Hydroa vacciniforme (HV) was first observed by Bazin in 1862, and its diagnosis is based on clinical and histopathological features [1, 2]. It is typically a disease of childhood, but may extend into adulthood [2, 3]. HV has been described to occur more often in males, in a 2:1 ratio, with a longer duration and later onset in males [3]. It is characterized by vesiculopapules on sun-exposed areas occurring a few hours after sun exposure. The vesicles then crust and heal over a period of 1-6 weeks, leaving behind depressed varioliform scars. Systemic symptoms are typically absent, and there are no specific laboratory tests for diagnosis [1, 2]. Severe forms of HV may present with fever, hepatosplenomegaly, or wasting, and have been reported to precede the diagnosis of Epstein-Barr Virus (EBV)-associated NK/ T-cell lymphoma [2].

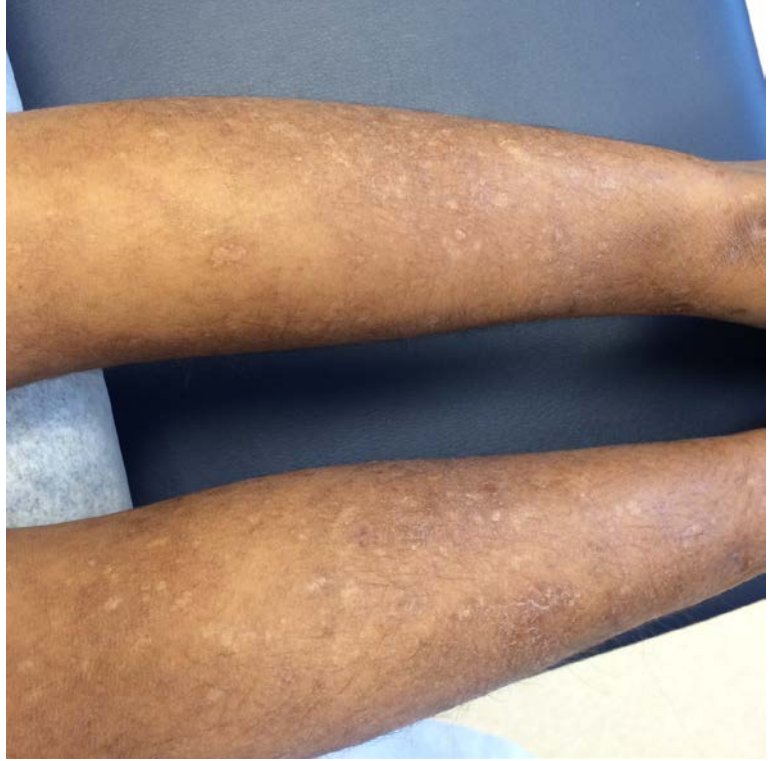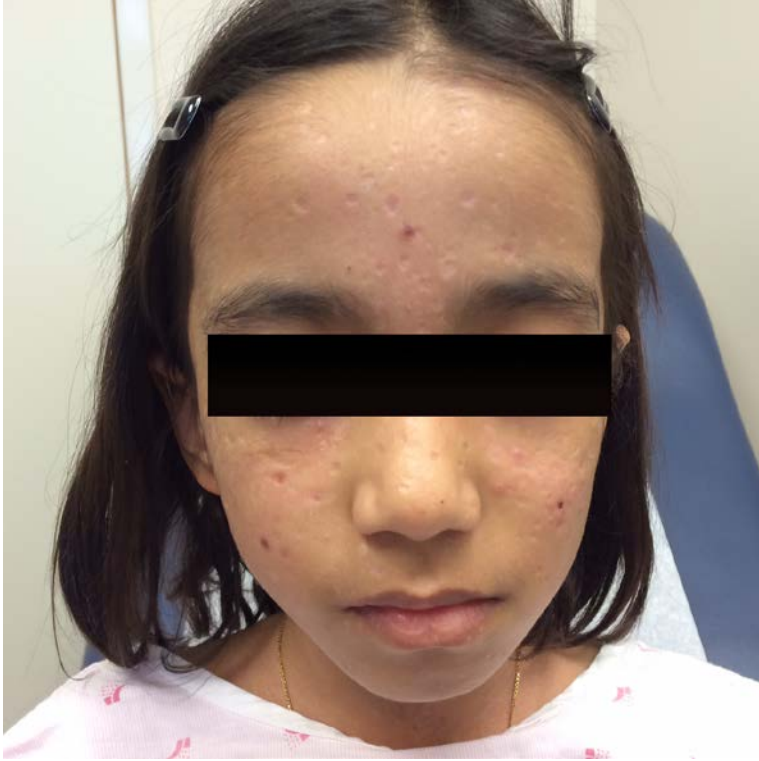**III. Case synopsis**

A 9-year-old girl presented to our clinic with a 1-year history of asymptomatic, generalized recurrent skin eruptions along with subjective fevers and anorexia. She had no other systemic complaints and no family history of skin disorders.

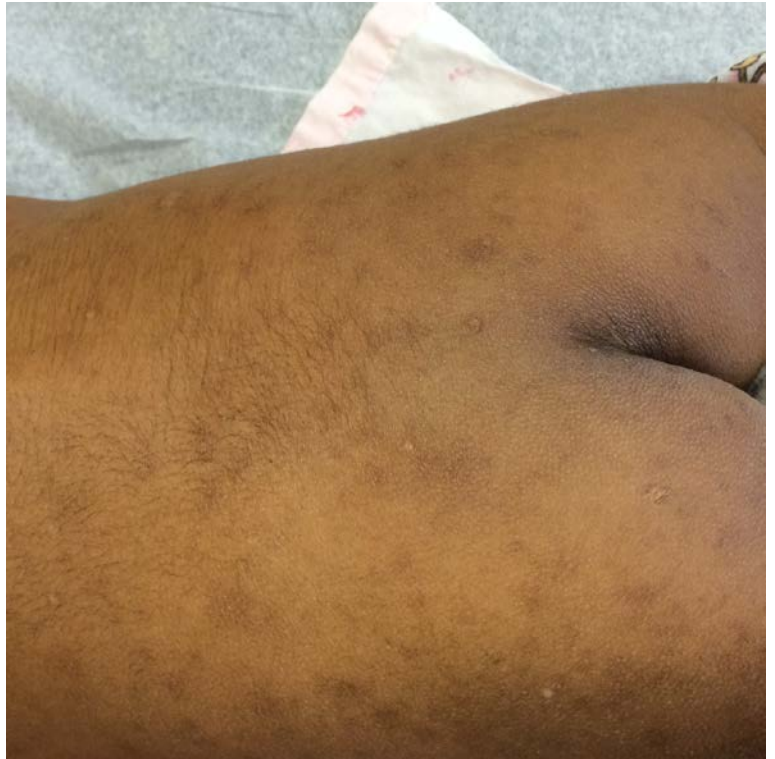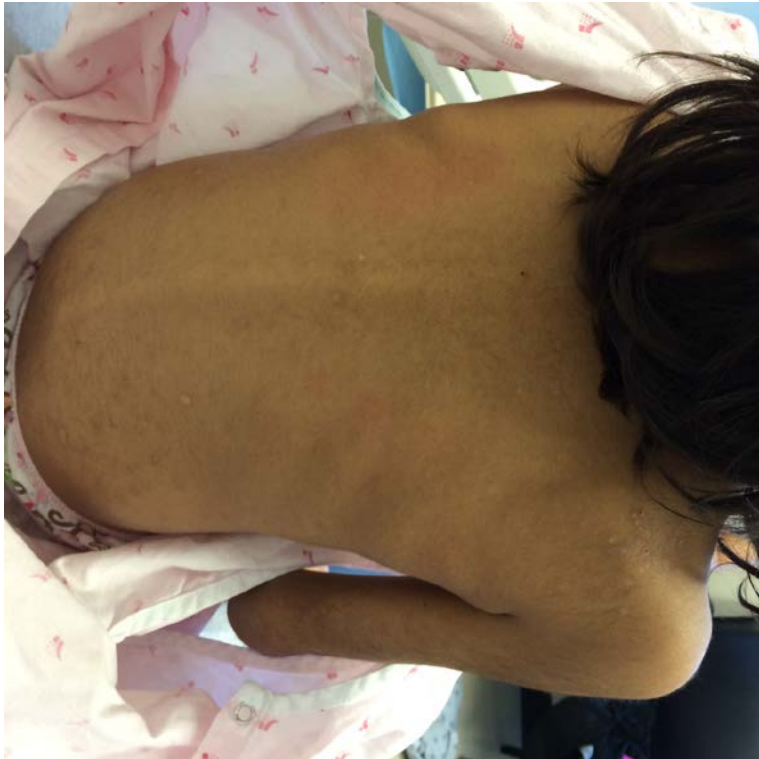On exam, the patient was thin with numerous varioliform scars and crusted papules present on the face, bilateral extremities, upper chest, and back in a predominantly photodistribution (Figure 1, 2). There were a few lesions on the buttocks (Figure 3, 4). Facial edema, excoriations, cheilitis, lymphadenopathy, and hepatosplenomegaly were absent.

Hematological studies showed an iron deficiency anemia, thrombocytosis, and leukocytosis. Liver function tests showed mild hypoalbuminemia with no transaminitis. Serum and urine porphyrins were negative. EBV IgG serology was positive and EBV IgM serology was negative. EBV DNA PCR from peripheral blood showed 1900 copies/mL.

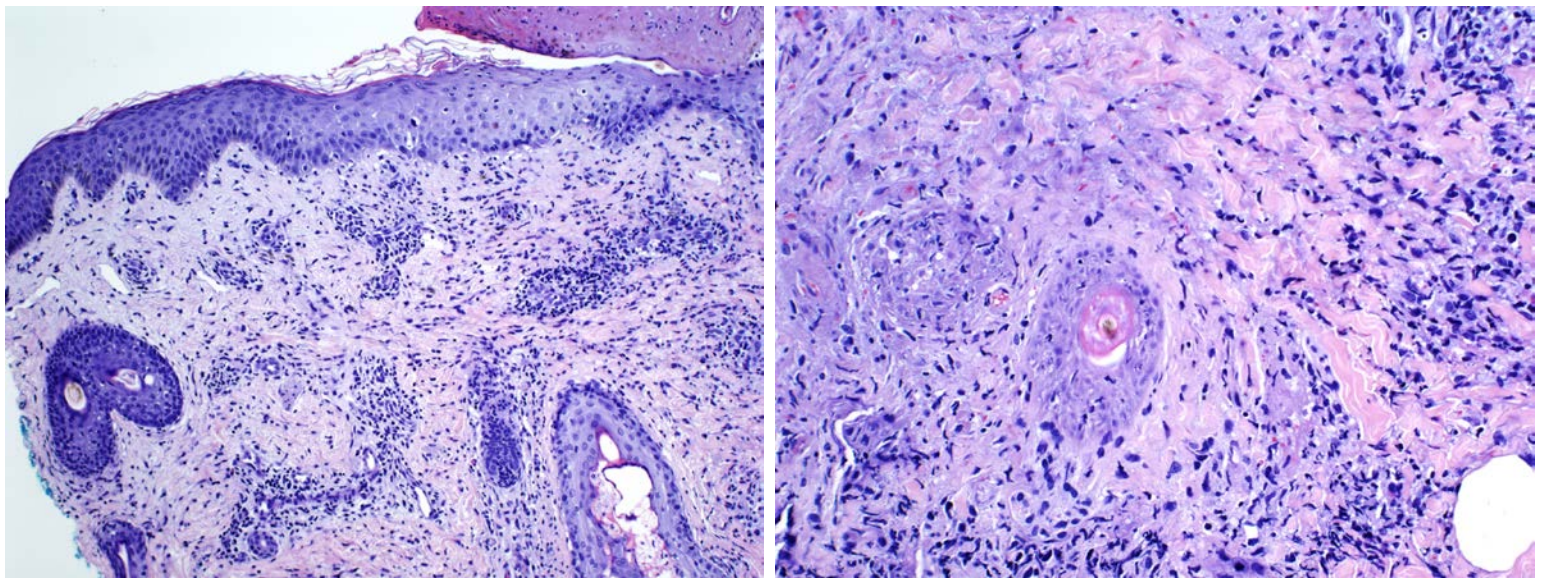
A 4-mm punch biopsy of an erythematous papule on the right cheek showed areas of epidermal necrosis with underlying dermal necrosis and a perivascular and periadnexal mixed infiltrate. (Figures 5, 6) Gram, GMS, and AFB stains were negative.



**Figure 1 and Figure 2.** Active lesions and varioliform scars on face and lower extremities



**Figure 3 and Figure 4.** Varioliform scars on back and buttocks



**Figure 5 and Figure 6.** H&E 100X and 200X, respectively. Broad area of full-thickness epidermal necrosis surrounded by scale crust and a corresponding area of wedge-shaped dermal necrosis, which extends to the subcutaneous tissue is demonstrated. In the surrounding viable dermis, there are perivascular, periadnexal, and interstitial lymphohistiocytic infiltrates.

## IV. Discussion

Hydroa vacciniforme encompasses a spectrum of manifestations. Typical HV has the following 3 criteria: (i) self-limiting vesiculopapular eruptions on exposed areas including the face, lips, cheeks, and dorsal surfaces of the hands; (ii) histological features of reticulated epidermal necrosis or blister formation associated with dense lymphocytic infiltration; and (iii) exclusion of hereditary photodermatoses. Severe HV presents with the aforementioned typical findings in addition to one or more of the following clinical signs: (i) high-grade fever; (ii) liver damage; (iii) ulcerative indurated lesions; (iv) edematous swelling of the cheeks, ears, lips, and eyelids [4]. Some studies suggest that evidence of lesions in sun-protected areas, wasting, or hepatosplenomegaly also qualify the presentation as severe [2, 4]. Our patient's clinical and histological findings were consistent with hydroa vacciniforme, though her history of fever and presence of lesions in sun-protected areas raised the concern for severe HV.

Several studies have demonstrated that HV occurs in response to UVA light in the range of 320-390 nm, but no chromophore has been identified [3]. A relationship between EBV and immunosuppression has been suggested, whereby UV irradiation-induced IL-10 release promotes the EBV lytic cycle within active HV lesions. Studies have shown the presence of EBV DNA and EBV particles in T-cells within active lesions of HV patients and its absence in nonlesional skin as well as in lesions of other photodermatoses. It has been reported that serum EBV DNA is elevated in HV in comparison to other photodermatoses as well. These EBV findings are present both in typical and severe forms of HV [2, 4]. Our patient had a mildly elevated serum EBV DNA with serology indicative of prior EBV exposure.

The histological hallmark of HV is reticular degeneration followed by epidermal necrosis with dense lymphocytic dermal infiltrate and sparse neutrophils. Perivascular and periadnexal lymphocytic infiltration may also be seen as in our patient. Severe forms of HV have deeper dermal infiltration as compared to typical forms [4].

The differential diagnosis of hydroa vacciniforme includes polymorphic light eruption (PMLE), erythropoietic protoporphyria (EPP), porphyria cutanea tarda (PCT), actinic prurigo, herpes simplex eruption, and varicella. Serum and urine porphyrins were normal in our patient. No atypical lymphocytes, viral changes, or dermal edema were observed on histology to suggest HV-like lymphoma, viral infection, or PMLE. Moreover, the eruption was asymptomatic and was not associated with cheilitis or bilateral conjunctivitis as expected with actinic prurigo.

Complications of HV are rare, but the most fatal are EBV-associated NK/T-cell lymphomas. In patients with severe forms of HV, the patient should be monitored closely for signs of lymphoma. Other complications include ocular involvement, oral mucosal lesions, and deformities of the nose, ears, and hands secondary to severe scarring [4, 7, 9].

Treatment options for HV are limited. Sun avoidance and use of broad-spectrum sunscreens have been reported to diminish and sometimes prevent skin eruptions. Systemic therapy, including antimalarials,  $\beta$ -carotene, and thalidomide have been attempted with limited success [3, 6, 9]. We recommended strict sun avoidance and use of sunscreens for our patient.

## V. Conclusion

Herein we present a case of a rare photodermatosis primarily affecting children. In patients with systemic symptoms, biopsy and serologic and urine studies should be performed to exclude HV-like lymphoma, photodermatoses, and infection. These patients should be monitored by a multidisciplinary team of physicians, including a pediatrician, oncologist, and dermatologist, given that patients with hydroa vacciniforme and systemic findings or more widespread lesions may progress to lymphoma.

## References

1. Cho KH, Kim CW, Heo DS, et al. Epstein-Barr virus-associated peripheral T-cell lymphoma in adults with hydroa vacciniforme-like lesions. *Clin Exp Dermatol*. 2001;26(3):242-7. [PMID: 11422165]
2. Cho KH, Lee SH, Kim CW, et al. Epstein-Barr virus-associated lymphoproliferative lesions presenting as a hydroa vacciniforme-like eruption: an analysis of six cases. *Br J Dermatol*. 2004;151(2):372-80. [PMID: 15327544]
3. Gupta G, Man I, Kemmett D. Hydroa vacciniforme: A clinical and follow-up study of 17 cases. *J Am Acad Dermatol*. 2000;42(2 Pt 1):208-13. [PMID: 10642674]
4. Iwatsuki K, Satoh M, Yamamoto T, et al. Pathogenic link between hydroa vacciniforme and Epstein-Barr virus-associated hematologic disorders. *Arch Dermatol*. 2006;142(5):587-95. [PMID: 16702496]
5. Iwatsuki K, Xu Z, Takata M, et al. The association of latent Epstein-Barr virus infection with hydroa vacciniforme. *Br J Dermatol*. 1999;140(4):715-21. [PMID: 10233328]
6. Jacyk WK, Moosa Y. Crusts and vacciniform scars on sun-exposed skin. *Clin Exp Dermatol*. 2010;35(1):97-8. [PMID: 20028406]
7. Jeng BH, Margolis TP, Chandra NS, Mccalmon TH. Ocular findings as a presenting sign of hydroa vacciniforme. *Br J Ophthalmol*. 2004;88(11):1478-9. [PMID: 15489499]
8. Verneuil L, Gouarin S, Comoz F, et al. Epstein-Barr virus involvement in the pathogenesis of hydroa vacciniforme: an assessment of seven adult patients with long-term follow-up. *Br J Dermatol*. 2010;163(1):174-82. [PMID: 20367637]
9. Yesudian PD, Sharpe GR. Hydroa vacciniforme with oral mucosal involvement. *Pediatr Dermatol*. 2004;21(5):555-7. [PMID: 15461761]