

# UC Davis

## Dermatology Online Journal

### Title

New world cutaneous leishmaniasis

### Permalink

<https://escholarship.org/uc/item/6bc5398b>

### Journal

Dermatology Online Journal, 20(12)

### Authors

Trufant, Joshua W  
Lewin, Jesse M  
Hale, Christopher S  
et al.

### Publication Date

2015

### DOI

10.5070/D32012025051

### Copyright Information

Copyright 2015 by the author(s). This work is made available under the terms of a Creative Commons Attribution-NonCommercial-NoDerivatives License, available at <https://creativecommons.org/licenses/by-nc-nd/4.0/>

Peer reviewed

## Case Presentation

### New world cutaneous leishmaniasis

Joshua W. Trufant MD, Jesse M. Lewin MD, Christopher S. Hale MD, Shane A. Meehan MD, and Miriam Keltz Pomeranz MD

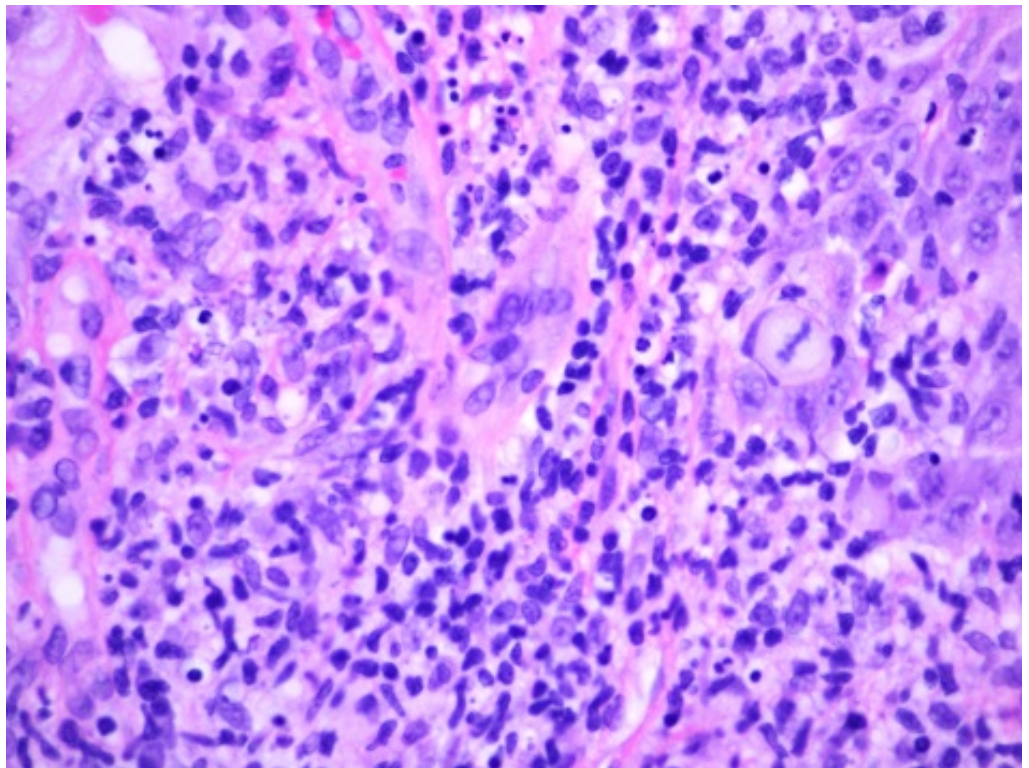
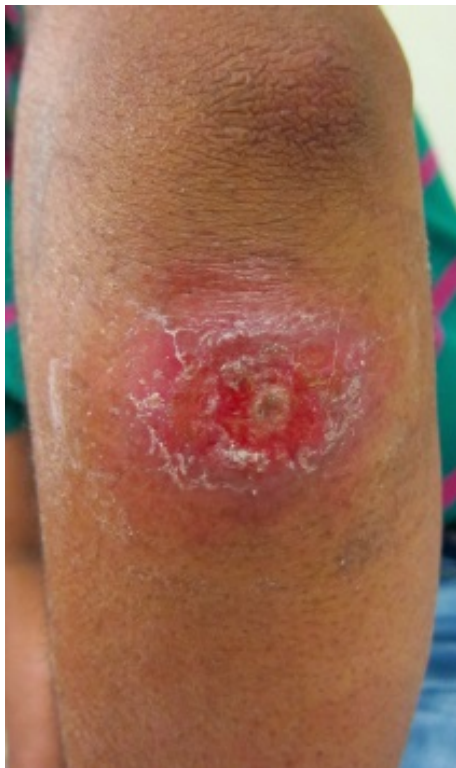Dermatology Online Journal 20 (12): 3

New York University School of Medicine

Special Guest Editor: Nicholas A. Soter, MD

## Abstract

A 24-year-old Bangladeshi man presented with a 12-week history of a pruritic papule on his left elbow that had enlarged and ulcerated. He was without any constitutional or systemic symptoms. He reported a history of extensive travel in the two years prior to presentation that included Bangladesh, South and Central America, and Mexico. Histopathologic features were consistent with leishmaniasis. Speciation by the Centers for Disease Control showed *L. brasiliensis*.



## Case synopsis

**History:** A 24-year-old Bangladeshi man presented to the Bellevue Hospital Center Urgent Care Clinic with a 12-week history of a plaque on his left forearm. The patient provided an extensive travel history that began in December, 2012, when he left Bangladesh for Bolivia. After two weeks in Bolivia, he spent six months in Brazil and then one month each in Colombia, Panama, and Mexico before arriving in California in January, 2014. He first noticed a small, pruritic papule on his arm while living in California, where he was initially treated empirically with a course of cephalexin and doxycycline. At the time of presentation, the

papule had enlarged to become a plaque, which was ulcerated and was no longer pruritic. He denied fever, chills, or any other systemic symptoms.

**Physical examination:** The patient was afebrile. Distal to his left elbow there was a 2.5-cm, indurated, erythematous, scaly plaque with central serous crust. It was not warm or tender to palpation. No drainage was noted. The mucous membranes were normal and adenopathy was not present.

**Laboratory data:** A complete blood count and comprehensive metabolic panel were normal. Polymerase chain reaction (PCR) of the skin biopsy showed *L. brasiliensis*.

**Histopathology:** There is a diffuse infiltrate of lymphocytes, histiocytes, and plasma cells throughout the dermis. Within some histiocytes and free within the dermis are scattered, small, circular structures with eccentric basophilic condensations.

## Discussion

**Diagnosis:** New World cutaneous leishmaniasis

**Comment:** Leishmaniasis is a chronic protozoan infection that is endemic to the Middle East, South Asia, Africa, and Latin America. Cases are traditionally characterized as Old World or New World depending on their geographic origin and causative *Leishmania* species. Four clinical patterns have been described: cutaneous (CL), mucocutaneous (MCL), diffuse cutaneous (DCL), and visceral leishmaniasis (VL). The World Health Organization estimates that up to 1.2 million new cases of CL occur annually [1]. The vast majority of cutaneous cases that are diagnosed in the United States (US) are acquired elsewhere by travelers and immigrants from endemic areas although a small number of endemic cases have been identified in Texas [2]. Incidence of Old World CL diagnoses in the US has increased over the past 20 years largely in military personnel and civilians who are returning from Middle East wars [3]. New World CL has seen a similar surge in the US as more Americans are traveling to Central America, particularly Costa Rica [4, 5].

More than 20 pathogenic *Leishmania* species have been identified. Old World CL is most commonly caused by *L. major* and *L. tropica* species in Asia, India, and the Middle East; *L. infantum* in the Mediterranean; and *L. aethiopica* and *L. donovani* in Africa [6]. Rodents and dogs are the main reservoirs; the sandfly of the genus *Phlebotomus* is the vector of transmission. New World CL is transmitted by the *Lutzomyia* sandfly and is caused by a wide range of species, which include *L. mexicana* in Mexico and Central and South America and *L. amazonensis* and *L. guyanensis* in the Amazon rain forest where wild animals are the most common reservoirs. *L. braziliensis* is the most common cause of MCL, which is a clinical pattern unique to the New World [6]. Owing to our patient's travel history, both Old and New World species were considered possible causative organisms.

All *Leishmania* species exist in an extracellular, flagellated promastigote form in the gut of the sandfly. They are then transmitted via the proboscis during a feeding on a mammalian host in which they are phagocytosed by macrophages, transformed into intracellular, non-flagellated amastigotes, and multiply by binary fission [7]. The incubation time in humans may range from two months to two years before symptoms appear.

Clinical manifestations of Old World and New World CL vary by *Leishmania* species and the host's cell-mediated immune response. A Th1 cytokine profile, and in particular IFN-gamma and TNF-alpha production, is associated with resistance to infection and self-limited disease whereas a Th2-predominant response is associated with disease susceptibility or progression [8]. The classic clinical manifestation of CL is a solitary, erythematous papule at the site of the sandfly bite that enlarges to a plaque with a distinct, raised border and subsequently ulcerates [9]. Satellite lesions or sporotrichoid spread with lymphadenopathy may be present. Most common sites of involvement are exposed areas on the head, neck, or upper extremities.

Diagnosis is most often made by identification of amastigotes in Geimsa-stained dermal scrapings from the ulcer's borders or in paraffin-embedded tissue specimens obtained by skin biopsy. In the US, punch biopsy specimens may be sent to the Centers for Disease Control (CDC) for identification of *Leishmania* species by polymerase chain reaction (PCR) [10]. PCR of our patient's biopsy specimen showed *L. brasiliensis*, which is a common cause of New World CL.

Whereas Old World CL is typically self-limited over several months, New World CL is less likely to spontaneously resolve. Treatment may be initiated to prevent relapse, local dissemination, or progression to diffuse cutaneous disease, which is of particular concern in patients with human immunodeficiency virus infection and other forms of immunocompromise [11]. Prompt treatment also may help to limit the formation of depressed scars in cosmetically sensitive areas. Pentavalent antimonials, most commonly sodium stibogluconate, are the mainstay of treatment in the US and abroad. A typical regimen for New World CL is sodium stibogluconate or meglumine antimoniate 20 mg/kg parenterally for three to four weeks [12]. However, owing to toxicity,

these medicines are not FDA-approved and must be obtained through the CDC and approved for use by a local institutional review board. Cure rates of cutaneous disease range from 70 to 90% [13]. Our patient has not yet begun treatment because speciation was only recently completed.

## References

1. World Health Organization. Leishmaniasis: situation and trends. Available from: [http://www.who.int/gho/neglected\\_diseases/leishmaniasis/en/](http://www.who.int/gho/neglected_diseases/leishmaniasis/en/). Last accessed April 27, 2014.
2. Wright NA, *et al.* Cutaneous leishmaniasis in Texas: a northern spread of endemic areas. *J Am Acad Dermatol* 2008;58:650 [PMID: 18249464]
3. Weina PJ, *et al.* Old world leishmaniasis: an emerging infection among deployed US military and civilian workers. *Clin Infect Dis* 2004;39:1674 [PMID: 15578370]
4. Scope A, *et al.* Experience with New World cutaneous leishmaniasis in travelers. *J Am Acad Dermatol* 2003;49:672 [PMID: 14512915]
5. McCullem R. New world leishmaniasis: a surge in incidence in the United States. *J Am Acad Dermatol* 2008;58:AB12
6. Lupi O, *et al.* Tropical dermatology: tropical diseases caused by protozoa. *J Am Acad Dermatol* 2009;60:897 [PMID: 19467364]
7. Samady JA, Schwartz RA. Old World cutaneous leishmaniasis. *Int J Dermatol* 1997;36:161 [PMID: 9158994]
8. Pirmez C, *et al.* Cytokine patterns in the pathogenesis of human leishmaniasis. *J Clin Invest* 1993;91:1390 [PMID: 8473490]
9. Markle WH, Makhoul K. Cutaneous leishmaniasis: recognition and treatment. *Am Fam Physician* 2004;69:1455 [PMID: 15053410]
10. David CV, Craft N. Cutaneous and mucocutaneous leishmaniasis. *Dermatolog Ther* 2009;22:491 [PMID: 19889134]
11. Van Griensven J, *et al.* Leishmaniasis in immunosuppressed individuals. *Clin Microbiol Infec* 2014;20:286 [PMID: 24450618]
12. Mitropoulos P., *et al.* New world cutaneous leishmaniasis: updated review of current and future diagnosis and treatment. *J Am Acad Dermatol* 2010; 63: 309 [PMID: 20303613]
13. Murray HW. Leishmaniasis in the United States: treatment in 2012. *Am J Trop Med Hyg* 2012;86:434 [PMID: 22403313]