

# UC Davis

## Dermatology Online Journal

### Title

A de novo mutation of KRT1 in a baby girl causing epidermolytic ichthyosis with impressive epidermolytic palmoplantar keratoderma

### Permalink

<https://escholarship.org/uc/item/6642w2p4>

### Journal

Dermatology Online Journal, 26(7)

### Authors

Calì, Francesco  
Failla, Pinella  
Vinci, Mirella  
et al.

### Publication Date

2020

### DOI

10.5070/D3267049560

### Copyright Information

Copyright 2020 by the author(s). This work is made available under the terms of a Creative Commons Attribution-NonCommercial-NoDerivatives License, available at <https://creativecommons.org/licenses/by-nc-nd/4.0/>

Peer reviewed

# A de novo mutation of KRT1 in a baby girl causing epidermolytic ichthyosis with impressive epidermolytic palmoplantar keratoderma

Francesco Cali, Pinella Failla, Mirella Vinci, Maddalena Siragusa, Carmelo Schepis

Affiliations: Oasi Research Institute – IRCCS (Istituto di Ricovero e Cura a Carattere Scientifico), Troina, Italy

Corresponding Author: Francesco Cali, Laboratory of Molecular Genetics, Oasi Research Institute – IRCCS (Istituto di Ricovero e Cura a Carattere Scientifico), Via Conte Ruggero, 7394018 Troina, Italy, Tel: 39-0935 936288, Fax: 39-0935 936533, Email: [cali@oasi.en.it](mailto:cali@oasi.en.it)

## Abstract

We report a 6-year-old girl showing epidermolytic ichthyosis/epidermolytic hyperkeratosis (EI/EH). Targeted Next Generation Sequencing revealed a de novo, previously unidentified *KRT1* mutation. The findings of this study expands the clinical and mutational spectrum and genotype-phenotype correlation associated with EI/EH.

*Keywords: KRT1, epidermolytic ichthyosis, palmoplantar keratoderma, NGS*

## Introduction

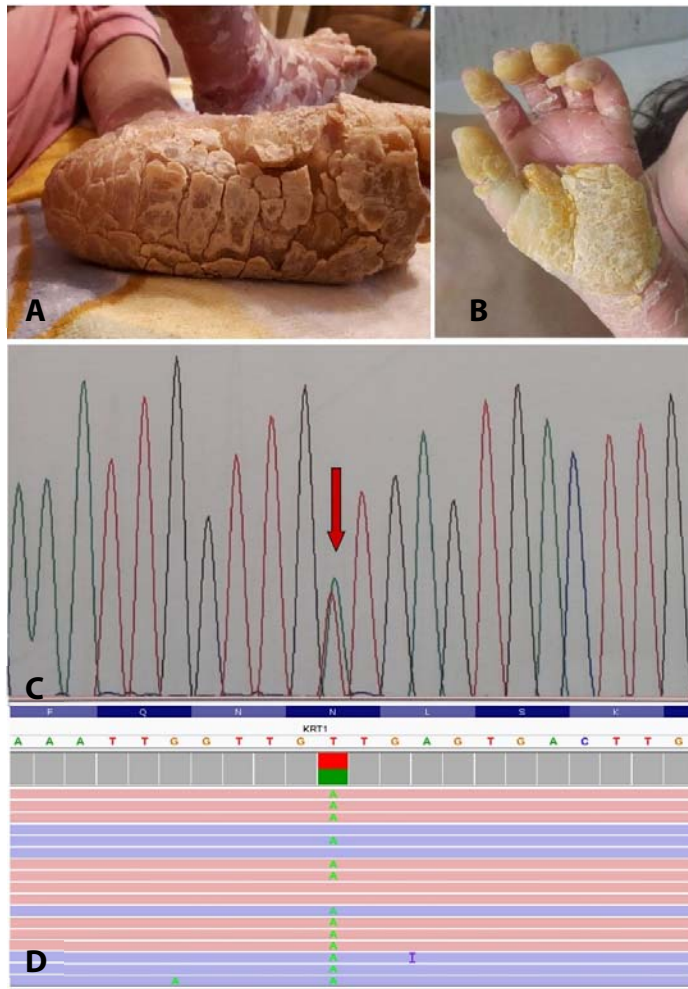
The term ichthyoses encompasses a heterogeneous group of genetic skin diseases whose skin manifestations include cutaneous desquamation. Epidermolytic hyperkeratosis (autosomal dominant transmission) is a rare form of congenital ichthyosis with blisters or bullae related to acantholysis. It has a prevalence of 1: 200,000 [1] with 50% of cases occurring as spontaneous mutations [2]. The disorder is characterized by changes in keratinization caused by a failure in the keratin 1 and/or 10 filament network with fragile keratinocytes, especially of the upper epidermis. Severe forms of ichthyosis are resistant to topical treatment but oral retinoids in several cases have been shown to be a useful mode of treatment. Defects in genes for *keratin 1 (KRT1)* and *10 (KRT10)* are the cause of epidermolytic hyperkeratosis [3].

## Case Synopsis

A 6-year-old girl presenting with epidermolytic ichthyosis/epidermolytic hyperkeratosis (also referred as congenital bullous ichthyosiform erythroderma) was admitted to our tertiary regional center for ichthyoses and genodermatoses. On physical examination, she appeared malnourished and in poor health. The skin of soles, knees, and both sides of the neck was coated by thick scales with a slipper-like appearance of the palmoplantar skin (**Figure 1A, B**), which prevented the child from walking. Epidermolytic areas were present and evident upon the trunk.

Histopathological examination of the lesional skin was performed elsewhere during the child's first year. Results showed orthokeratosis and epidermal acanthosis with cytolysis of the cells of granular and Malpighian layers, which caused a detachment of the upper layers of the epidermis. Ultrastructural examination also showed extensive "clumping" linked to the abnormal aggregation of the tonofilaments of granular and Malpighian layers. Such findings led to the diagnosis of epidermolytic ichthyosis.

Informed consent was obtained from patient's parents. Genomic DNA was isolated from peripheral blood leucocytes according to standard protocols. Mutation analysis (all coding exons and splice sites) of the genes *KRT1* and *KRT10* were amplified using a Next Generation Sequencing (NGS) panel



**Figure 1. A-B)** Current clinical presentation (6 years of age), showing a particularly impressive hyperkeratosis on the hands and feet. **C)** The Sanger sequencing electropherograms of the proband with heterozygous mutation (c.563A>T). Sequencing electropherogram revealed (red arrows) a heterozygous A to T transversion at position 563 of the *KRT1* gene cDNA (NM\_006121.3). The mutation is predicted to result in the substitution of an Asparagine (Asn) residue for an Isoleucine (Ile) amino acid at position 188 of the amino acid sequence of the *KRT1* protein, producing p.Asn188Ile alteration. The mutation, which has never been previously reported in any case of epidermolytic ichthyosis, was absent in the non-affected members of the family and was not been referenced as single nucleotide polymorphisms (SNPs) nor found in the HGMD Professional Database, 1000 Genomes Database or in the Exome Aggregation Consortium. Mutation has been indicated as implicated in the disease. **D)** Next Generation Sequencing (NGS) visualization with the IGV (Integrative Genomics Viewer) of the heterozygous missense mutation c.563A>T in the *KRT1* gene. Graphic shows a single nucleotide variant (A→T) in the *KRT1* gene (c.563A→T). Pink and blue reads are aligned to the forward and reverse strand, respectively. Reads total count = 542. Only 10 of 542 reads are shown on IGV. The number of reads which map to either the reference or mutated allele at heterozygous c.563A→T mutation of the *KRT1* gene are respectively 269 (reads "A") and 273 (reads "T").

(IAD55509). Reference sequences NM\_006121.3 for *KRT1* and NM\_000421.3 for *KRT10* were used. NGS was performed using the Ion Torrent Personal Genome Machine (Thermo Fisher Scientific). Amplicon library, emulsion PCR, sequencing runs, data analysis of runs, and Sanger confirmation were performed as described in Cali et al. [4]. We identified (confirmed with Sanger sequencing, **Figure 1C**) a heterozygous "de novo" variant c.563A>T (p.Asn188Ile) in the *KRT1* gene (NM\_006121.3), (**Figure 1D**) to our knowledge not described before. The missense variant changes an asparagine (polar) at position 188 to an isoleucine (non-polar). The mutation detected has not been referenced as a single nucleotide polymorphism (SNP) and has not been found in the HGMD Professional Database ([www.hgmd.cf.ac.uk](http://www.hgmd.cf.ac.uk)), 1000 Genomes Database, or Exome Aggregation Consortium. The variant is highly conserved across species and the tested "in silico predictive tool" suggested it was possibly damaging. The impact of the mutation on the structure of the protein was predicted to be "strong" according to ACMG Standard Guidelines (both maternal and paternal "de novo" mutations were confirmed in a patient with the disease and no family history).

## Case Discussion

Next-generation sequencing represents a breakthrough innovation in molecular alteration screening, being a cost-effective approach to high/middle-throughput genotyping. The traditional sequencing methodology, indeed, is still too expensive for the analysis of large genes or the whole genome.

Based on clinical findings, we performed NGS for *KRT1* and *KRT10* genes. Next-generation sequencing analysis detected in the patient a heterozygous "de novo" variant c.563A>T (p.Asn188Ile) in the *KRT1* gene (**Figure 1D**) never described before. This variant was confirmed by Sanger sequencing (**Figure 1C**). Based on several criteria (not described previously in controls, in silico predictive tool, ACMG Standard Guidelines, see method), c.563A>T

(p.Asn188Ile) mutation has been indicated as implicated in the disease.

More than 40 mutations in the *KRT1* gene have been found in patients with epidermic hyperkeratosis, most of which are missense mutations [5]. Genotype/phenotype correlations suggest that the most severe disease is caused by mutations in the 1A helix initiation motif of keratin 1 [6, 7], as is the residue at position 188 (p.Asn188Ile) found in our patient. The residual asparagine (Asn188) is located in the region that is involved in the lateral alignment between heterodimers and could result in impairment in intermediate filament assembly thus compromising the maintenance of both cellular and tissue integrity [8]. Other mutations have been shown to affect the p.Asn188 residue (p.Asn188His, p.Asn188Lys, p.Asn188Ser, p.Asn188Thr), which has been previously described with variable phenotype (with or without epidermolysis) in families with bullous congenital ichthyosiform erythroderma, severe neonatal blistering and palmoplantar keratodermas, and extensive epidermolytic hyperkeratosis [8-11]. It could be possible to suggest that the effects on the phenotype of p.Asn188 mutations are specifically related to the nature of each substitution. The reason why the alteration of

the same residue leads to different phenotypes is still unclear. However, it is remarkable to note that the same mutation in *KRT1* patients can cause a different phenotype, likely because of other factors that may influence the clinical phenotype [12].

## Conclusion

Our patient and the finding of this novel mutation in the “target-gene” allows us to increase the number of EI/EH-related mutations and to extend the clinical features associated with variants in the *KRT1* gene.

## Potential conflicts of interest

The authors declare no conflicts of interests.

## Acknowledgments

Special acknowledgements for this paper are due to Mrs. Eleonora Di Fatta for her valuable assistance in the translation, preparation and formatting of the text. This work was partially supported by the Italian Ministry of Health – Ricerca Corrente 2018 - and ‘5 per mille’ funding.

## References

- Müller FB, Huber M, Kinaciyan T, et al. A human keratin 10 knockout causes recessive epidermolytic hyperkeratosis. *Hum Mol Genet.* 2006;15:1133–1141. [PMID: 16505000].
- Covaciu C, Castori M, De Luca N, et al. Lethal autosomal recessive epidermolytic ichthyosis due to a novel donor splice-site mutation in *KRT10*. *Brit. J. Derm.* 2010;162:1384-1387. [PMID: 20302579].
- Lane EB, McLean WH. Keratins and skin disorders. *J Pathol.* 2004;204:355-66. [PMID: 15495218].
- Cali F, Chiavetta V, Ruggeri G, et al. Mutation spectrum of *NF1* gene in Italian patients with neurofibromatosis type one using Ion Torrent PGM™ platform. *Eur J Med Genet.* 2017;60: 93-99. [PMID: 27838393].
- Stenson PD, Mort M, Ball EV, et al. The Human Gene Mutation Database: towards a comprehensive repository of inherited mutation data for medical research, genetic diagnosis and next-generation sequencing studies. *Hum Genet.* 2017;136:665-677. [PMID: 28349240].
- Rothnagel JA, Dominey AM, Dempsey LD, et al. Mutations in the rod domains of keratins 1 and 10 in epidermolytic hyperkeratosis. *Science.* 1992;257:1128-30. [PMID: 1380725].
- Cserhalmi-Friedman PB, Squeo R, Gordon D, et al. Epidermolytic hyperkeratosis in a Hispanic family resulting from a mutation in the keratin 1 gene. *Clin Exp Dermatol.* 2000;25:241-3. [PMID: 10844506].
- Arin MJ, Longley MA, Küster W, et al. An asparagine to threonine substitution in the 1A domain of keratin 1: a novel mutation that causes epidermolytic hyperkeratosis. *Exp Dermatol.* 1999;8:124-7. [PMID: 10232403].
- Eskin-Schwartz M, Drozhdina M, Sarig O, et al. Epidermolytic Ichthyosis Sine Epidermolysis. *Am J Dermatopathol.* 2017;39:440-444. [PMID: 28121638].
- Lee DY, Ahn KS, Lee CH, et al. Two novel mutations in the keratin 1 gene in epidermolytic hyperkeratosis. *J Invest Dermatol.* 2002;119:976-7. [PMID: 12406348].
- Gach JE, Munro CS, Lane EB, et al. Two families with Greither's syndrome caused by a keratin 1 mutation. *J Am Acad Dermatol.* 2005;53:225-30. [PMID: 16227096].
- Zeng YP, Chai WX, Fang K, et al. A recurrent missense mutation of keratin 1 gene in a Chinese family with epidermolytic hyperkeratosis (severe palmoplantar hyperkeratosis, type 1). *Int J Dermatol.* 2012;51:182-5. [PMID: 22250628].