

UC Davis

Dermatology Online Journal

Title

Clinical improvement of a patient with both amyopathic dermatomyositis and psoriasis following treatment with cyclosporine

Permalink

<https://escholarship.org/uc/item/5qh0n741>

Journal

Dermatology Online Journal, 23(8)

Authors

Inkeles, Megan S
No, Daniel
Wu, Jashin J

Publication Date

2017

DOI

10.5070/D3238036019

Copyright Information

Copyright 2017 by the author(s). This work is made available under the terms of a Creative Commons Attribution-NonCommercial-NoDerivatives License, available at <https://creativecommons.org/licenses/by-nc-nd/4.0/>

Clinical improvement of a patient with both amyopathic dermatomyositis and psoriasis following treatment with cyclosporine

Megan S Inkeles¹ MD PhD, Daniel No^{2,3} BA, Jashin J Wu² MD

Affiliations: ¹Department of Dermatology, University of Michigan, Ann Arbor, Michigan, ²Department of Dermatology, Kaiser Permanente Los Angeles Medical Center, Los Angeles, California, ³Loma Linda University School of Medicine, Loma Linda, California

Corresponding Author: Jashin J Wu, MD, Kaiser Permanente, Los Angeles Medical Center, Department of Dermatology, 1515 North Vermont Ave, 5th Floor, Los Angeles, CA 90027, Email: jashinwu@gmail.com

Abstract

Clinically amyopathic dermatomyositis (CADM) is an uncommon subtype of dermatomyositis that rarely presents simultaneously with psoriasis. There are subsequently few reports discussing the management of concurrent CADM and psoriasis. Furthermore, skin lesions of CADM are often recalcitrant to first line dermatomyositis interventions. We present a case of a 45-year-old woman with both CADM and psoriasis whose lesions were resistant to multiple therapies; she eventually achieved disease control and remission with cyclosporine.

Keywords: amyopathic dermatomyositis, psoriasis, treatment, cyclosporine

Introduction

Clinically amyopathic dermatomyositis (CADM) is a subtype of dermatomyositis in which patients present with characteristic cutaneous findings of dermatomyositis without clinical signs of muscle damage [1]. CADM represents less than 20% of patients within the dermatomyositis spectrum and typically responds poorly to conventional dermatomyositis treatments [1, 2]. In contrast to CADM, psoriasis is a T cell mediated disease of chronic inflammation that predominantly affects the skin and/or joints. The pathogenesis of psoriasis involves the aberrant proliferation of pro-inflammatory cells and cytokines and the hyperproliferation of basal keratinocytes [3].

Both CADM and psoriasis are considered to be

chronic inflammatory diseases. The simultaneous presentation of psoriasis and CADM is uncommon and the mechanism motivating their coexistence is unclear. Furthermore, the concurrent management of these diseases is primarily based on anecdotal evidence. We present a patient with coexisting CADM and psoriasis treated successfully with cyclosporine following multiple treatment failures.

Case Synopsis

A 45-year-old woman with a history of psoriasis presented with a four-year history of generalized rash and severe pruritus. She initially presented with a malar rash but no systemic symptoms such as fatigue or myalgia. At the time of examination, the patient had hyperpigmented, lichenoid, reticular patches and plaques sparing the palms, soles, and a well-demarcated linear area on her back (**Figure 1**). The patient also had loose scale on the scalp, periungual telangiectasia, and a few discrete psoriasiform lesions. Laboratory tests were significant for a positive ANA and negative antibodies to dsDNA, SSA, SSB, Smith, RNP, cardiolipin, Scl-70, and centromere. Pathology, not shown here, showed a nonspecific interface dermatitis with perivascular inflammation. The patient was diagnosed with clinically amyopathic dermatomyositis based on her clinical course and presentation.

The patient's management was remarkable for poor responses to multiple treatment modalities. Over four years, she had minimal reduction of erythema and scale under the following regimens: hydroxychloroquine (both generic and brand name, three months), low dose prednisone (five months),

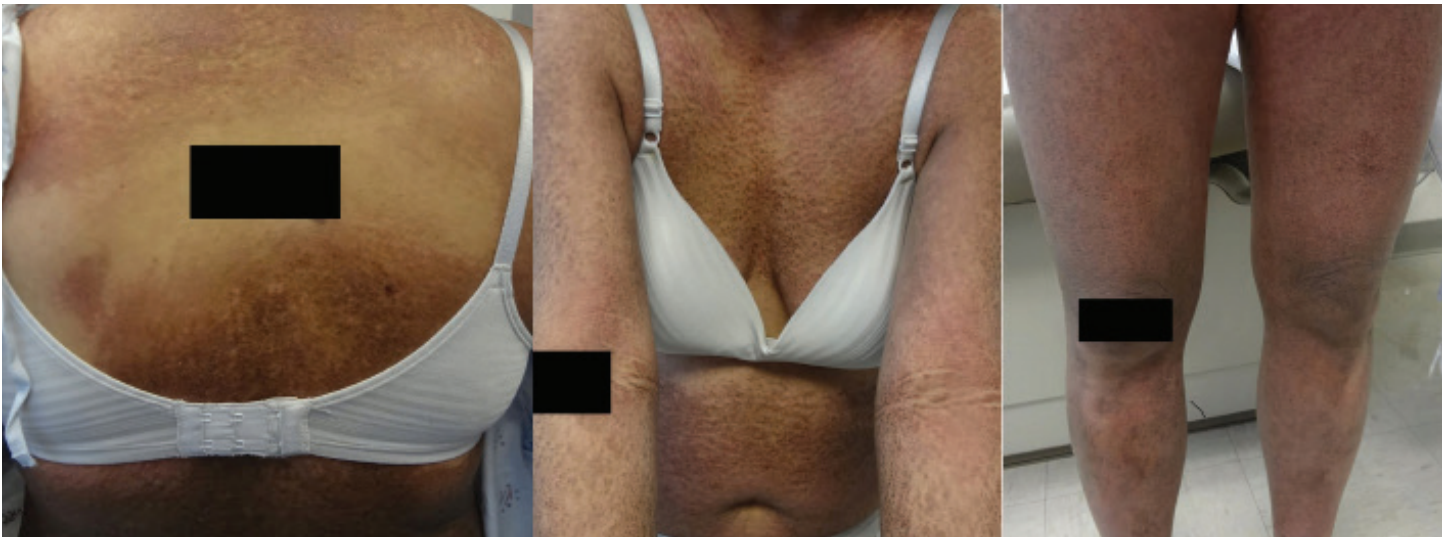

Figure 1. Hyperpigmented, reticulated, hyperkeratotic patches and plaques covering most of the patient's body surface area with notable sparing of a crescent shaped area on the back.

methotrexate (two months), mycophenolate mofetil (five months), azathioprine (six months), dapsone (one month), rituximab (two infusions), acitretin (two months), pentoxifylline (duration unknown), and ustekinumab (one injection). She was started on cyclosporine 3 mg/kg/d, which was increased after one week to 5 mg/kg/d. The patient had significant clinical improvement after five months of treatment under the higher dosage (**Figure 2**). The patient discontinued cyclosporine after two years of treatment and has since remained in remission.

Case Discussion

Owing to its low incidence, there are few studies regarding the management of CADM, but case reports show poor response to multiple immunosuppressive regimens [2]. In this case, our patient also had psoriasis, which further complicated treatment. Although the current literature has described several cases of psoriasis and dermatomyositis, the authors were unable to find case reports of coexisting CADM and psoriasis in an adult patient. This case is also notable for the high number of treatment failures before higher dose cyclosporine was found to be an effective therapy. The dosing of 5 mg/kg/d is twice the level indicated for cutaneous and rheumatological conditions, which typically start at 2.5 mg/kg/d.

High-dose systemic corticosteroids are considered first line treatment for dermatomyositis, with methotrexate as a first line adjuvant in non-responders. Several case reports have described

the efficacy and safety of cyclosporine in the treatment of steroid-resistant dermatomyositis [4, 5]. In contrast systemic corticosteroids are generally avoided in psoriasis owing to the potential risk of triggering pustular psoriasis upon steroid withdrawal, although a definitive link has yet to be established [6]. Cyclosporine is FDA-approved in the treatment of psoriasis, particularly for patients who are experiencing severe flares of widespread inflammatory psoriasis or who have had a poor response to other systemic therapies [7].

In this case, our patient failed ten treatment regimens before responding to cyclosporine. Cyclosporine is a calcineurin inhibitor that reduces the production of IL-2, a cytokine involved in the activation and proliferation of helper T cells and cytotoxic T cells. In addition, cyclosporine is also known to selectively inhibit T-lymphocyte production of interferon- γ (IFN) while leaving IFN- α/β levels unchanged [8, 9]. Conversely, tumor necrosis factor (TNF) inhibitors, which have been effective in the treatment of psoriasis, are also associated with clinical worsening of dermatomyositis, perhaps related to a transient increase in IFN- α/β following decreased TNF cross-regulation [8, 10]. A 2011 case series in children reported the development of psoriasis following effective treatment of juvenile dermatomyositis, as well as the inverse relationship, implying the two disease states have related but opposing roles [10]. The effectiveness of cyclosporine in this case supports a role for selective IFN- γ inhibition in the treatment of

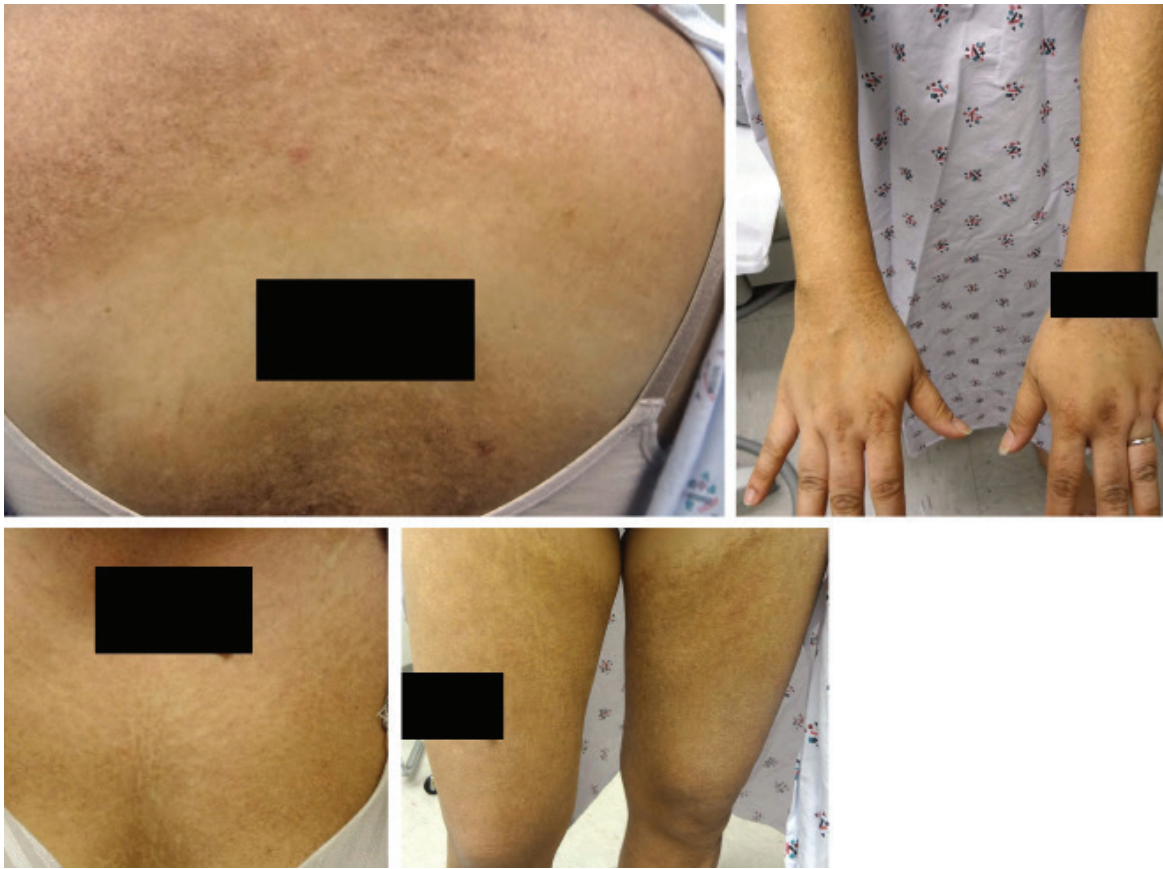


Figure 2. Following approximately five months of treatment, the patient had significant thinning and lightening of lesions. Remaining patches were consistent with post-inflammatory hyperpigmentation.

dermatomyositis. Although cyclosporine is not first line treatment for either psoriasis or dermatomyositis because of the potential for hypertension and renal toxicity, it should be considered in patients with both conditions.

Conclusion

The diagnosis of CADM can be challenging owing to its unusual presentation and relative rarity in the dermatomyositis spectrum. In an even smaller subset of patients, CADM and psoriasis can present simultaneously. The ideal form of therapy is uncertain, however, this case supports the observation that cyclosporine may provide clinical benefit to patients with refractory cutaneous lesions of both CADM and psoriasis.

References

1. Udkoff J, Cohen PR. Amyopathic Dermatomyositis: A Concise Review of Clinical Manifestations and Associated Malignancies. *Am J Clin Dermatol.* 2016;17(5):509-18. [PMID: 27256496].
2. Callander J, Robson Y, Ingram J, Piguet V. Treatment of clinically amyopathic dermatomyositis in adults: a systematic review. *Br J Dermatol.* 2016. [PMID: 27167896].
3. Krueger JG, Bowcock A. Psoriasis pathophysiology: current concepts of pathogenesis. *Ann Rheum Dis.* 2005;64 Suppl 2:ii30-6.

4. Correia O, Polónia J, Nunes JP, Resende C, Delgado L. Severe acute form of adult dermatomyositis treated with cyclosporine. *Int J Dermatol.* 1992;31(7):517-9. [PMID: 1500250].
5. Mehregan DR, Su WP. Cyclosporine treatment for dermatomyositis/polymyositis. *Cutis.* 1993;51(1):59-61. [PMID: 8419114].
6. Mrowietz U, Domm S. Systemic steroids in the treatment of psoriasis: what is fact, what is fiction? *J Eur Acad Dermatol Venereol.* 2013;27(8):1022-5. Epub 2012/07/25. [PMID: 22830601].
7. Soleymani T, Vasantachart JM, Wu JJ. Comparison of Guidelines for the Use of Cyclosporine for Psoriasis: A Critical Appraisal and Comprehensive Review. *J Drugs Dermatol.* 2016;15(3):293-301. [PMID: 26954314].
8. Oddis CV. Update on the pharmacological treatment of adult myositis. *J Intern Med.* 2016;280(1):63-74. [PMID: 27098592].
9. Kalman VK, Klimpel GR. Cyclosporin A inhibits the production of gamma interferon (IFN gamma), but does not inhibit production of virus-induced IFN alpha/beta. *Cell Immunol.* 1983;78(1):122-9. [PMID: 6406074].
10. Kim NN, Lio PA, Morgan GA, Jarvis JN, Pachman LM. Double trouble: therapeutic challenges in patients with both juvenile dermatomyositis and psoriasis. *Arch Dermatol.* 2011;147(7):831-5. [PMID: 21422326].