

UC Davis

Dermatology Online Journal

Title

Zoledronic acid-associated symmetrical drug-related intertriginous and flexural exanthema (SDRIFE): report of baboon syndrome in a woman with recurrent metastatic breast cancer after receiving zoledronic acid

Permalink

<https://escholarship.org/uc/item/5kk0g864>

Journal

Dermatology Online Journal, 21(8)

Author

Cohen, Philip R

Publication Date

2015

DOI

10.5070/D3218028425

Copyright Information

Copyright 2015 by the author(s). This work is made available under the terms of a Creative Commons Attribution-NonCommercial-NoDerivatives License, available at <https://creativecommons.org/licenses/by-nc-nd/4.0/>

Peer reviewed

Case report

Zoledronic acid-associated symmetrical drug-related intertriginous and flexural exanthema (SDRIFE): report of baboon syndrome in a woman with recurrent metastatic breast cancer after receiving zoledronic acid

Philip R Cohen MD

Dermatology Online Journal 21 (8): 2

Department of Dermatology, University of California San Diego, San Diego, California.

Correspondence:

Philip R. Cohen, MD
10991 Twinleaf Court
San Diego, CA 92131-3643
mitehead@gmail.com

Abstract

Background: Baboon syndrome is a distinctive skin reaction in which the patient typically develops erythematous buttocks that appear similar to those of a baboon. The non-contact allergenic variant of baboon syndrome is also referred to as symmetrical drug-related intertriginous and flexural exanthema (SDRIFE). Zoledronic acid is a bisphosphonate that is used in patients with metastatic cancer to prevent bone complications.

Purpose: Zoledronic acid-associated baboon syndrome is described in a woman with recurrent metastatic breast cancer.

Methods: PubMed was used to search the following terms, separately and in combination: baboon syndrome, breast cancer, symmetrical drug-related intertriginous and flexural exanthema, and zoledronic acid. All papers were reviewed and relevant manuscripts, along with their reference citations, were evaluated.

Results: Zoledronic acid has infrequently been associated with mucocutaneous adverse reactions. However, baboon syndrome has not previously been observed in patients receiving zoledronic acid. The reported woman developed baboon syndrome after her initial exposure to zoledronic acid.

Conclusions: Non-contact allergenic drug-induced baboon syndrome has most commonly been associated with antibiotics such as beta-lactams and penicillins. Zoledronic acid-associated baboon syndrome has not previously been observed in cancer patients. Baboon syndrome (SDRIFE variant) was observed in a woman with recurrent metastatic breast cancer after her first exposure to zoledronic acid. In summary, SDRIFE can occur in oncology patients receiving zoledronic acid and zoledronic acid should be added to the list of medications associated with the potential to cause non-contact allergenic drug-induced baboon syndrome.

Key Words: acid, baboon, breast, cancer, drug, exanthema, flexural, intertriginous, symmetric, symmetrical, syndrome, zoledronic

Introduction

Baboon syndrome is an uncommon, yet distinctive, cutaneous adverse drug reaction typically characterized by erythematous buttocks similar in appearance to the red gluteal region of the baboon [1]. Zoledronic acid is a bisphosphonate used in patients

with malignancy-associated bone metastases to prevent skeletal-related adverse events [2]. A woman with recurrent metastatic breast cancer who developed baboon syndrome after her initial treatment with zoledronic acid is described.

Case synopsis

A 54-year-old woman with metastatic breast cancer to her lungs and bones presented for evaluation of a new asymptomatic rash that covered several areas of her body. Her past medical history was significant for invasive mixed ductal and lobular carcinoma (grade 2, T3N3 with lymphatic vessel invasion, estrogen receptor positive, progesterone receptor negative, and HER2/neu negative) of the right breast diagnosed in 2004. She was treated with lumpectomy of the right breast, chemotherapy (adriamycin and cytoxan, followed by taxol), radiation therapy, and five years of hormonal therapy that was completed in February 2010.

In July 2014, she developed a cough. Computerized tomography of the chest revealed a left hilar mass and multiple pulmonary nodules; computerized tomography of the abdomen and pelvis revealed bone metastases. Fine needle aspirate of the lung mass was positive for adenocarcinoma (which was also estrogen receptor positive, progesterone receptor negative, and HER2/neu negative). Daily letrozole 2.5 mg was started July 31, 2014.

Treatment with zoledronic acid, to prevent complications to her bones, was initiated on Sunday, September 7, 2014; she received an intravenous infusion of 4 mg of zoledronic acid. The following morning, she noticed an asymptomatic flat red rash not only on her left antecubital fossa (which was the infusion site), but also bilaterally on her groin area and medial thighs. By Tuesday, September 9, 2014, similar lesions had appeared on her right antecubital fossa, both of her axilla, and both of her popliteal fossa.

In addition, the rash was also present on her right flank. There were no systemic symptoms, such as fever, and the affected areas were neither itchy nor painful. She had no history of previous, similar-appearing, skin lesions and her complete blood counts and serum chemistries were normal.

Cutaneous examination, on Wednesday, September 10, 2014, showed a comfortable afebrile woman with non-tender, non-pruritic erythematous patches. There had been no further progression of her skin lesions and some of the affected areas were beginning to resolve spontaneously. Bilaterally affected areas included the inguinal region and proximal medial thighs (Figure 1), the axilla (Figure 2), the antecubital fossa (Figure 3) and the popliteal fossa (Figure 4). There was also macular erythema of the right flank. There were no lesions of mucosal membranes.

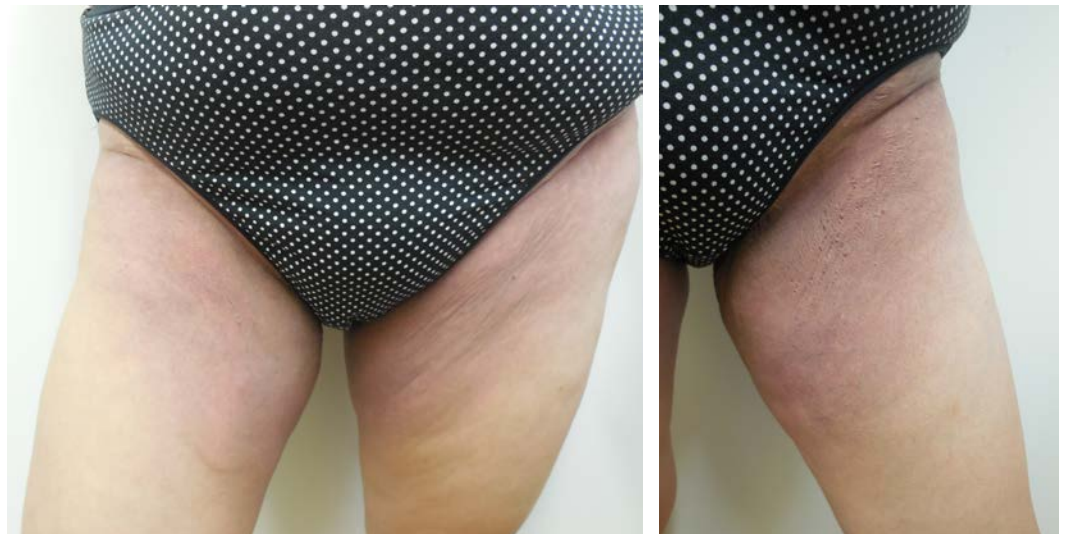

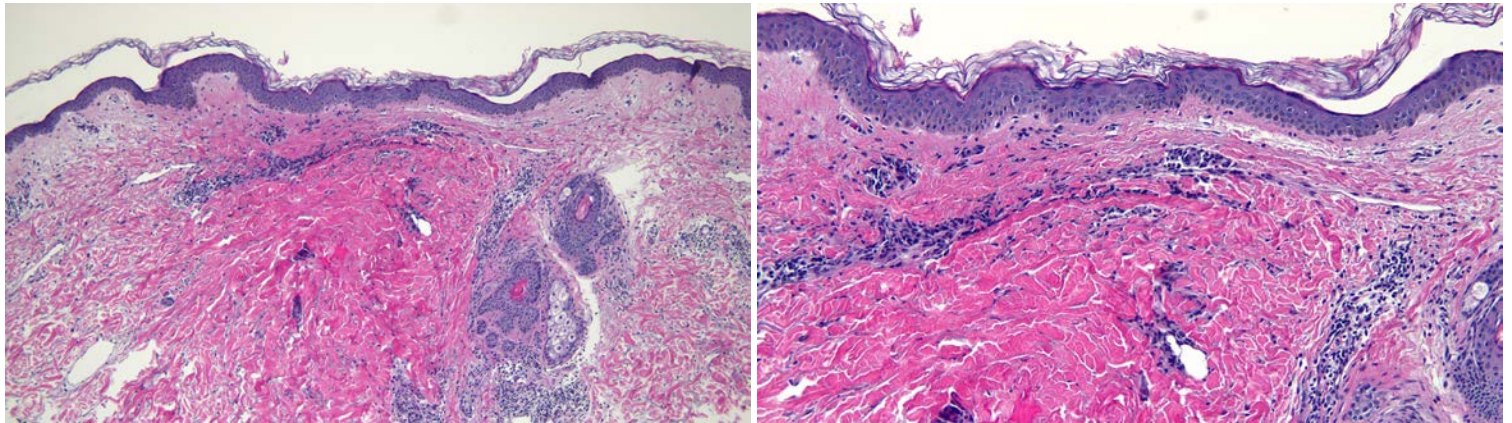
Figure 1 (a and b). Non-contact allergenic drug-induced baboon syndrome, in a 54-year-old woman with recurrent metastatic breast cancer, developed within 24 hours after receiving her first infusion of zoledronic acid. Distant (a) and closer (b) views of both (a) and left (b) inguinal regions and proximal medial thighs show asymptomatic patches of erythema.

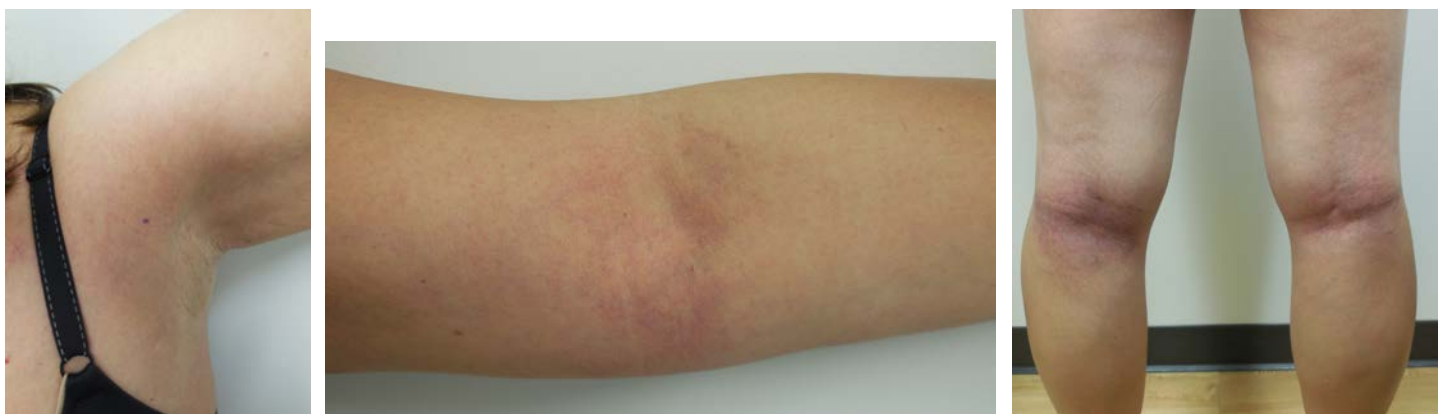

Figure 2. Asymptomatic erythematous patches of non-contact allergenic drug-induced baboon syndrome (also referred to as symmetric drug-related intertriginous and flexural exanthema or SDRIFE) on the left axilla. **Figure 3.** A close view of the left antecubital fossa shows macular

erythema of zoledronic acid-induced baboon syndrome. **Figure 4.** A distant view of the left and right popliteal fossas show symmetric macular erythema of baboon syndrome.

Microscopic examination of biopsies from the left thigh and the left axilla both showed similar changes (Figure 5). There is mild spongiosis in the overlying epidermis. In the dermis there is not only a variable superficial and deep perivascular infiltrate, but also a focal periadnexal infiltrate comprised of lymphocytes and eosinophils.



The clinical characteristics of the patient's skin lesions fulfilled all of Hausermann et al's [3] diagnostic criteria for the distinctive clinical presentation of a medication reaction described as symmetrical drug-related intertriginous and flexural exanthema (SDRIFE). The pathology findings were those of a dermal hypersensitivity reaction, consistent with a drug eruption. An association between her exposure to zoledronic acid and the onset of her skin lesions had been established. Correlation of her clinical history, lesion morphology, and biopsy pathology was consistent with the diagnosis of non-contact allergenic systemic drug-associated baboon syndrome.

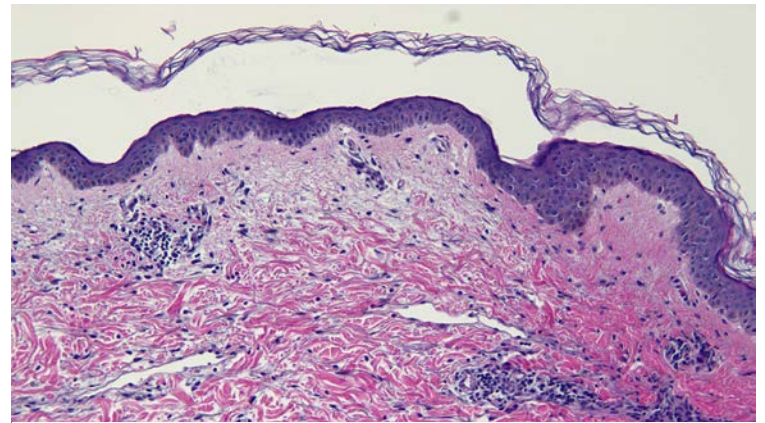


Figure 5 (a, b and c). Low and higher magnifications of a biopsy from the left thigh shows a superficial and deep perivascular, predominantly lymphocytic, infiltrate in the dermis; inflammation around a hair follicle and its associated sebaceous gland are also present [hematoxylin and eosin; a = x 10; b = x 20; c = x 20].

Conservative management, consisting only of observation, was advised since some of the asymptomatic lesions were already beginning to disappear. Within 1 week, all of her skin lesions had completely resolved. There was no recurrence of the dermatosis.

An alternative agent, denosumab, was selected in order to prevent bone complications. She initially received the drug on October 5, 2014 without any complications. There have been no adverse skin events following subsequent treatments with denosumab.

Discussion

Nakayama et al [4], during a presentation at the 6th International Symposium on Contact Dermatitis in Tokyo, Japan in March 1982, described 15 patients with an eruption labeled mercury exanthema that presented not only as a diffuse symmetric erythema predominantly on major flexural areas but also as an inverted triangular or V-shaped erythema on both upper medial thighs. The generalized rash appeared one to two days after breaking a thermometer or during dental treatment. Most of the patients had a prior history of contact dermatitis to mercurichrome and were patch test-positive to several mercurials. The investigators hypothesized that the patients developed a systemic contact dermatitis to inhalation of mercury vapor [4].

The term "baboon syndrome" was introduced by Andersen et al [5] in 1984 to describe a characteristic distribution pattern of systemic-induced allergic contact dermatitis. He and his coauthors reported 3 individuals with generalized rash that was provoked by ampicillin, nickel or mercury and recognized the similarity of their patients' eruption to that described by Nakayama et al [4]. Their designation of "baboon syndrome" refers to the dramatic and distinctive clinical appearance of the patient's buttocks that is similar to the red presentation of the corresponding area of a baboon [5-7].

Three independent investigators have subsequently proposed classifications for this cutaneous adverse drug reaction that contain various subcategories of baboon syndrome (Table 1) [3,8-10]. Baboon syndrome type 1 (according to Ozkaya's classification [9]) is referred to as classical baboon syndrome by Miyahara et al [8]; it represents contact allergen-induced baboon syndrome from agents such as balsam of Peru, mercury (dental or vapor), nickel, and poison ivy—similar to that observed by Nakayama et al [4] and Andersen et al [5]. Topical and drug induced baboon syndrome (as designated by Miyahara et al [8])—both referred to as baboon syndrome type 2 by Ozkaya [9]—corresponds to specific stages of Lachapelle's [10] concept of allergic contact dermatitis syndrome with a history of prior cutaneous sensitization: stage 3A (in which there is hematogenous dissemination of the skin lesions from the primary site of topical allergen application to distant sites) and stage 3B (in which systemic reactivation of allergic contact dermatitis results in generalized dissemination of skin lesions following systemic administration of the allergens either by ingestion, inhalation or injection), respectively [10]. Non-contact allergenic drug-induced baboon syndrome [also referred to as either baboon syndrome type 3 by Ozkaya [9] or symmetric drug-related intertriginous and flexural exanthema (SDRIFE) by Hausermann et al [3] and Miyahara et al [8]] is the most frequent variant of baboon syndrome.

Table 1. Classifications of baboon syndrome^a

	Classification		PS ^d	DI	PT ^e	CSC ^f
Miyahara et al [8] ^b	Ozkaya [9] ^c	Hausermann et al [3]				
Classical BS ^g	BS type 1: contact allergen-induced BS (excluding drugs) ^g		+	-	+/-	+/-
Topical drug-induced BS ^{h,i}	BS type 2: contact allergic drug-induced BS ^{l,j}	Stage 3A of ACDS ^l	+	+	+	+
Systemic drug-induced BS ^h	BS type 2: contact allergic drug-induced BS ^{l,k}	Stage 3B of ACDS = SRCD ^k	+	+	+	-
SDRIFE	BS type 3: non-contact allergenic drug-induced BS	SDRIFE	-	+	+/-	-

^aAbbreviations: ACDS, allergic contact dermatitis syndrome; BS, baboon syndrome; CSC, current skin contact; DI, drug induced; PS, previous sensitization; PT, patch tests; SDRIFE, symmetric drug-related intertriginous and flexural exanthema; SRCD, systemic reactivation of allergic contact dermatitis; +, present; -, absent; =, also known as.

^bMiyahara et al included 2 additional types: (1) Infection-induced dermatoses that have a BS-like pattern (common cold, parvovirus B19, and streptococcus) and (2) Dermatoses affecting the gluteal region with a BS-like pattern (erysipelas, intertrigo, and staphylococcal scalded skin syndrome).

^cOzkaya proposed the Gunes subclassification of baboon syndrome.

^dPrevious contact sensitization to the causative agent.

^eReaction to patch testing with the causative agent.

^fSkin contact with the causative agent elicits the skin lesions.

^gCausative agents: balsam of Peru, mercury (dental or vapor), nickel, and poison ivy.

^hBoth of these types represent a systemic contact dermatitis since the patients have previously been sensitized via skin contact to the offending drug. The difference between the two types is the manner of exposure to the challenging dose of the drug—either: (1) absorption of the drug from the skin or mucosal surface (topical) or (2) inhaled or intravenous or oral (systemic).

^lCausative drugs: 5-aminosalicylic acid, ampicillin, bufexamac, and cinchocaine.

^jACDS, with a previous cutaneous sensitization, has four clinical stages. Stage 3 of ACDS involves the generalized dissemination of skin lesions. In Stage 3A of ACDS, the skin lesions spread from the primary site of topical allergen application to distant sites by hematogenous dissemination. Stage 3B of ACDS occurs following systemic administration of the allergens either by ingestion, inhalation or injection.

^kIntravenous causative agent: ethlendiamine; oral causative agents include: betamethasone, cloprednol, dexamethasone, erythromycin, hydrocortisone, methylprednisolone, neomycin, nystatin, and prednisolone.

Hausermann et al [3] have proposed criteria to establish the diagnosis of baboon syndrome resulting from systemic drugs. Their criteria for SDRIFE (baboon syndrome type 3) are listed in Table 2 [3]. Antibiotics—particularly beta-lactams and penicillins—are the most common causative medications eliciting non-contact allergenic drug-induced baboon syndrome [6-8,11,12].

Table 2. Hausermann et al's diagnostic criteria for systemic drug-associated baboon syndrome [3]^{a,b}

Criteria number	Criteria description
1	Exposure to a systemic administered drug: Contact allergens excluded

	Dose: first or repeated
2	Gluteal/perianal area: Sharply demarcated erythema And/Or Inguinal/perigenital area: V-shaped erythema
3	Intertriginous/flexural fold: Involvement of at least one other area
4	Affected areas: Symmetric
5	Systemic symptoms and signs: Absent

^aHausermann et al also refer to this distinctive clinical presentation of drug eruption as symmetric drug-related intertriginous and flexural exanthema.

^bAll five criteria need to be fulfilled.

Non-contact allergenic drug-induced baboon syndrome typically presents in middle-aged men as an asymptomatic skin eruption. It usually appears within hours to a few days following exposure to the eliciting agent. Diffuse erythema appears on the underpants area (buttocks and anogenital area), the inguinal area/medial thigh, or both. In addition, there is symmetric involvement of flexural (antecubital and popliteal fossa) and intertriginous (axilla) areas. The eruption resolves spontaneously, often within 7 days to 2 weeks [8,9,11].

Microscopic examination of the affected area often shows nonspecific findings such as a superficial perivascular lymphocytic infiltrate in the dermis. However, the dermal infiltrate may contain other cells (such as eosinophils, neutrophils and/or extravasated erythrocytes). In addition, mild dermal edema or epidermal spongiosis may be present. Rarely, the pathology can mimic acute generalized pustular dermatosis, bullous drug eruptions (such as erythema multiforme and fixed drug eruption), giant cell lichenoid dermatitis, leukocytoclastic vasculitits, neutrophilic dermatosis (with subcorneal and suprabasal pustules) or pustular hemorrhagic reaction [8,9,12].

Zoledronic acid is a bisphosphonate. It is used in oncology patients—such as those with breast and prostate cancer—for the treatment and prevention of not only bone metastases but also cancer associated skeletal complications. The drug binds to hydroxyapatite of mineralized bone and inhibits osteoclast-mediated bone resorption [2,13-16].

Cutaneous adverse skin reactions to zoledronic acid are not frequent (Table 3) [13,17-24]. Conjunctivitis and hyperhidrosis have more commonly been observed [16]. Infusion site reactions have occasionally been described that include erythema, induration, irritation, pain and/or swelling [17,20,21].

Table 3. Cutaneous and mucosal adverse events in patients receiving zoledronic acid^{a,b}

Event	Description	Ref
Angioedema	Rare	17
Baboon syndrome	Single case report Non-contact allergenic drug-induced BS type 3 (also known as SDRIFE) A 54-year-old woman with metastatic breast cancer. Onset of asymptomatic symmetric erythematous macules and patches on her proximal medial thighs, axilla, and antecubital and popliteal fossa within less than 24 hours following infusion and spontaneously resolved within 7 days.	CR
Calcinosis cutis (dystrophic) and metaplastic bone formation	Single case report A 61-year-old woman developed recurrent breast cancer with bone metastases in 2003; she was treated with zoledronic acid and letrozole. She used zoledronic acid for 5 years and clodronate for 2 years. In 2010, she presented with “a rash around her previous mastectomy	18

	site and a discharge lesion on her right chest wall.” Bipsy sowed dystrophic calcification and metaplastic bone formation without any malignant cells. The lesion was excised and bisphosphonate therapy was stopped; she continued on letrozole.	
Conjunctivitis	Common	17
Dermatomyositis (drug-induced)	Single case report A 57-year-old woman with prior exposure to oral bisphosphonate therapy developed dermatomyositis (rash, myalgia, muscle weakness, elevated creatinine kinase, alanine transaminase, alkaline phosphatase, gamma glutamine transaminase and antinuclear antibody) beginning 3 days after her first infusion of zoledronic acid. Skin lesions involved her forehead (macular, violaceous with telangiectasia an atrophy), neck, upper chest, laeral thighs (macular violaceous erythema, Holster sign), and left arm (mottled violaceous patch) and periungual telangiectasias involving both hands. There was poikiloderma of the buttocks. Biopsy from the thigh revealed basal vacuolar change and a sparse lichenoid infiltrate. Telangiectasia and perivascular lymphohistiocytic infiltrate was in the superficial dermis and there was abundant dermal mucin deposition. Treatment initially consisted of prednisolone 25 mg daily; it was increased to 50 mg/d and hydroxychloroquine at 200 mg twice daily was added. Topical betamethasone dipropionate 0.05% cream was applied to the rash. Her lab abnormalities, except the elevated antinuclear antibody, resolved after 12 weeks. After 12 months, the dose of her oral medications was being weaned and there had been resolution of the rash and muscle weakness.	19
Hyperhidrosis	Common	17
Hypersensitivity reaction	Uncommon	17
Infusion (injection) site reactions	Uncommon Characterized by induration, irritation, pain, redness, and/or swelling.	17,20,21
Pruritus	Uncommon 1-10 cases per 1000 according to EMA in 2008.	17,20,21
Rash	Uncommon Includes erythematous and macular eruptions. 1-10 cases per 1000 according to EMA in 2008.	13,17,20-23
Rash associated with protracted fever	Single case report A 64-year-old woman with neglected rheumatoid arthritis receiving oral methotrexate, prednisone, folic acid, calcium and vitamin D was given zoledronic acid for osteoporosis. She experienced fever (39°C) and chills 6 hours after the infusion; the fever persisted and 10 days later she developed a pruritic confluent maculopapular rash on the medial aspects of both thighs. She was hospitalized (temperature was 38.5°C, C-reactive protein elevated at 61 mg/L and erythrocyte sedimentation rate elevated at 48 mm/h) and treated with intravenous prednisone 25 mg/d and oral laratidine 10 mg/d. The	24

	rash subsided and she was afebrile 2 days later.	
Stevens Johnson syndrome	4 patients According to the US FDA ARES in 2009	20,21
Toxic epidermal necrolysis	4 patients According to the US FDA ARES in 2009	20,21
Urticaria	Frequency unknown Adverse drug reaction reported during post marketing experience	17

aAbbreviations: ARES, adverse event reporting system; BS, baboon syndrome; CR, current report; FDA, Food and Drug Administration; EMA, European Medicines Agency; SDRIFE, symmetric drug-related intertriginous and flexural exanthema; US, United States

bDefinitions of the ranges of event incidence: common ($\geq 1/100$, $< 1/10$), uncommon ($\geq 1/1,000$, $< 1/100$), and rare ($\geq 1/10,000$, $< 1/1,000$).

Systemic corticosteroid and antihistamine-responsive protracted fever with a subsequent associated pruritic erythematous exanthema was reported in a 64-year-old woman after receiving zoledronic acid for osteoporosis [24]. In larger studies, “rash” has been observed ranging from less than 1 percent [20,21] to 5 percent [22,23] of individuals. However, neither the morphology nor the distribution of the rash is further defined [13,22,23].

To the best of our knowledge, baboon syndrome had not been described following the administration of zoledronic acid. The reported patient developed baboon syndrome within less than 24 hours after intravenously receiving her first dose of zoledronic acid; she had no prior exposure to bisphosphonates. Although her buttocks were not affected, she fulfilled all of Hausermann et al’s diagnostic criteria, including symmetric erythema of her medial thighs, for baboon syndrome (type 3 or SDRIFE variant). Her asymptomatic skin lesions continued to progress over the next day and then spontaneously resolved. She subsequently received denosumab to prevent tumor-related bone complications and did not develop any adverse cutaneous effects.

Conclusion

Baboon syndrome was initially described as a form of systemic contact dermatitis following non-drug or topical medication sensitization followed by either topical or systemic challenge with the offending agent. Subsequently, the cutaneous adverse drug reaction that has a similar morphologic presentation but does not have a prior sensitization by the causative agent was also classified as baboon syndrome. In this clinical setting, the variant is referred to as either SDRIFE or baboon syndrome type 3 (non-contact allergenic drug-induced baboon syndrome). Zoledronic acid, a bisphosphonate used to prevent bone complications in oncology patients, may occasionally result in conjunctivitis, hyperhidrosis, and infusion site reactions. However, other mucosal or cutaneous adverse events occur infrequently. A woman with recurrent metastatic breast cancer developed zoledronic acid-associated baboon syndrome (SDRIFE) after her initial exposure to the medication. Baboon syndrome (SDRIFE) should be included in the potential adverse skin reactions from zoledronic acid and zoledronic acid should be added to the medications that are potentially associated with the development of non-contact allergenic drug-induced baboon syndrome (SDRIFE).

References

1. Akkari H, Belhadjali H, Youssef M, Mokni S, Zili J: Baboon syndrome induced by hydroxyzine. *Indian J Dermatol* 2013;58(3):244. [PMID: 23723506]
2. Dhillon S, Lyseng-Williamson KA: Zoledronic acid: a review of its use in the management of bone metastases of malignancy. *Drugs* 2008;68:507-534. [PMID: 18318568]
3. Hausermann P, Harr T, Bircher AJ: Baboon syndrome resulting from systemic drugs: is there strife between SDRIFE and allergic contact dermatitis syndrome? *Contact Dermatitis* 2004;51:297-310. [PMID: 15606657]
4. Nakayama H, Niki F, Shono M, Hada S: Mercury exanthema. *Contact Dermatitis* 1983;9:411-417. PMID = 6194931
5. Andersen KE, Hjørh N, Menne T: The baboon syndrome: systemically-induced allergic contact dermatitis. *Contact Dermatitis* 1984;10:97-100. [PMID: 6232098]
6. Wolf R, Orion E, Matz H: The baboon syndrome or intertriginous drug eruption: a report of eleven cases and a second look at its pathomechanism. *Dermatol Online J* 2003;9(3):2. [PMID: 12952749]
7. Wolf R, Tuzun Y: Intertriginous drug eruption: including chemotherapy-induced intertrigo-like eruption. *Clin Dermatol*, in press.
8. Miyahara A, Kawashima H, Okubo Y, Hoshika A: A new proposal for a clinical-oriented subclassification of baboon syndrome and a review of baboon syndrome. *Asian Pac J Allergy Immunol* 2011;29:150-160. [PMID: 21980830]
9. Ozkaya E: Current understanding of baboon syndrome. *Expert Rev Dermatol* 2009;4(2):163-175. PMID = None
10. Lachapelle JM: Allergic contact dermatitis: clinical aspects. *Rev Environ Health* 2014;29:185-194. [PMID: 25241725]

11. Winnicki M, Shear NH: A systematic approach to systemic contact dermatitis and symmetric drug-related intertriginous and flexural exanthema (SDRIFE). *Am J Clin Dermatol* 2011;12:171-180. [PMID: 21469762]
12. Tan SC, Tan JW: Symmetrical drug-related intertriginous and flexural exanthema. *Clin Opin Allergy Clin Immunol* 2011;11:313-318. [PMID: 21659857]
13. Huang WW, Huang C, Liu J, Zheng HY, Lin L: Zoledronic acid as an adjuvant therapy in patients with breast cancer: a systematic review and meta-analysis. *PLoS ONE* 2012;7(7):e40783. [PMID: 22844410]
14. Valachis A, Polyzos NP, Coleman RE, Gnani M, Eidtmann H, Brufsky AM, Aft R, Tevaarwerk AJ, Swenson K, Lind P, Mauri D: Adjuvant therapy with zoledronic acid in patients with breast cancer: a systematic review and meta-analysis. *Oncologist* 2013;18:353-361. [PMID: 23404816]
15. Coleman RE, Rathbone E, Brown JE: Management of cancer treatment-induced bone loss. *Nat Rev Rheumatol* 2013;9:365-374. [PMID: 23507900]
16. Lluch A, Cueva J, Ruiz-Borrego M, Ponce J, Ferez-Fidalgo JA: Zoledronic acid in the treatment of metastatic breast cancer. *Anticancer Drugs* 2014;25:1-7. [PMID: 24100278]
17. New Zealand Data Sheet Zometa-Medsafe. Date of preparation: 21 October 2014. <http://www.medsafe.govt.nz/profs/datasheet/z/Zometaconcinf.pdf> Accessed 21 Mar 2015.
18. Tath AM, Gunduz S, Goksu SS, Arslan D, Uysal M, Bassorgun CI, Coskun HS: Dystrophic cutaneous calcification and metaplastic bone formation due to long term bisphosphonate use in breast cancer. *Case Rep Oncol Med* 2013;2013:871917. [PMID: 23956898]
19. Tong PL, Yu LL, Chan JJ: Drug-induced dermatomyositis after zoledronic acid. *Australas J Dermatol* 2012;53:e73-e75. [PMID: 23157790]
20. Musette P, Brandi ML, Cacoub P, Kaufman JM, Rizzoli R, Reginster JY: Treatment of osteoporosis: recognizing and managing cutaneous adverse reactions and drug-induced hypersensitivity. *Osteoporos Int* 2010;21:723-732. [PMID: 19921087]
21. Musette P, Kaufman JM, Rizzoli R, Cacoub P, Brandi ML, Reginster JY: Cutaneous side effects of antiosteoporosis treatments. *Ther Adv Musculoskel Dis* 2011;3:31-41. [PMID: 22870464]
22. Nakamura K, Yamada Y, Rosser CJ, Arakawa M, Zennmai K, Kato Y, Wantanabe M, Katsuda R, Tobiume M, Naruse K, Aoki S, Taki T, Saito H, Hasegawa T, Honda N: The use of zoledronic acid in Japanese men with stage D2 prostate cancer. *Oncol Lett* 2010;1:13-16. [PMID: 22966248]
23. Brufsky AM, Bosserman LD, Caradonna BR, Haley BB, Jones CM, Moore HCF, Jin L, Warsi GM, Ericson SG, Perez EA: Zoledronic acid effectively prevents aromatase inhibitor-associated bone loss in postmenopausal women with early breast cancer receiving adjuvant letrozole: Z-FAST study 36-month follow-up results. *Clin Breast Cancer* 2009;9:77-85. [PMID: 19433387]
24. Rizos EC, Milionis HJ, Elisaf MS: Fever with rash following zoledronic acid administration [letter]. *Clin Exp Rheumatol* 2006;24:455. [PMID: 16956442]