

UC Davis

Dermatology Online Journal

Title

Propranolol for infantile hemangiomas in developing countries

Permalink

<https://escholarship.org/uc/item/5hs9c24f>

Journal

Dermatology Online Journal, 23(3)

Authors

McMichael, Josette
Lawley, Leslie P

Publication Date

2017

DOI

10.5070/D3233034282

Copyright Information

Copyright 2017 by the author(s). This work is made available under the terms of a Creative Commons Attribution-NonCommercial-NoDerivatives License, available at <https://creativecommons.org/licenses/by-nc-nd/4.0/>

Peer reviewed

Propranolol for infantile hemangiomas in developing countries

Josette McMichael MD, Leslie P. Lawley MD

Affiliations: Department of Dermatology, Emory University School of Medicine, Atlanta, Georgia

Corresponding Author: Leslie P. Lawley MD, Department of Dermatology, Emory University School of Medicine, 1525 Clifton Rd NE 1st Floor, Atlanta, GA 30322, Tel. 404-778-3333 Fax. 404-778-3337, Email: leslie.lawley@emory.edu

Abstract

Background: Propranolol is the treatment of choice for complicated infantile hemangiomas (IH). However, in some locations, propranolol has not yet become standard of care. To our knowledge, until 2014, propranolol had not been used in Afghanistan to treat IH. **Objectives:** To raise further awareness that propranolol is the treatment of choice for complicated IH, suggest a propranolol induction, maintenance, and taper protocol, show an example of therapeutic success in a resource-limited country, and discuss potential challenges. **Methods:** At an academic teaching hospital in Kabul, Afghanistan, we conducted a retrospective chart review of patients treated with propranolol for IH from 2014-2015. **Results:** Seventeen patients were treated using a modified protocol based on consensus recommendations. Average age was 6.3 months (range 2.5 to 18 months). Thirteen patients had focal IH and four had large segmental facial IH. Three patients were lost to follow-up. The remaining 14 had good response and very few complications, including one patient co-managed by utilizing store-and-forward teledermatology. **Conclusions:** Patients in resource-limited countries can be managed successfully using a modified version of a propranolol induction, maintenance, and taper protocol. In developing countries where dermatologists are scarce, we suggest IH may be co-managed with primary care physicians via teledermatology.

Keywords: infantile hemangiomas, hemangioma, propranolol, treatment, beta blocker, developing countries, resource-limited

Introduction

A major shift in treatment of infantile hemangiomas (IH) occurred in 2008 with the report of remarkable response to propranolol [1]. Beta-blockers rapidly became the treatment of choice in many areas of the world for complicated IH. A 2015 large multi-center, randomized, controlled trial provided safety data that resulted in approval by the United States Food and Drug Administration and European Medicines Agency to use propranolol for IH in infants 5 weeks and older [2]. A 2016 meta-analysis on pharmacologic interventions for IH concluded that propranolol is much more efficacious than systemic corticosteroids [3].

However, in some locations, it has not yet become standard of care. In resource-limited settings, health care providers may not be aware of this treatment option, owing to lack of access to medical literature and limited interaction with the international medical community. They may advise parents to avoid propranolol because it is a "blood pressure medicine for adults." They might suggest other treatments such as high dose systemic steroids or inappropriate surgery during the proliferative phase. Alternatively, they may be informed but do not know how to manage propranolol in these infants in their context.

To our knowledge, as of 2014, propranolol had not been used in Afghanistan to treat IH. In January 2014, we started treating IH with oral propranolol in the dermatology department at an academic teaching hospital in Kabul. The objectives of this article are to 1) raise further awareness that propranolol is decidedly the treatment of choice for complicated

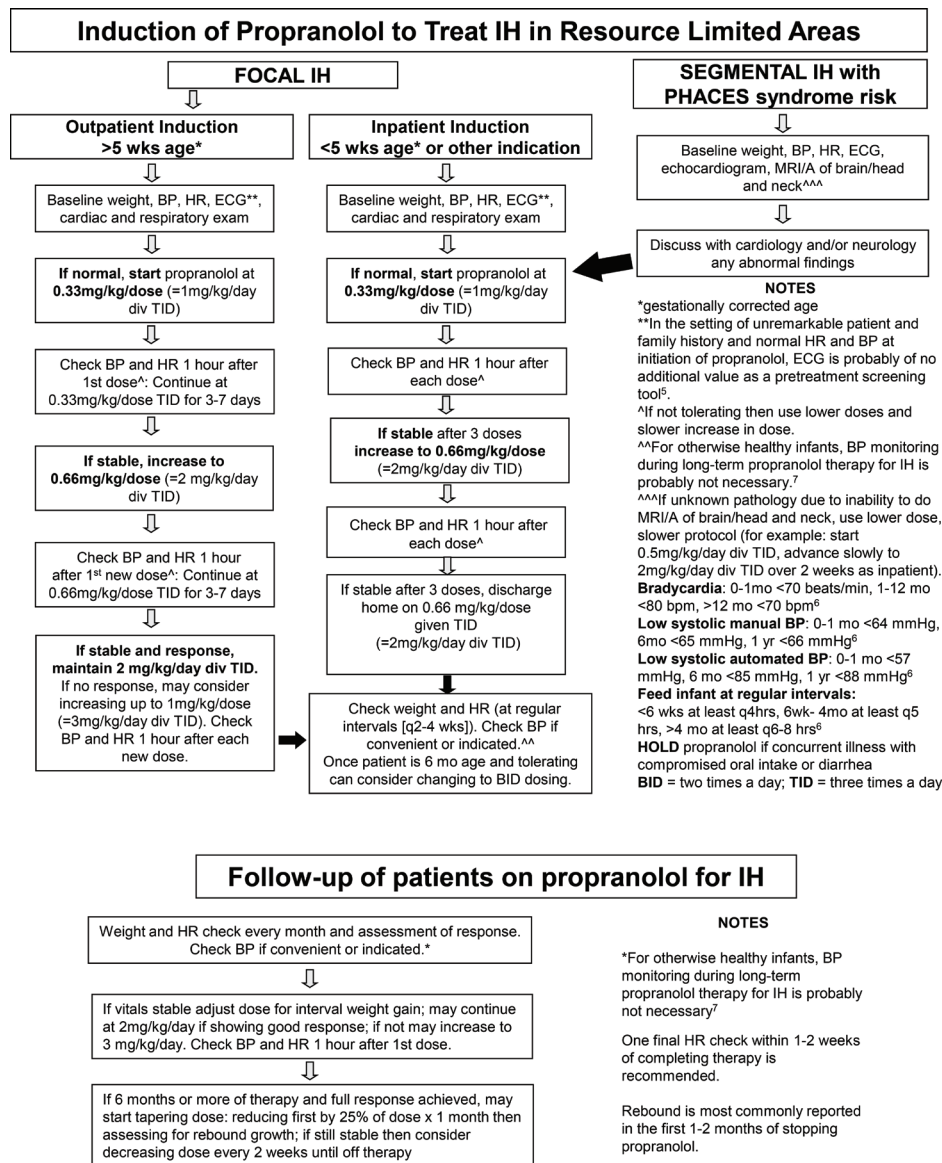


Figure 1. Induction, maintenance, and taper protocol for propranolol to treat IH in a resource-limited setting, adapted from Emory's algorithm and published recommendations regarding the safety and monitoring of infants receiving propranolol for IH [5-7].

IH; 2) suggest a propranolol induction, maintenance, and taper protocol; 3) show an example of therapeutic success in a resource-limited country; and 4) discuss potential challenges unique to this context.

Methods

This study is a retrospective chart review of the treatment of IH with propranolol in an academic teaching hospital in Kabul, Afghanistan. Institutional review board approval was not required. This chart review followed the guidelines of the Helsinki Declaration of 1975 and 1983 revisions and is in accordance with the ethical standards for human studies. We reviewed the charts of patients receiving propranolol for IH from 2014 to 2015 specifically

looking for ability to follow a standard protocol of initiation and monitoring, adjustments made to the protocol related to lack of resources, and outcomes of treatment. We also assessed whether parents had been advised previously by other health care providers to consider propranolol or other systemic treatment, or topical timolol treatment. We assessed the age at initiation of treatment and categorized the IH as focal or segmental.

Most IH do not require treatment. The indications for systemic treatment included: 1) ulceration, 2) interference with functions such as breathing, feeding, or vision, 3) involvement of cosmetically-important anatomy such as lips, nose, eyes, and

ears, 4) large or segmental IH, and 5) significant visceral hemangiomas. For small superficial IH without indication for systemic treatment, but for which parents were not content with active non-intervention, topical timolol 0.5% ophthalmic solution was prescribed twice daily to be applied to the IH [4].

The propranolol induction and maintenance protocol utilized was derived in 2010 at the Emory University Department of Dermatology in Atlanta, Georgia, United States, by one of the authors (LL) with the advice of local pediatric cardiologists. The protocol is revised periodically as substantial research has been published regarding the safety and monitoring of infants receiving propranolol for IH [5-7]. The protocol was modified for use in Afghanistan with consideration of resources (See **Figure 1**).

When syndromic IH such as PHACES (posterior fossa malformations, hemangioma, arterial anomalies, cardiac defects, eye abnormalities, and sternal defects) or LUMBAR (lower body IH and other cutaneous defects, urogenital anomalies/ulceration, myelopathy, bony deformities, anorectal malformations/arterial anomalies, and renal anomalies) was suspected, referral to a facility with MRI, echocardiography, and ECG was enacted when possible.

Results

In early 2015, a weekly hemangioma clinic was initiated to provide improved continuity of care and facilitate training of residents in IH management. Until that time, no medical records were kept on any outpatients in the dermatology department. Medical records were initiated at that time for current and new patients with IH on propranolol or topical timolol, but not for those requiring observation only.

Seventeen IH patients met criteria for systemic treatment and were started on propranolol between 2014 and 2015. We reviewed all 17 charts. All patients' parents reported that they had previously consulted multiple other doctors, and none had recommended topical timolol, oral propranolol, systemic steroids, or other systemic agents. The average age at initiation of treatment was 6.3 months (range 2.5 to 18 months), far into the proliferative phase of IH. Thirteen patients

had focal IH and four patients had large segmental facial IH. Required supplies included: 1) scale for infant weight, 2) stethoscope, 3) BP monitor with infant cuff, 4) oral propranolol tablets (liquid propranolol is not available in Afghanistan - only 10mg tablets are available at a cost of one US dollar per 50 tablets.), and, 5) a pill cutter.

Patients were prescribed propranolol 10 mg tablets divided with a pill cutter in half, fourths, or eighths, dosed by weight according to our protocol (see **Figure 1**). Of the 17 patients, one patient with segmental facial IH and two patients with focal IH were lost to follow-up. The remaining 14 patients followed up regularly and continued propranolol as recommended in the protocol with good response to the propranolol (See **Figure 2**).

For patients with large segmental facial IH, a work-up was pursued to exclude PHACES syndrome. Echocardiogram and quality infant ECG were unavailable at the institution, but these tests were available elsewhere in the city. Each patient had a normal neurologic and cardiac exam, ECG, and echocardiogram, except for one patient with patent foramen ovale, which was not a contraindication for therapy. Ophthalmology exam for one patient revealed strabismus but normal vision. All four patients were unable to afford neuroimaging which is a typical barrier to published recommended evaluation for patients in Afghanistan. Of note, fellowship-trained cardiologists and neurologists were not available in the country.

Since patients could not be fully assessed for associated vascular anomalies and risk of PHACES and stroke, a conservative initiation and titration modification of the protocol was used for these four patients by starting low dose propranolol at 0.5mg/kg/day divided (div) TID and increasing to 2mg/kg/day div TID more slowly, monitoring as inpatient for two weeks [8]. Three of the four had travelled long distances from other provinces. One of these was lost to follow-up after inpatient induction. The other patients continued to follow-up regularly with good response to the propranolol and no complications (see **Figure 2**).

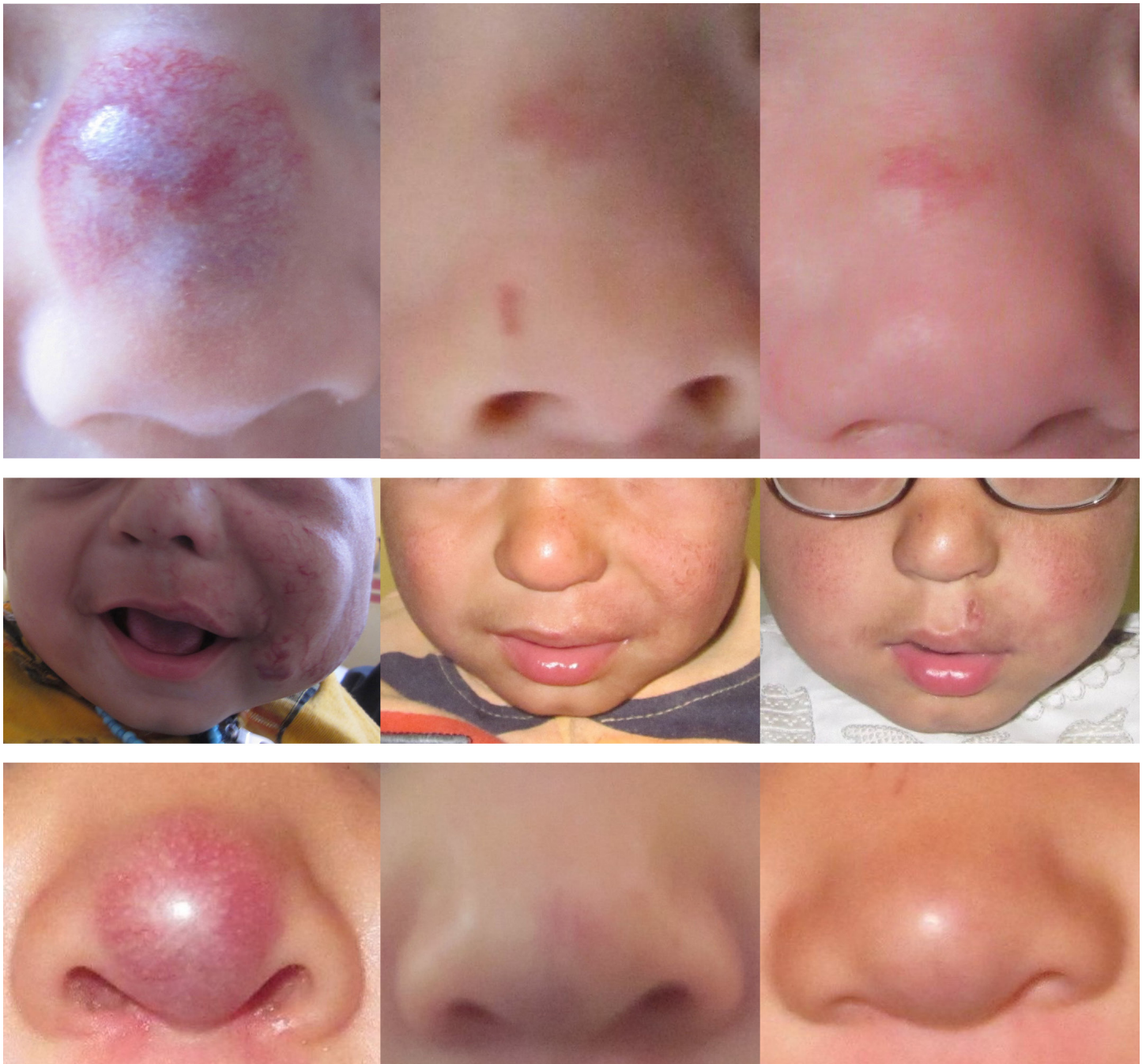

Figure 2. Three patients in the study at initiation of propranolol treatment and during treatment; the top patient was managed through teledermatology.

Additionally, six patients with small focal IH were started on topical timolol between 2014 and 2015. All had good response and no reported complications.

Given that many patients' mothers are minimally literate, verbal patient education was provided rather than written instructions.

One of the propranolol patients, a premature twin with three focal IH, was successfully co-managed utilizing store-and-forward teledermatology. This

patient and her mother travelled from a remote province for admission to the hospital for propranolol induction. Propranolol was slowly increased to 2mg/kg/day and the patient was discharged after one week. She returned home and has been followed regularly by a primary care physician who emails monthly photos, weight, BP, and heart rate (HR) for review and recommendations on continued therapy. Her only complication was a small ulceration of one hemangioma which healed with gentian violet and petroleum jelly (Vaseline®).

Very few other complications occurred. One patient with focal IH had a borderline low BP on propranolol 1mg/kg/day and was therefore maintained on 0.5mg/kg/day for a week before increasing the dose. Subsequent BPs were normal. Later in her treatment, her mother reported a persistent cough that was suspicious for bronchospasm in the absence of any other symptoms. The cough resolved by decreasing her dose by one-third. One baby initially had mild sleep disturbance but did not need to stop treatment.

Discussion

Treatment of IH in resource-limited settings presents several unique challenges, many of which we have experienced. Patients often have advanced presentations well into the proliferative phase of IH, particularly if they are from rural areas or remote provinces. Travel is difficult and parents may first try various topical remedies and other complimentary treatments recommended by traditional healers. As with our patients, parents may seek treatment from physicians who are either not aware that propranolol is a treatment option or do not feel comfortable initiating propranolol treatment in these young patients.

Liquid propranolol may not be available. Propranolol 10 mg tablets can be divided with a pill cutter. We have been unable to find pill cutters locally for parental use at home. Therefore, we divide the tablets with our own department pill cutter. Future plans include partnering with a local pharmacist to procure pill cutters from India. Dividing tablets ourselves, although time-consuming, has ensured that patients receive an accurate dose. Division of tablets into fourths, or even eighths for low-weight infants, takes precision and patience.

Furthermore, parents may be uneducated and non-literate, making patient education difficult. Follow-up is challenging especially when families travel from distant locations; some are lost to follow-up. If substantial numbers of IH patients are being followed, a weekly dedicated hemangioma clinic may help improve continuity of care.

Although sometimes needed, consultation with fellowship-trained cardiologists and neurologists may not be available. Additionally, it may be hard to

obtain a good quality ECG for an infant. Thankfully, ECGs may not be necessary for most patients anymore [5]. In recent years protocols have been simplified, making them easier to utilize in resource-limited settings. For example, most protocols have dispensed with routine baseline electrocardiogram (ECG) and glucose monitoring [5, 6]. A 2015 study suggested that for otherwise healthy infants, blood pressure (BP) monitoring during long-term propranolol therapy for IH is probably not necessary [7].

Conclusion

Despite potential challenges in treating IH with propranolol in resource-limited countries, we have shown that patients can be managed successfully using a modified version of a protocol for initiation and monitoring of the medication with consideration of consensus recommendations (**Figure 1**) [6]. In developing countries where dermatologists are scarce, particularly outside major cities, we suggest IH may be co-managed with primary care physicians via store-and-forward teledermatology. Recent studies suggest some of the previously recommended monitoring may not be necessary easing the use of beta-blockers for IH [5-7].

Acknowledgements

We gratefully appreciate the assistance of the dermatology faculty, staff, and residents in Kabul, Afghanistan who participated in the evaluation and management of patients in this study.

References

1. Léauté-Labrèze C, Dumas de la Roque E, Hubiche T, Boralevi F, Thambo JB, Taïeb A. [Letter] Propranolol for severe hemangiomas of infancy. *N Engl J Med*. 2008;358:2649-2651. [PMID: 18550886]
2. Léauté-Labrèze C, Hoeger P, Mazereeuw-Hautier J, Guibaud L, Baselga E, Posiunas G, Phillips RJ, Caceres H, Lopez Gutierrez JC, Ballona R, Friedlander SF, Powell J, Perek D, Metz B, Barbarot S, Maruani A, Szalai ZZ, Krol A, Boccara O, Foelster-Holst R, Febrer Bosch MI, Su J, Buckova H, Torrelo A, Cambazard F, Grantzow R, Wargon O, Wyrzykowski D, Roessler J, Bernabeu-Wittel J, Valencia AM, Przewratil P, Glick S, Pope E, Birchall N, Benjamin L, Mancini AJ, Vabres P, Souteyrand P, Frieden IJ, Berul CI, Mehta CR, Prey S, Boralevi F, Morgan CC, Heritier S, Delarue A, Voisard JJ et al. A randomized controlled trial of oral propranolol in infantile hemangioma. *N Engl J Med*. 2015 Feb 19;372(8):735-46. [PMID: 25693013]
3. Chinnadurai S, Fannesbeck C, Snyder KM, Sathe NA, Morad A, Likis FE, McPheeters ML. Pharmacologic Interventions for Infantile Hemangioma: A Meta-analysis. *Pediatrics*. 2016 Feb;137(2):e20153896. [PMID: 26772662]
4. Chan H, McKay C, Adams S, Wargon O. RCT of timolol maleate gel for superficial infantile hemangiomas in 5- to 24-week-olds.

- Pediatrics. 2013 Jun;131(6):e1739-47. [PMID: 23650294]
5. Raphael MF, Breugem CC, Vlasveld FA, de Graaf M, Slieker MG, Pasmans SG, Breur JM. Is cardiovascular evaluation necessary prior to and during beta-blocker therapy for infantile hemangiomas?: A cohort study. *J Am Acad Dermatol*. 2015 Mar;72(3):465-72. [PMID: 25592625]
 6. Drolet BA, Frommelt PC, Chamlin SL, Haggstrom A, Bauman NM, Chiu YE, Chun RH, Garzon MC, Holland KE, Liberman L, MacLellan-Tobert S, Mancini AJ, Metry D, Puttgen KB, Seefeldt M, Sidbury R, Ward KM, Blei F, Baselga E, Cassidy L, Darrow DH, Joachim S, Kwon EK, Martin K, Perkins J, Siegel DH, Boucek RJ, Frieden IJ. Initiation and use of propranolol for infantile hemangioma: report of a consensus conference. *Pediatrics*. 2013 Jan;131(1):128-40. [PMID: 23266923]
 7. Hengst M, Oelert M, Hoeger PH. Blood pressure monitoring during the induction and maintenance period of propranolol therapy for complicated infantile hemangiomas: a prospective study of 109 infants. *Pediatr Dermatol*. 2015 Nov; 32(6): 802-7. [PMID: 26391729]
 8. Metry D, Frieden IJ, Hess C, Siegel D, Maheshwari M, Baselga E, Chamlin S, Garzon M, Mancini AJ, Powell J, Drolet BA. Propranolol use in PHACE syndrome with cervical and intracranial arterial anomalies: collective experience in 32 infants. *Pediatr Dermatol*. 2013 Jan-Feb;30(1):71-89. [PMID: 22994362]