

UC Davis

Dermatology Online Journal

Title

Acquired unilateral facial melanocytosis: nevus of Sun

Permalink

<https://escholarship.org/uc/item/4gb0c51q>

Journal

Dermatology Online Journal, 27(6)

Authors

Nazzaro, Gianluca
Bortoluzzi, Paolo
Giacalone, Serena
et al.

Publication Date

2021

DOI

10.5070/D327654061

Copyright Information

Copyright 2021 by the author(s). This work is made available under the terms of a Creative Commons Attribution-NonCommercial-NoDerivatives License, available at <https://creativecommons.org/licenses/by-nc-nd/4.0/>

Peer reviewed

Acquired unilateral facial melanocytosis: nevus of Sun

Gianluca Nazzaro¹ MD, Paolo Bortoluzzi² MD, Serena Giacalone² MD, and Stefano Veraldi¹ MD

Affiliations: ¹Department of Pathophysiology and Transplantation, IRCCS Foundation, Cà Granda Maggiore Hospital Polyclinic, Milan, Italy, ²Dermatology Unit, Department of Pathophysiology and Transplantation, IRCCS Foundation, Cà Granda Maggiore Hospital Polyclinic, Milan, Italy

Corresponding Author: Paolo Bortoluzzi, Dermatology Unit, Department of Pathophysiology and Transplantation, IRCCS Foundation, Cà Granda Maggiore Hospital Polyclinic, Via Pace n° 9, 20122, Milan (MI), Italy, Tel: 39-3494182187, Email: paolobortoluzzi.1@gmail.com

Abstract

Acquired dermal melanocytoses include pigmented lesions with a clear late onset, histologically characterized by the presence of melanocytes in the dermis. In this report, we describe a rare case of acquired unilateral facial melanocytosis, also called nevus of Sun, in a Caucasian woman.

Keywords: dermal melanocytosis, acquired dermal melanocytosis, nevus of Sun

Introduction

Dermal melanocytoses include pigmented lesions histologically characterized by the presence of melanocytes in the dermis. They appear as gray or blue-gray in color and can be distinguished based on the time of onset and body location. Examples of congenital melanocytosis or occurring at an early age are: 1) common melanocytosis located in the lumbosacral area; 2) the nevus of Ota, usually one-sided, which is arranged along the first two branches of the trigeminal nerve; and 3) Ito nevus localized to the acromioclavicular region. Although the common melanocytosis of the lumbosacral area often regresses spontaneously during childhood, the nevi of Ota and Ito are usually permanent [1].

There is also a rare group of dermal melanocytosis with a clear late onset. Although the etiology of these lesions has not yet been established, it is believed that during embryological development some melanocytes, while migrating from the neural crest, do not reach their final location in the basal layer of the epidermis. As a result, inflammatory states, local

trauma, or sex hormones could activate them in later years [2]. Furthermore, genetic factors seem to be implicated owing to the greater incidence among subjects of Asian origin. Herein, it is reported a rare case of acquired dermal melanocytosis in a Caucasian woman.

Case Synopsis

A 50-year-old woman presented to our department for the presence of a pigmented lesion in the right temporal region. She reported that this lesion had appeared about 5 years earlier and that for some months it had been increasing in size (**Figure 1**).

Among the diagnoses we had considered an atypical common melanocytosis, drug pigmentation, melasma, and Addison disease; a biopsy was performed for histopathological examination.

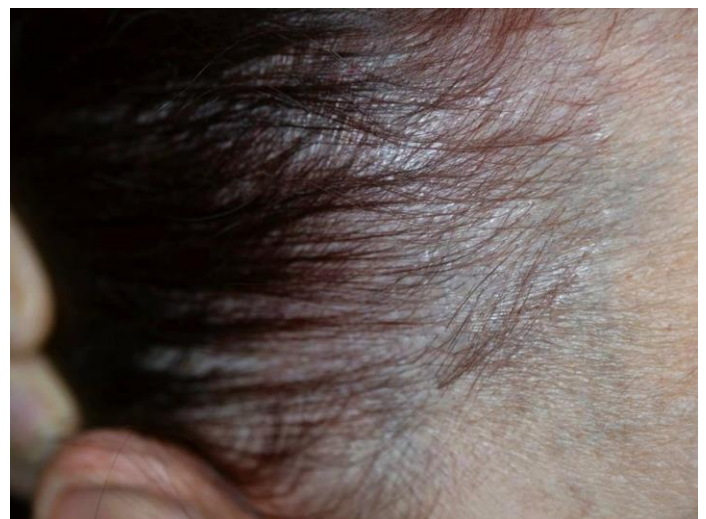


Figure 1. Nevus of Sun: on the fronto-temporal region, blue-gray macula with an adult onset.

Low magnification showed normal findings, with slight vasodilatation, whereas at greater magnification there were numerous dendritic melanocytes among the collagen bundles, especially in the reticular dermis (**Figure 2A**) and at the border with the subcutis (**Figure 2B**).

The diagnosis thus formulated was of acquired dermal melanocytosis. In particular, because of the unilaterality, nevus of Sun appeared to be the best diagnosis.

Case Discussion

In 1984, Hori described acquired dermal melanocytosis in 22 subjects [3]. These were bilateral maculae similar to nevus of Ota. These lesions, now known as Hori nevus, appear during the third or fourth decade, especially in Asian women. They are macules with a variable color ranging from blue to brown and localized to the face. Hori remarked that they were very similar to the nevus of Ota but without being observable in the oral and ocular mucosa.

The nevus of Sun, or unilateral acquired dermal melanocytosis, was described by Chee-Ching Sun in

1987 [4]. Even the nevus of Sun does not involve the mucous membranes. According to Sun data, prevalence is in favor of female subjects (12:1), of Asian origin, with a marked family tendency. Clinically and histologically, these lesions are indistinguishable from the corresponding congenital dermal melanocytosis. They tend to become clearer and greyish with the passing of the years. However, they can darken with chronic exposure to the sun and in association with hormonal stimuli such as pregnancy or menstruation.

In 1991 Whitmore described a unilateral nevus of Ota in a 42-year-old Caucasian woman [5]. This nevus is now known as nevus of Sun, although this eponym [6] is not widely known. The case herein presented is unusual because dermal melanocytoses are rare in Caucasian patients and acquired variants are exceedingly uncommon. In fact, the case we presented is the second described in a Caucasian individual, to the best of our knowledge, after the one by Whitmore.

Spontaneous regression or malignant transformation have never been described in acquired dermal melanocytoses and they are not associated with any systemic disease. In the literature specific therapies for acquired dermal melanocytosis are not indicated. An approach with depigmenting agents can be attempted, but the patient should certainly be informed about the benign nature of the lesion.

Conclusion

Dermal melanocytoses are rare lesions in Caucasian patients and acquired variants are exceedingly uncommon. The nevus of Sun is a unilateral acquired dermal melanocytosis and it can darken with chronic sun exposure or in relation to hormonal stimuli but malignant transformation has never been described.

Potential conflicts of interest

The authors declare no conflicts of interest.

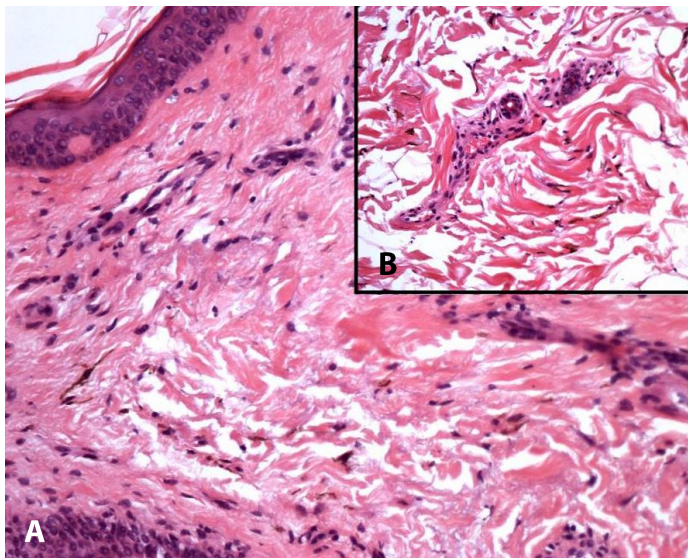


Figure 2. H&E histopathology. **A)** Nevus of Sun: dendritic melanocytes among the collagen bundles in the reticular dermis, 200x, and **B)** deeper at the border with the subcutis, 400x.

References

1. Stanford DG, Georgouras KE. Dermal melanocytosis: a clinical spectrum *Australas J Dermatol* 1996;37:19-25. [PMID: 8936066].
2. Mataix J, Lopez N, Haro R, Gonzalez E, Angulo J, Requena L, Late-onset Ito's nevus: an uncommon acquired dermal melanocytosis *J Cutan Pathol* 2007;34:640-643. [PMID: 17640235].
3. Hori Y, Kawashima M, Oohara K, Kukita A. Acquired, bilateral nevus of Ota-like macules *J Am Acad Dermatol* 1984;10:961-964. [PMID: 6736340].
4. Sun CC, Lu YC, Lee EF, et al. Naevus fusco-caeruleus zygomaticus *Br J Dermatol* 1987;117:545-553. [PMID: 3689676].
5. Whitemore SE, Wilson BB, Copper PII. Late-onset nevus of Ota *Cutis* 1991;48: 213-216. [PMID: 1935251].
6. Vaira F, Nazzaro G, Crosti C, Veraldi S. The men or women behind nevi: Alfred Guido Miescher *JAMA Dermatol* 2014;150:411. [PMID: 24718430].