

# UC Davis

## Dermatology Online Journal

### Title

Primary livedoid vasculopathy associated with mononeuritis multiplex

### Permalink

<https://escholarship.org/uc/item/4c80g04v>

### Journal

Dermatology Online Journal, 26(7)

### Authors

Krueger, Steven  
McLean, Riley  
Amano, Shinya  
[et al.](#)

### Publication Date

2020

### DOI

10.5070/D3267049556

### Copyright Information

Copyright 2020 by the author(s). This work is made available under the terms of a Creative Commons Attribution-NonCommercial-NoDerivatives License, available at <https://creativecommons.org/licenses/by-nc-nd/4.0/>

Peer reviewed

# Primary livedoid vasculopathy associated with mononeuritis multiplex

Steven Krueger<sup>1</sup> MD, Riley McLean<sup>1</sup> MD, Shinya Amano<sup>1</sup> MD PhD, Leah Belazarian<sup>1,2</sup> MD

Affiliations: Department of Dermatology, University of Massachusetts Medical School, Worcester, Massachusetts, USA,

<sup>2</sup>Department of Pediatrics, University of Massachusetts Medical School, Worcester, Massachusetts, USA

Corresponding Author: Leah Belazarian MD, 281 Lincoln Street, Worcester, MA 01605, Tel: 508-334-5979, Fax: 508-334-5981, [Leah.Belazarian@umassmemorial.org](mailto:Leah.Belazarian@umassmemorial.org)

## Abstract

A 40-year-old woman presented with painful ulcerations on the bilateral lower extremities. A biopsy confirmed the diagnosis of livedoid vasculopathy (LV). She was treated initially with aspirin and pentoxifylline, and with the addition of dipyridamole she has had no recurrence of her ulcerations to date. Despite this positive response to treatment she reported numbness and paresthesias in her legs. Nerve conduction studies confirmed a diagnosis of mononeuritis multiplex. This case highlights mononeuritis multiplex as a rarely described complication of LV, and suggests that early recognition of symptoms and a multidisciplinary approach are necessary for optimal management of this condition.

*Keywords: livedoid vasculopathy, vascular occlusion, neuropathy, mononeuritis multiplex*

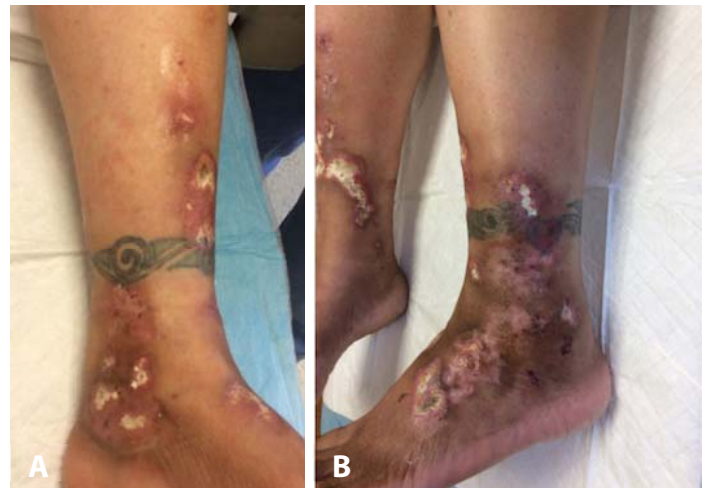## Introduction

Livedoid vasculopathy (LV) is a chronic, relapsing-remitting ulcerative disease of the lower extremities that predominantly affects middle-aged women. Although LV was once considered a form of vasculitis, there is increasing evidence that the cutaneous manifestations are related to vascular occlusion from thrombus formation rather than primary inflammation. We present an uncommon neurologic manifestation of this cutaneous disease that has rarely been reported in the dermatology literature. It is important that dermatologists recognize these neurologic symptoms early in the

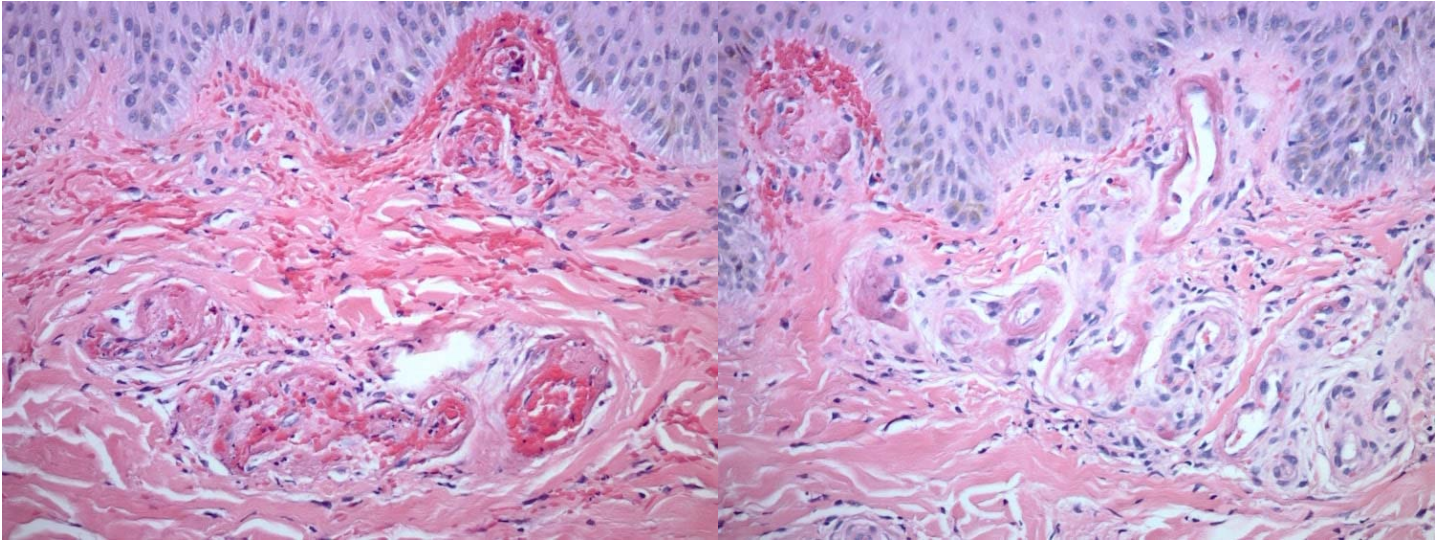
course of the disease to appropriately manage this condition.

## Case Synopsis

A 40-year-old woman presented to a local dermatologist with painful, stellate ulcerations on the bilateral lower extremities (**Figure 1**). After failing treatments with antibiotics and prednisone, a punch biopsy was performed. The initial differential diagnosis was broad and included conditions characterized by vascular occlusion, such as inherited coagulopathies, platelet-related thrombopathies, hematologic malignancies, cryoglobulinemia, cryofibrinogenemia, infectious diseases, embolization, and immune-mediated vasculitides, as well as other common causes of leg ulcers, such as arterial disease, diabetes, neoplasms, vascular proliferations, and medications.



**Figure 1.** At the time of presentation, the patient had multiple, stellate ulcerated plaques on the bilateral lower extremities.

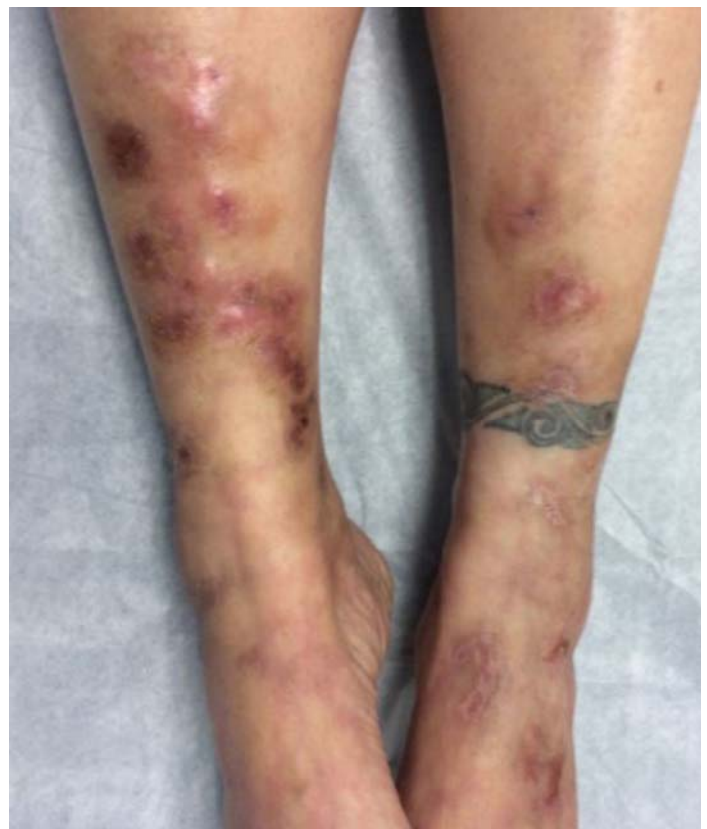

**Figure 2.** Biopsy of left lateral ankle showing hyalinization of superficial and deep dermal blood vessels, fibrin thrombi in vessel lumens, focal tissue hemorrhage, and a mild perivascular lymphocytic infiltrate. H&E, 20x.

The patient was referred to the rheumatology department and the results of the following laboratory studies were either normal, negative, or unremarkable: protein C and S, antithrombin III antigen, lupus anticoagulant, beta-2 glycoprotein, cardiolipin antibody, antinuclear antibody, rheumatoid factor, antineutrophil cytoplasmic antibody, C1, C3, and C4 complement levels, hepatitis panel, cryoglobulins, cryofibrinogens, prothrombin G20210A mutation, methylene tetrahydrofolate reductase mutation, erythrocyte sedimentation rate, C-reactive protein, serum protein electrophoresis, hemoglobin A1C, complete blood count with differential, comprehensive metabolic panel, and urinalysis.

The patient was then referred to our dermatology practice, where review of her original biopsy showed hyalinization of superficial and deep dermal blood vessels, fibrin thrombi in vessel lumens, focal tissue hemorrhage, and a mild perivascular lymphocytic infiltrate (**Figure 2**). These features were consistent with a thrombotic vasculopathy rather than true vasculitis. Given the clinical presentation of painful persistent ulcerations over the malleoli combined with these histopathologic findings and a negative laboratory work-up, the patient was diagnosed with primary livedoid vasculopathy (LV). Treatment was begun according to the therapeutic ladder previously set forth in the literature [1, 2]. She

continued to have periodic ulcerations despite treatment with aspirin and pentoxifylline. With the addition of dipyridamole, her skin lesions healed with atrophic scars and she has not had any new ulcerations for well over one year (**Figure 3**).



**Figure 3** Four months after instituting aspirin, pentoxifylline, and dipyridamole, the patient's leg wounds healed with atrophic scars.



As the patient's skin lesions resolved, she continued to complain of numbness, tingling, and burning pain in her legs that was distinct from the pain related to her ulcers. She was referred by her primary care provider for a vascular surgery consultation and had no evidence of hemodynamically significant arterial occlusive disease. As her symptoms seemed neuropathic in nature, she was seen by a neurologist and found to have diminished Achilles reflexes bilaterally. An electromyogram with nerve conduction studies showed unobtainable evoked potentials in her right superficial peroneal and left sural nerves. She was diagnosed with mononeuritis multiplex of the bilateral sural, posterior tibial, and peroneal nerves, likely associated with LV. The patient was treated with varying combinations of tramadol, acetaminophen, gabapentin, sertraline, pregabalin, hydrocodone-acetaminophen, magnesium oxide, amitriptyline, compounded topical analgesic gels, and lidocaine patches. To date, she reports moderate relief of her symptoms with gabapentin and uses lidocaine patches as needed for flares.

## Case Discussion

Although LV is a well-known condition, associated peripheral neuropathy is a rarely described potential sequela of the disease. Only 7 cases of associated neuropathy have been reported in the dermatology literature to our knowledge and 21 cases have been reported overall [3-10]. Of the cases reported in dermatology journals, 5 did not include nerve biopsy data or nerve conduction studies [3-6]. Patients suffering with neurologic involvement typically complain of sensory symptoms, such as numbness, tingling, or loss of pinprick and light-touch sensitivity, which can occur before or after the onset of skin lesions [7, 8]. A clinical neurological examination will often be abnormal [9]. These signs and symptoms tend to fit the criteria for a diagnosis of mononeuritis multiplex, or a pattern of peripheral neuropathy characterized by multifocal damage to two or more different nerves [8].

Mononeuritis multiplex can be associated with several other systemic disorders such as diabetes, connective tissue disease, vasculitis, amyloidosis,

cryoglobulinemia, sarcoidosis, neoplasms, and infections [8]. The diagnosis can be confirmed with electrophysiological testing and/or a nerve biopsy. In patients with neuropathic symptoms in the setting of LV, nerve conduction studies typically reveal diminished or absent sensory nerve action potentials, as was seen in our patient [7, 9]. Nerve biopsy samples from patients with LV-related mononeuritis multiplex reveal endoneurial capillary ectasia and congestion with hemorrhage, as well as extensive infarct of the peripheral nerve and Schwann cells leading to axonal loss. There are scattered perivascular CD3+ lymphocytes infiltrating the arterioles in the epineurium, without clear signs of vasculitis [7, 10]. These nerve biopsy findings can be interpreted as the product of ischemia from vascular thrombosis of the vasa nervorum rather than a vasculitic peripheral neuropathy [7, 8, 10]. The same alterations of the vasculature are present in both nerve and skin biopsies, strongly suggesting a common mechanism leading to ischemic damage in each tissue [8, 10]. It is therefore conceivable that restoration of normal blood flow in patients with LV may reduce potential long-term effects on the nervous system. A multidisciplinary approach using targeted antithrombotic therapies may halt the progression to permanent nerve damage in addition to new skin ulcerations. Our patient's skin lesions appear to have responded well to combination therapy with aspirin, pentoxifylline, and dipyridamole.

## Conclusion

Based on the paucity of reports in the literature, peripheral neuropathy may be rare in patients diagnosed with LV. Nevertheless, those who present with persistent or progressive numbness, weakness, or burning pain should be promptly referred for formal neurological assessment [9]. It is important that dermatologists recognize this complication early in the course of the disease so that it can be managed appropriately.

## Potential conflicts of interest

The authors declare no conflicts of interests.

## References

1. Callen JP. Livedoid vasculopathy: what it is and how the patient should be evaluated and treated. *Arch Dermatol* 2006;142:1481–1482. [PMID: 17116840].
2. Micieli R, Alavi A. Treatment for Livedoid Vasculopathy: A Systematic Review. *JAMA Dermatol.* 2018;154:193–202. [PMID: 29141075].
3. Bard JW, Winkelmann RK. Livedo vasculitis. Segmental hyalinizing vasculitis of the dermis. *Arch Dermatol* 1967;96:489–499. [PMID: 6054223].
4. Tran MD, Becherel PA, Cordel N, Piette JC, Frances C. "Idiopathic" white atrophy. *Ann Dermatol Venereol* 2001;128:1003–1007. [PMID: 11907958].
5. Hairston BR, Davis MDP, Pittelkow MR, Ahmed I. Livedoid vasculopathy: further evidence for procoagulant pathogenesis. *Arch Dermatol.* 2006;142:1413–1418. [PMID: 17116831].
6. Osada S, Kimura Y, Kawana S. Case of livedoid vasculopathy with peripheral neuropathy successfully treated with low-dose warfarin. *J Dermatol* 2010;37:98–101. [PMID: 20175830].
7. Toth C, Trotter M, Clark A, Zochodne D. Mononeuropathy multiplex in association with livedoid vasculitis. *Muscle Nerve* 2003;28:634–639. [PMID: 14571469].
8. Malaguti MC, Cavallaro T, Speziali L, et al. Mononeuritis multiplex associated with primary livedoid vasculopathy: neuropathological evidence of ischemic nerve damage. *J Neurol Sci.* 2015;351:214–5. [PMID: 25798525].
9. Gan EY, Tang MB, Tan SH, Chua SH, Tan AW. A ten-year retrospective study on livedo vasculopathy in Asian patients. *Ann Acad Med Singapore* 2012;41:400–6. [PMID: 23052434].
10. Allenbach Y, Tourte M, Stenzel W, et al. Expanding the spectrum of livedoid vasculopathy: peculiar neuromuscular manifestations. *Neuropathol Appl Neurobiol.* 2015;41:849–52. [PMID: 25871345].