

# UC Davis

## Dermatology Online Journal

### Title

Regorafenib- associated panniculitis

### Permalink

<https://escholarship.org/uc/item/4880v60z>

### Journal

Dermatology Online Journal, 22(6)

### Authors

Chockalingam, Ramya  
Aung, Phyu  
Patel, Anisha B

### Publication Date

2016

### DOI

10.5070/D3226031324

### Copyright Information

Copyright 2016 by the author(s). This work is made available under the terms of a Creative Commons Attribution-NonCommercial-NoDerivatives License, available at <https://creativecommons.org/licenses/by-nc-nd/4.0/>

Peer reviewed

**Case presentation**

**Regorafenib- associated panniculitis**

**Ramya Chockalingam BA<sup>1</sup>, Phyu Aung MD, PhD<sup>2</sup>, Anisha B. Patel MD<sup>3</sup>**

**Dermatology Online Journal 22 (6): 12**

**<sup>1</sup>The University of Texas Medical School at Houston**

**<sup>2</sup>Department of Pathology, University of Texas MD Anderson Cancer Center**

**<sup>3</sup>Department of Dermatology, University of Texas Medical School at Houston and MD Anderson Cancer Center**

**Correspondence:**

Anisha B. Patel, MD  
Department of Dermatology  
UT MD Anderson Cancer Center  
1515 Holcombe Blvd, Unit 1452, Houston, TX 77030  
Tel. (713) 745-1113  
Email: apatel11@mdanderson.org

---

**Abstract:**

Regorafenib is a second-generation multikinase inhibitor that is approved for the treatment of metastatic colon cancer and advanced gastrointestinal stromal tumors. Hand-foot skin reaction, alopecia, and oral mucositis are well-established side effects of this medication. Herein, we discuss a 60-year-old woman who developed a lobular and septal granulomatous panniculitis after six months of therapy with regorafenib. Biopsy demonstrated focal lobular and septal granulomatous inflammation admixed with septal fibrosis and lobular lymphohistiocytic infiltrate associated with fat necrosis. To our knowledge, regorafenib-induced panniculitis has not been previously described. Increased awareness of this presentation can facilitate more timely diagnosis and treatment.

**Key words: panniculitis, erythema nodosum, regorafenib, sorafenib, sunitinib, multikinase inhibitors**

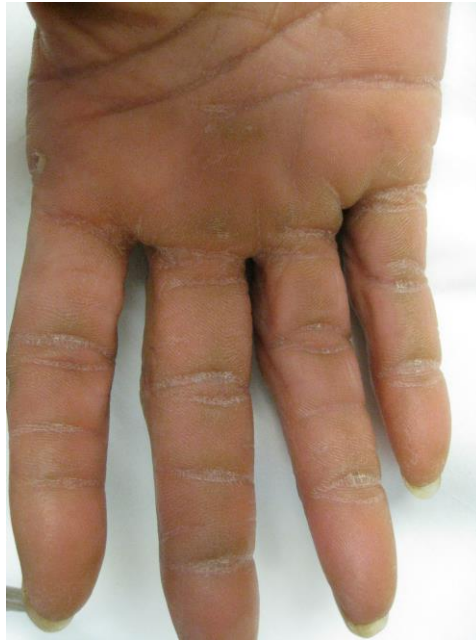**Introduction**

Regorafenib is a second-generation small molecule multikinase inhibitor that targets angiogenic (VEGFR 1-3, TIE2), stromal (PDGFR  $\alpha$ , FGFR) and oncogenic receptor tyrosine kinases (KIT, RET, RAF) [1]. Regorafenib's mechanism is believed to target cell-signaling pathways involved in tumor formation and progression, including angiogenesis, oncogenesis, and maintenance of the tumor environment [2]. It has been approved for the treatment of metastatic colorectal cancers (mCRC) and advanced gastrointestinal stromal tumors (GIST) [3]. Hand-foot skin reaction (HFSR) is the most characteristic dermatologic adverse effect of regorafenib and it has been reported in up to 60% of individuals taking this medication. Other less common dermatological

reactions associated with regorafenib include alopecia and oral mucositis [4]. There is another eruption associated with regorafenib, which has not been further characterized and usually involves less than 30% of the body surface area and is more often observed after the first cycle of chemotherapy with reduced incidence after subsequent cycles [2]. In this report, we describe a case of panniculitis in a patient treated with regorafenib for several months. This presentation has not been described previously.

## Case synopsis

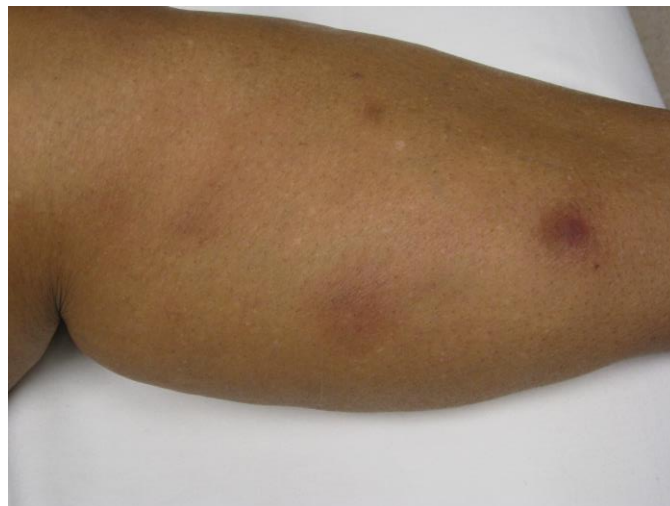A 60-year-old woman with a history of GIST with metastases to the peritoneum currently being treated with regorafenib presented with multiple calluses and thickening of her palms and soles. Prior to starting the chemotherapy, she denied any similar eruptions. On physical exam, the patient had hyperkeratotic yellow, scaly plaques covering bilateral palms and soles. Within the plaques, a few 2-8 mm focal hyperkeratotic thick papules were identified and ill-defined superficial desquamation was observed (Figure 1).



**Figure 1.** Hyperkeratotic papules in areas of pressure and friction with mild desquamation seen with hand-foot skin reaction

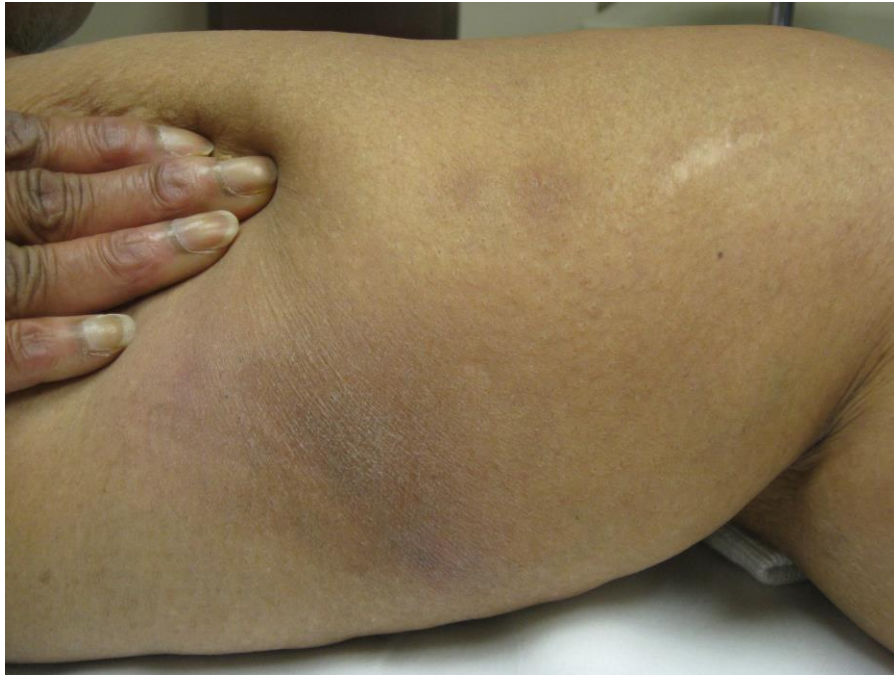These findings were consistent with HFSR, a well-reported side effect of multikinase inhibitors. The patient was advised to continue using daily moisturizer, perform intermittent hand and foot soaks, and wear comfortable shoes. In addition, she was recommended to apply a keratolytic agent, urea 40% cream, to affected areas daily.

Three months later, the patient had remarkable improvement in the HFSR. However, she had newly developed scattered papules and nodules on the bilateral lower extremities and abdomen. There were two morphologies: erythematous papules and pustules of the left ankle and erythematous indurated nodules on her left leg. These lesions were thought to be both folliculitis and furunculosis; she was treated with oral doxycycline (Figure 2).



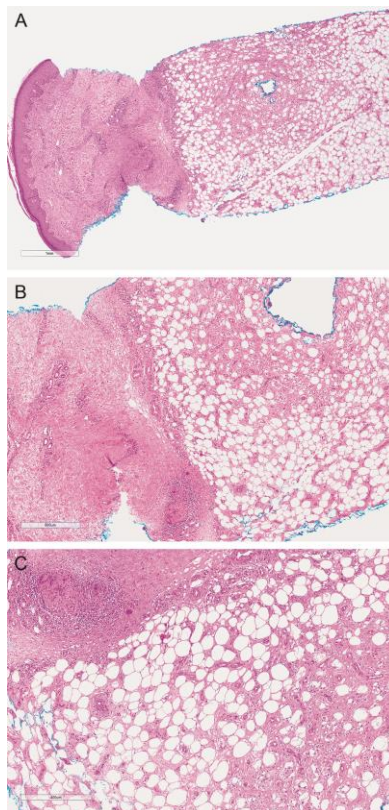
**Figure 2.** Ill-defined erythematous indurated nodules seen at first visit.

At her visit three months later, the smaller papules and pustules had resolved with oral doxycycline, but the larger, ill-defined, firm, tender erythematous nodules were still present and were suspicious for panniculitis mimicking erythema nodosum (Figure 3).



**Figure 3.** Ill-defined erythematous indurated nodules seen at second visit.

A 4 mm punch biopsy of a lesion on the calf demonstrated mixed lobular and septal panniculitis. Focal septal granulomatous inflammation (composed of lymphocytes, histiocytes, and multinucleated giant cells) admixed with septal fibrosis and lobular lymphohistiocytic infiltrate associated with fat necrosis was exhibited (Figure 4).



**Figure 4.** A. H&E representative picture revealing a mixed lobular and septal panniculitis (scanning power magnification) B and C. H&E representative picture showing septal granulomatous inflammation (composed of lymphocytes, histiocytes and multinucleated giant cells) admixed with septal fibrosis and lobular lymphohistiocytic infiltrate associated with fat necrosis (B: x100 and C: x200)

The patient was discontinued from the regorafenib because of non-response and her panniculitis resolved without treatment within three weeks of discontinuing the chemotherapy. No other medications were changed, and the patients' only other prescription medication was nifedipine, which she was taking for greater than two years and continued to take after her chemotherapy was switched.

## Discussion

Multikinase inhibitors are playing increasingly important roles in the treatment of various malignancies. However, several dermatological reactions have been associated with multikinase inhibitor therapy. The most specific and most common cutaneous reaction seen with regorafenib is HFSR, which was the presenting cutaneous eruption in our patient. In two phase III clinical trials for GIST and metastatic colorectal cancer (mCRC), there was a 46.6-56.6% incidence rate of HFSR. The next most significant cutaneous reactions were a nonspecific rash in 18.2-26.0% of patients and oral mucositis in 27.2-37.9% of patients. Alopecia was significant in the GIST trial with a 23.5% incidence rate, but was not reported in the mCRC trial [5,6].

HFSR initially presents as paresthesias, followed by tender, erythematous lesions on the palms and soles [4]. The lesions are especially prominent in areas that encounter high levels of mechanical stress, such as the palms, fingertips, finger webs, distal phalanges, soles, and toes [2]. The lesions may subsequently evolve into blisters or hyperkeratotic lesions. Patients on regorafenib are advised to wear soft, cotton socks and properly fitting padded footwear with orthotic inserts [4]. Patients are instructed to use creams and moisturizers and to avoid potentially drying products, such as soaps and hand sanitizers containing alcohol [2]. Excessive mechanical stress on the palms and soles, including running and using tools, should be minimized. This limitation in activity is especially important in the first six weeks of treatment, as this is when HFSR typically occurs [4]. Cold packs and NSAIDs can be used in patients experiencing pain. HFSR usually improves with time, but if these measures are unsuccessful in relieving the patient's symptoms, dose modification may be necessary [2].

HFSR was first described as the classic cutaneous eruption associated with sorafenib and sunitinib, first-generation multikinase inhibitors. Sorafenib inhibits the serine-threonine kinases, Raf-1 and B-Raf, and the tyrosine kinase activity of vascular endothelial growth factor receptors (VEGFRs) and platelet-derived growth factor receptor  $\beta$  (PDGFR- $\beta$ ) [7]. It has been approved for the treatment of advanced renal cell carcinoma, hepatocellular carcinoma, and thyroid cancer [7,8]. Sorafenib has been associated with various dermatological reactions, including HFSR, maculopapular or papulopustular rash, bullous dermatitis, vasculitis, pruritus, skin ulceration, angioedema, cheilitis, exfoliation, psoriasis, urticaria, alopecia, hyperpigmentation, subungual hemorrhages, acneiform facial eruption, squamous cell carcinoma, eruptive nevi, Stevens-Johnson syndrome, and toxic epidermal necrolysis [8-11]. One case of panniculitis and necrotizing vasculitis has been reported in a patient who was treated with sorafenib for hepatocellular carcinoma after three months of treatment [7]. This time frame is consistent with the delayed presentation in our patient. Sunitinib is another multikinase inhibitor that has anti-tumor and anti-angiogenic effects via inhibition of VEGFR-2, stem cell factor receptor, fetal liver tyrosine kinase receptor-3 and PDGFR  $\alpha$  and  $\beta$  [10]. Sunitinib has been associated with HFSR, maculopapular rash, pruritus, skin ulceration, xerosis, eruptive nevi, subungual splinter hemorrhages, icterus, pyoderma gangrenosum, acral erythema, hair depigmentation, seborrheic dermatitis, vasculitis, and purpura [9-11]. There are no reports of sunitinib-induced panniculitis in the literature.

Regorafenib has also been associated with a morbilliform eruption, typically involving less than 30% of a patient's body surface area. The rash occurs after the first cycle of treatment, unlike the panniculitis described above, which had a delayed presentation. The eruption improves with time and can be treated with antihistamines, topical corticosteroids, and emollients and mild soaps. Also, minimizing direct sunlight exposure and avoiding extreme temperatures can either prevent or reduce the severity of the rash [2].

Although regorafenib-induced panniculitis has not been reported previously in the literature, this type of reaction has been observed in patients treated with BRAF inhibitors. In these patients, erythema nodosum-like skin lesions have been reported with increasing frequency. The median time to onset of skin lesions is 8 weeks, and the majority of lesions are located on the legs. Often, these lesions are accompanied by systemic symptoms, such as arthralgia, fever, conjunctivitis, central scotoma, fatigue and myalgia [10]. As the lesions are thought to be a result of a systemic, noninfectious inflammatory reaction, patients can be treated symptomatically with NSAIDs and topical or systemic steroids [13]. In severe cases, dose reduction or interruption is considered [12]. Although the underlying mechanisms of BRAF inhibitor-induced panniculitis have not been elucidated, it is not unexpected that regorafenib, which also targets BRAF, has overlapping side effects and indicates that the panniculitis seen in our patient could be a result of BRAF inhibition.

In an environment of using multiple targeted small molecular inhibitors synergistically, it is useful to understand the cutaneous side effects associated with each drug. This is the first case of a panniculitis reported with regorafenib, a multikinase inhibitor.

Panniculitides have not been classically associated with multikinase inhibitors and early recognition of this delayed-onset eruption can facilitate the treatment and comfort of patients.

## References

1. Deng G-L, Zeng S, Shen H. Chemotherapy and target therapy for hepatocellular carcinoma: New advances and challenges. *World J of Hepatol* 2015;7(5):787-798. [PMID: 25914779]
2. De Wit M, Boers-Doets CB, Saettini A, Vermeersch K, de Juan CR, Ouwekerk J, Raynard S, Bazin A, Cremolini C. Prevention and management of adverse events related to regorafenib. *Support Care Cancer* 2014;22(3):837-846. [PMID: 24337717]
3. Canter RJ, Ames E, Mac S, Grossenbacher SK, Chen M, Li C, Borys D, Smith RC, Tellez J, Sayers TJ, Monjazeb AM, Murphy WJ. Anti-proliferative but not anti-angiogenic tyrosine kinase inhibitors enrich for cancer stem cells in soft tissue sarcoma. *BMC Cancer* 2014;14:756. [PMID: 25301268]
4. Belum VR, Cercek A, Sanz-Motilva V, Lacouture ME. Dermatologic adverse events to targeted therapies in lower GI cancers: clinical presentation and management. *Curr Treat Options Oncol.* 2013;14(3): 389-404. [PMID: 23996476]
5. Demetri GD, Reichardt P, Kang YK, et al. Efficacy and safety of regorafenib for advanced gastrointestinal stromal tumours after failure of imatinib and sunitinib (GRID): an international, multicentre, randomised, placebo-controlled, phase 3 trial. *Lancet.* 2013;381(9863):295-302. [PMID: 23177515]
6. Grothey A, Van cutsem E, Sobrero A, et al. Regorafenib monotherapy for previously treated metastatic colorectal cancer (CORRECT): an international, multicentre, randomised, placebo-controlled, phase 3 trial. *Lancet.* 2013;381(9863):303-12. [PMID: 23177514]
7. Panebianco M, Ragazzi M, Asensio NM, Pagano M, Gnoni R, Boni C. A case of necrotizing vasculitis with panniculitis, during sorafenib treatment for hepatocellular carcinoma, appeared in disease progression. *J Gastroint Oncol* 2014;5(6):E121-E124. [PMID: 25436135]
8. Cohen PR. Sorafenib-Associated Facial Acneiform Eruption. *Dermatol Ther* 2015;5(1):77-86. [PMID: 25539704]
9. Faye E, Bondon-Guitton E, Olivier-Abbal P, Montastruc J. Spontaneous reporting of serious cutaneous reactions with protein kinase inhibitors. *Eur J Clin Pharmacol* 2013;69:1819-26. [PMID: 23748749]
10. Gole P, Madke B, Khopkar U, Kumar P, Noronha V, Yadav M. Side effects of Sorafenib and sunitinib: A new concern for dermatologist and oncologist. *Indian Dermatol Online J* 2014;5(1):89-91. [PMID: 24616870]
11. Macdonald, JB, Macdonald B, Golitz LE, LoRusso P, Sekulic A. Cutaneous adverse effects of targeted therapies: Part I: Inhibitors of the cellular membrane. *J Am Acad Dermatol* 2015;72(2):203-218. [PMID: 25592339]
12. Mössner R, Zimmer L, Berking C, Hoeller C, Loquai C, Richtig E, Kähler KC, Hassel JC, Gutzmer R, Ugurel S. Erythema nodosum-like lesions during BRAF inhibitor therapy: Report on 16 new cases and review of the literature. *J Eur Acad Dermatol Venereol* 2015. [PMID: 25752368]
13. Zimmer L, Livingstone E, Hillen U, Dömkes S, Becker A, Schadendorf D. Panniculitis With Arthralgia in Patients With Melanoma Treated With Selective BRAF Inhibitors and Its Management. *Arch Dermatol.* 2012;148(3):357-361. [PMID: 22250191]