

# UC Davis

## Dermatology Online Journal

### Title

A case of tinea incognito mimicking subcorneal pustular dermatosis

### Permalink

<https://escholarship.org/uc/item/46g9x55w>

### Journal

Dermatology Online Journal, 26(2)

### Authors

Kalkan, Göknur  
Demirseren, D Deniz  
Güney, Cansu Altınöz  
et al.

### Publication Date

2020

### DOI

10.5070/D3262047432

### Copyright Information

Copyright 2020 by the author(s). This work is made available under the terms of a Creative Commons Attribution-NonCommercial-NoDerivatives License, available at <https://creativecommons.org/licenses/by-nc-nd/4.0/>

Peer reviewed

# A case of tinea incognito mimicking subcorneal pustular dermatosis

Göknur Kalkan<sup>1</sup>, D Deniz Demirseren<sup>2</sup>, Cansu Altınöz Güney<sup>1</sup>, Akın Aktaş<sup>1</sup>

Affiliations: <sup>1</sup>Department of Dermatology, School of Medicine, Ankara Yıldırım Beyazıt University, Ankara, Turkey, <sup>2</sup>Department of Dermatology, Ankara City Hospital, Ankara, Turkey

Corresponding Author: Göknur Kalkan, Department of Dermatology, Ankara Yıldırım Beyazıt University, Faculty of Medicine, Ankara, Turkey, Tel: 90-505 265 32 71, Email: [goknurkalkan@yahoo.com](mailto:goknurkalkan@yahoo.com)

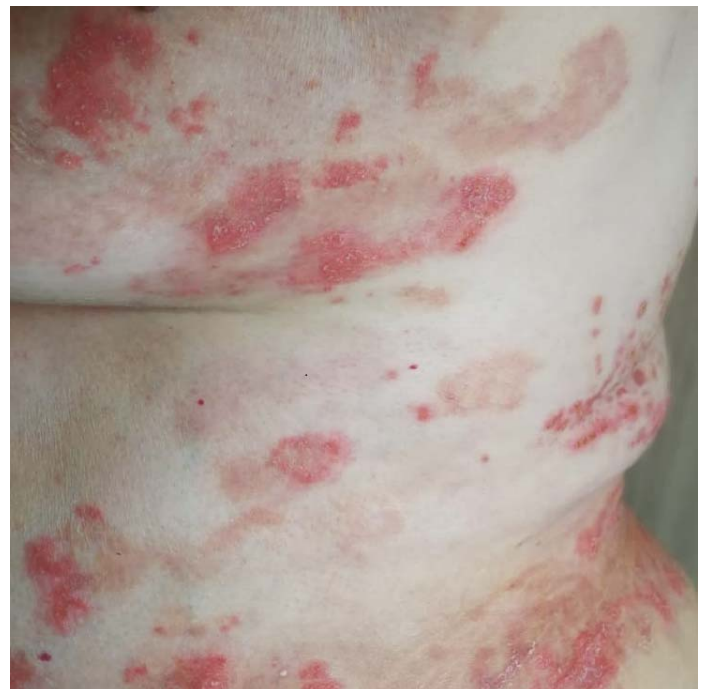## Abstract

An 89-year-old woman presented with plaque-like lesions, accompanied with pustules and desquamation on the back and front of the trunk for approximately one year. Long term use of potent topical corticosteroids was ineffective. Because of the chronicity of her condition, the diagnoses of subcorneal dermatosis or subcorneal pustular dermatosis type of IgA pemphigus were considered. However, fungal hyphae were observed in the potassium hydroxide examination. Therefore, we present this case since this clinical appearance of tinea incognito can also mimic various pustular dermatoses.

20% potassium hydroxide (KOH) is a simple and inexpensive test in the diagnosis of the disease [1-3].

## Case Synopsis

An 89-year-old woman presented with plaques, accompanied by pustules and desquamation on the back and front of the trunk for approximately one year (**Figure 1**). Long term use of potent topical corticosteroid had been ineffective. Because of the chronicity, the diagnoses of subcorneal dermatosis or subcorneal pustular dermatosis type of IgA



**Figure 1:** Lesions mimicking pustular dermatoses on the trunk.

*Keywords: tinea incognito, pustular dermatosis*

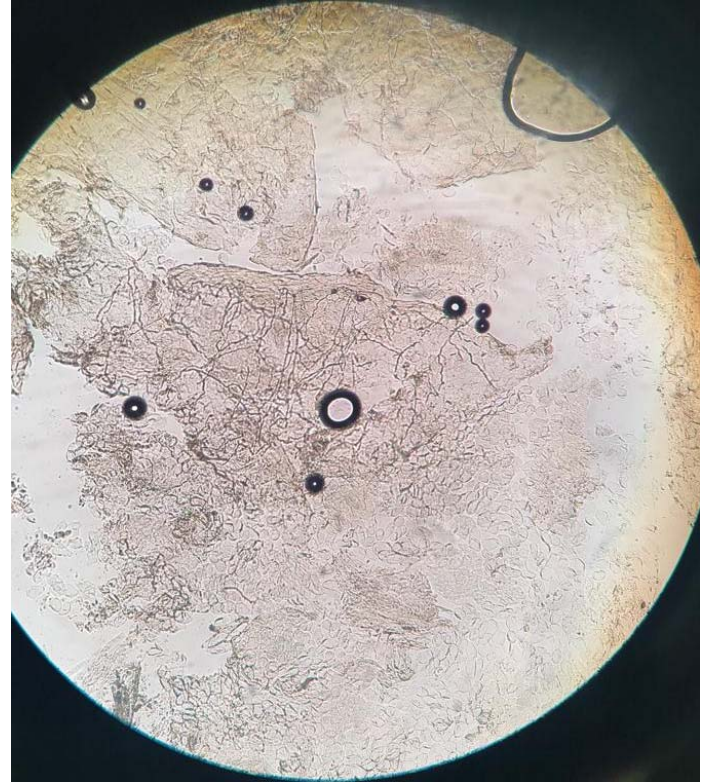
## Introduction

Tinea incognito is a superficial fungal infection with an atypical clinical appearance caused by inappropriate use of topical or systemic corticosteroids. The dermatophytic infection of the skin is masked and often exacerbated by application of topical agents containing corticosteroids. The clinical manifestations of tinea incognito can mimic many dermatoses such as eczema, psoriasis, allergic contact dermatitis, rosacea, seborrheic dermatitis, and atopic dermatitis. The differential diagnosis may be challenging for the clinician because of the atypical presentation. Microscopic examination with

pemphigus were considered. However, prior to beginning a more extensive work up, a KOH examination, which is simple and inexpensive, revealed fungal hyphae (**Figure 2**). Performing unnecessary interventional procedures such as biopsy and direct immunofluorescence methods were avoided. The history of prolonged misuse of potent topical corticosteroids facilitated the establishment of the correct diagnosis. As a result of the KOH examination, the patient was diagnosed with tinea incognito and treated with systemic and topical anti-fungal therapy.

### Case Discussion

In a multi-center study composed of 283 tinea incognito patients performed in Korea, the following diagnoses had been incorrectly applied to tinea incognito patients: nonspecific eczema, contact dermatitis, atopic dermatitis, seborrheic dermatitis, diaper dermatitis, intertrigo, nummular dermatitis, stasis dermatitis, psoriasis, lupus erythematosus, urticaria, and lichen simplex chronicus [3]. In another series, Romano et al. presented 200 cases of tinea incognito; the most common mimicking dermatoses were impetigo, discoid dermatitis, lupus erythematosus, polymorphic light eruption, psoriasis, rosacea, seborrheic dermatitis, lichen planus, and erythema migrans [4]. Recently, a bullous form of tinea incognito has been also described for the first time in the medical literature [5]. Cox et al. also reported a similar case of tinea incognito recently, presenting with an annular red plaque with a raised purpuric border lasting for 12 weeks in which the diagnosis was also confirmed by biopsy [6].



**Figure 2:** Fungal hyphae were observed by direct KOH (potassium hydroxide) examination.

### Conclusion

We would like to present this unusual case, since this clinical appearance of tinea incognito can also mimic various pustular dermatoses. We remind clinicians to include tinea incognito in their differential diagnosis; a direct microscopic examination should be the first step in the diagnosis.

### Potential conflicts of interest

The authors declare no conflicts of interests.

### References

1. Kim MW, Park HS, Bae JM, Yoon HS, Cho S. Tinea Incognito with Folliculitis-Like Presentation: A Case Series. *Ann Dermatol.* 2018;30:97-99. [PMID: 29386843].
2. Paloni G, Valerio E, Berti I, Cutrone M. Tinea Incognito. *J Pediatr.* 2015;167:1450-e2. [PMID: 26423793].
3. Won-Jeong K, Tae-Wook K, Je-Ho M, et al: Tinea incognito in Korea and its risk factors: nine-year multicenter survey. *J Korean Med Sci.* 2013;28:145-51. [PMID: 23341725].
4. Romano C, Maritati E, Gianni C. Tinea incognito in Italy: a 15-year survey. *Mycoses.* 2006;49:383-7. [PMID: 16922789].
5. Tchernev G, Terziev I. Bullous Tinea Incognito in a Bulgarian Child: First Description in the Medical Literature. *Open Access Maced J Med Sci.* 2018;14;6:376-377. [PMID: 29531608].
6. Cox SV, Cohen PR. What is this annular plaque on the leg? *The Dermatologist.* 2017;25:47-50. <https://www.the-dermatologist.com/article/what-annular-plaque-leg>. Accessed on January 1, 2020.