

UC Davis

Dermatology Online Journal

Title

Pemphigus foliaceus

Permalink

<https://escholarship.org/uc/item/421460hm>

Journal

Dermatology Online Journal, 20(12)

Authors

Orne, Charisse M
Hale, Christopher S
Meehan, Shane A
et al.

Publication Date

2015

DOI

10.5070/D32012025064

Copyright Information

Copyright 2015 by the author(s). This work is made available under the terms of a Creative Commons Attribution-NonCommercial-NoDerivatives License, available at <https://creativecommons.org/licenses/by-nc-nd/4.0/>

Peer reviewed

Case Presentation

Pemphigus foliaceus

Charisse M. Orme MD PhD, Christopher S. Hale MD, Shane A. Meehan MD, and Marie Leger MD PhD

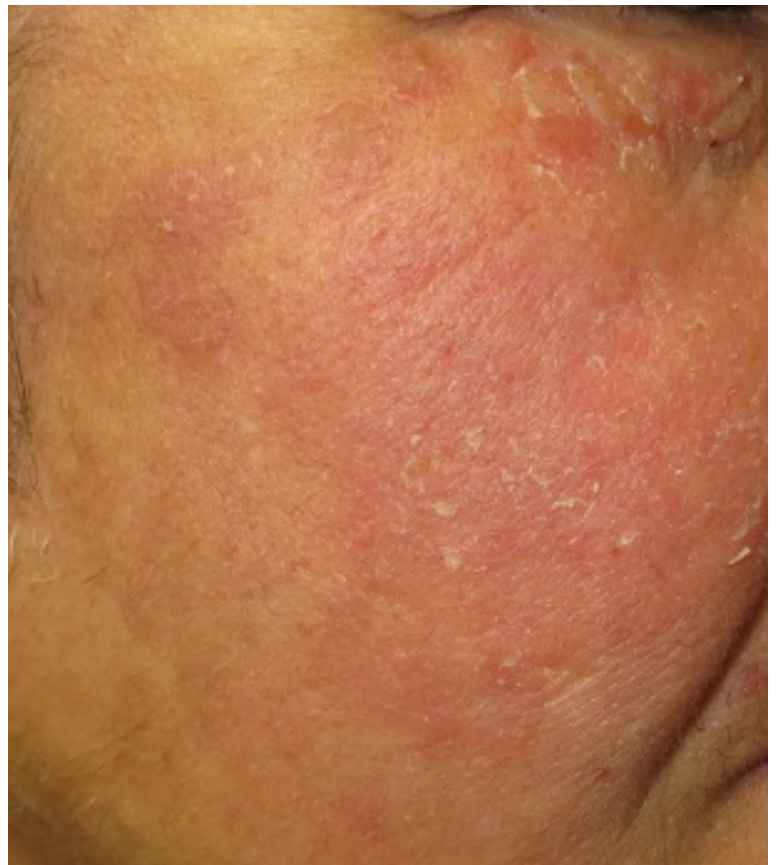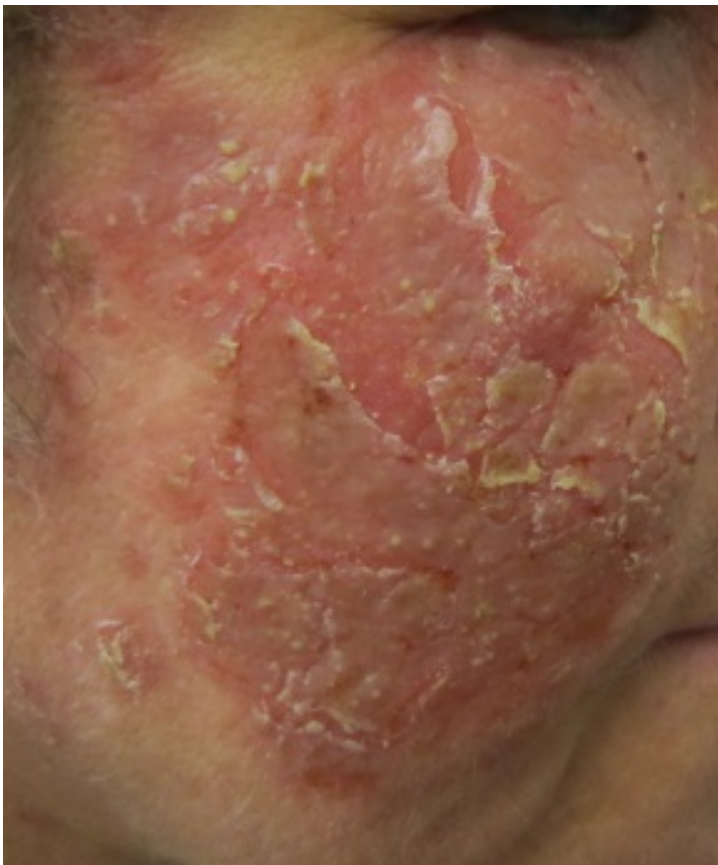Dermatology Online Journal 20 (12): 115

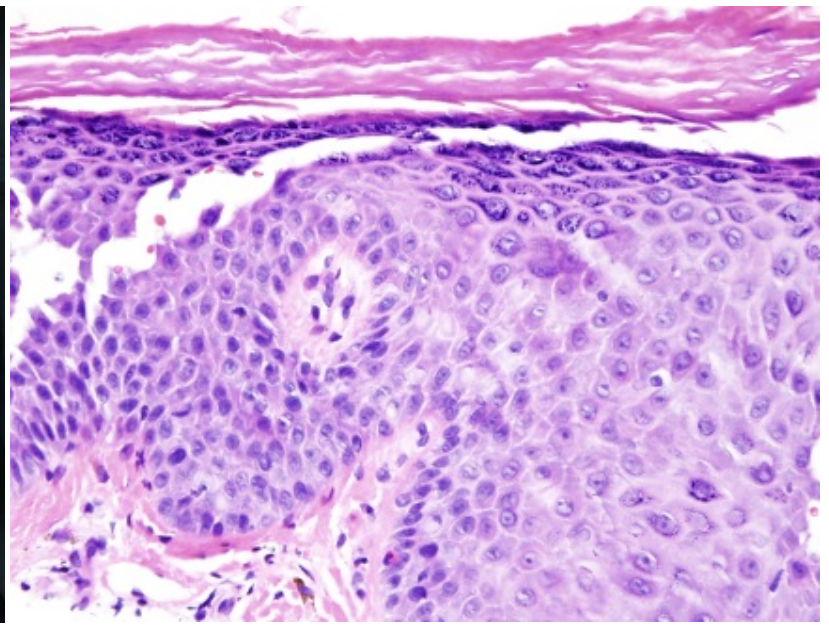
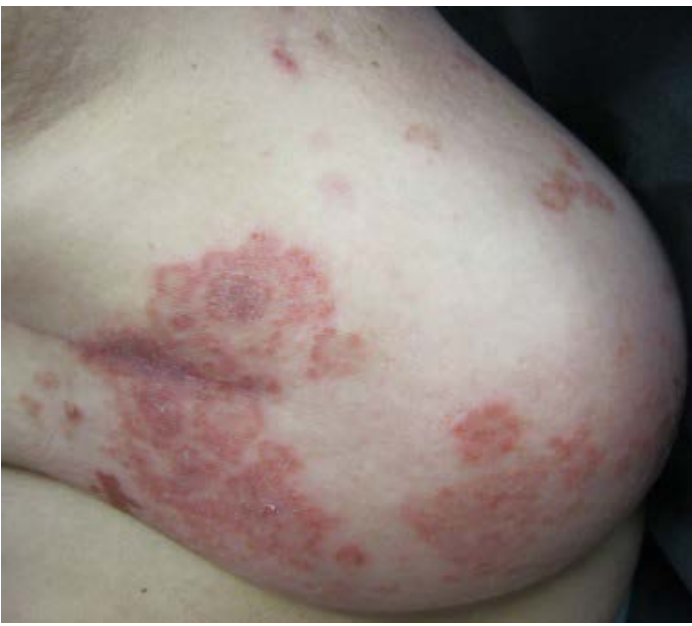New York University School of Medicine

Special Guest Editor: Nicholas A. Soter, MD

Abstract

A 55-year-old woman presented after a four-year history of impetiginized eczema that was distributed over her face, scalp, chest, and back and a recent diagnosis of breast cancer. A skin biopsy specimen for direct immunofluorescence demonstrated intercellular IgG4. Anti-desmoglein 1 and 3 antibodies were present. Indirect immunofluorescence testing was positive on monkey but not rat esophagus. These findings were consistent with a diagnosis of pemphigus foliaceus in association with a malignant condition. After many years of the use of topical glucocorticoids and oral antibiotics, the patient's disease was ultimately managed with methotrexate and a small dose of prednisone. Increasing data supports a role for a steroid-sparing effect of methotrexate in pemphigus vulgaris and likely pemphigus foliaceus.





Case synopsis

History: A 55-year-old woman presented to NYU Dermatologic Associates with a four-year history of dermatitis that previously had been diagnosed as impetiginized atopic dermatitis versus psoriasis. Multiple previous specimens were interpreted as spongiotic dermatitis with secondary impetiginization. She had a personal history of asthma and reported a family history of asthma, rhinitis, and eczema. She did not report a personal or family history of autoimmune diseases. The patient had received multiple courses of antibiotics and topical glucocorticoids with only minor improvements in the eruption. There was pruritus associated with her condition. The patient denied oral involvement. Her medical history included asthma, hypertension, and breast cancer two months prior to presentation. Her medications included urbesartan, hydrochlorothiazide, vitamin B complex and, boswellia serrata extract powder.

Physical examination: On the face, which included the area from the lower lid to the lower cheek and temples, red scaly plaques were present. She had annular, yellow plaques with scale of the chest and back. The mucosal surfaces were normal.

Laboratory data: A complete blood count and chemistry profile were normal. Cholesterol was 257mg/dL and triglycerides 169 mg/dL. Anti-antinuclear antibody, rheumatoid factor, and anti-Ro, anti-La, and anti-Smith antibodies were negative. Desmoglein 1 and Desmoglein 3 antibodies were elevated at 201.4 and 85.9 Elisa units, respectively.

Histopathology: There is intraepidermal and subcorneal acantholysis. A periodic acid-Schiff with diastase stain fails to show fungal hyphae.

A direct immunofluorescence test shows linear and focal intercellular deposition of IgG4 and IgG1 with granular C3 and IgG deposits within the epidermis. Fibrin deposits are noted in the papillary dermis. Indirect immunofluorescence on monkey esophagus is positive for IgG4 and IgG1. Indirect immunofluorescence on rat bladder is negative.

Discussion

Diagnosis: Pemphigus foliaceus

Comments: We present a patient with breast cancer and the rare, autoimmune, blistering disorder pemphigus foliaceus (PF), which was successfully managed with methotrexate and low-dose prednisone. Although there is an indisputable link between malignant conditions and paraneoplastic pemphigus (PNP), there also is limited evidence that patients with other subtypes of pemphigus, such as pemphigus vulgaris (PV) and PF, also have an increased incidence of malignant conditions when compared to the general population [1-3]. The occurrence of associated cancer ranges from 5 to 11.2% and includes a variety of non-hematologic malignant conditions, such as breast cancer. Malignant conditions and pemphigus may occur simultaneously or one can precede the other.

The pemphigus family of diseases has historically been treated with moderate-to- high-doses of glucocorticoids for extended periods. Owing to the side effects that are associated with oral glucocorticoids, other immunomodulatory agents have been evaluated in the treatment of pemphigus. However, there is currently no consensus concerning the best steroid-sparing approach [4]. Methotrexate has been successfully and safely used for the management of other dermatologic diseases, such as psoriasis, since the 1960s [5]. Although not considered standard of care, reports of methotrexate as steroid-sparing therapy for PV have been presented in the literature for the past 45 years [6-12]. To the best of our knowledge, no literature exists regarding methotrexate therapy as treatment for PF.

In a recent, retrospective study that examined the effects of methotrexate on PV, the mean time from diagnosis of PV to methotrexate use was 35 months [6]. The maintenance dose of prednisone required for adequate control was 34.5 mg daily prior to initiating methotrexate. With an average methotrexate dose of 18.9 mg weekly, most patients were either able to stop prednisone completely (70%) or continue with a reduced average range of 2 to 10 mg daily (22%). Similar results have been found in other studies [11, 12]. Eventual weaning from methotrexate without a flare for those on methotrexate monotherapy was successful in 21% although the dose of methotrexate was at least reduced by one-half in 57% of patients [6].

Traditionally, PV is defined by the presence of antibodies against desmoglein 1 (Dsg1) and desmoglein 3 (Dsg3), whereas PF has only antibody to desmoglein 1 (Dsg1) [13]. Our patient was positive for both Dsg1 and Dsg3, which suggested a biochemical diagnosis of PV. However, clinically she had the traditional facial distribution of the eruption and lack of oral involvement that is observed in classic PF. After three years of undiagnosed and untreated PF, the patient underwent a lumpectomy for newly-diagnosed breast cancer. The patient declined additional radiation and hormonal adjuvant treatments for her cancer. Her oncologist was consulted to determine which immunosuppressive therapy would be most safe and appropriate for use in PF. Rituximab was considered but not initiated owing to concerns of an increased risk of malignant conditions. Methotrexate 15 mg weekly and prednisone 60 mg daily were started. Her symptoms rapidly improved. Over eight weeks, the prednisone dose was tapered from 60 mg to 10 mg, and the methotrexate was increased from 15 to 25 mg weekly. She now has limited disease with involvement of the cheeks and breasts and is maintained on a methotrexate dose of 25 mg weekly and prednisone dose of 1.5 mg daily.

References

1. Younus J, et al. The relationship of pemphigus to neoplasia. *J Am Acad Dermatol* 1990; 23: 498 [PMID: 2212152]
2. Iwashita K, et al. The incidence of internal malignancies in autoimmune bullous diseases. *Tokai J Exp Clin Med* 2007; 32: 42 [PMID: 21319056]
3. Ogawa H, et al. The incidence of internal malignancies in pemphigus and bullous pemphigoid in Japan. *J Dermatol Sci* 1995; 9: 136 [PMID: 7772576]
4. Frew JW, et al. Evidence-based treatments in pemphigus vulgaris and pemphigus foliaceus. *Dermatol Clin* 2011; 29: 599 [PMID: 21925004]
5. Benedek TG. Psoriasis and psoriatic arthropathy, historical aspects: part I. *J Clin Rheumatol* 2013; 19: 193 [PMID: 23669809]
6. Tran KD, et al. Methotrexate in the treatment of pemphigus vulgaris: experience in 23 patients. *Br J Dermatol* 2013; 169: 916 [PMID: 23772610]
7. Lever WF, et al. Treatment of pemphigus vulgaris with methotrexate. *Arch Dermatol* 1969; 100: 70 [PMID: 5822360]
8. Peck SM, et al. Studies in bullous diseases: treatment of pemphigus vulgaris with immunosuppressives (steroids and methotrexate) and leucovorin calcium. *Arch Dermatol* 1971; 103: 141 [PMID: 4928233]
9. Lever WF. Methotrexate and prednisone in pemphigus vulgaris: therapeutic results obtained in 36 patients between 1961 and 1970. *Arch Dermatol* 1972; 106: 491 [PMID: 4562487]
10. Gurcan HM, et al. Analysis of current data on the use of methotrexate in the treatment of pemphigus and pemphigoid. *Br J Dermatol* 2009; 161: 723 [PMID: 19548961]
11. Smith TJ, et al. Methotrexate as an adjuvant treatment for pemphigus vulgaris. *Arch Dermatol* 1999; 135: 1275 [PMID: 10522684]
12. Baum S, et al. Methotrexate is an effective and safe adjuvant therapy for pemphigus vulgaris. *Euro J Dermatol* 2012; 22: 83 [PMID: 22266247]
13. Groves RW. Pemphigus: a brief review. *Clin Med* 2009; 9: 371 [PMID: 19728517]