

# UC Davis

## Dermatology Online Journal

### Title

Photodistributed granuloma annulare

### Permalink

<https://escholarship.org/uc/item/3tq3054b>

### Journal

Dermatology Online Journal, 21(12)

### Authors

Gittler, Julia  
Mir, Adnan  
Meehan, Shane A  
et al.

### Publication Date

2015

### DOI

10.5070/D32112029540

### Copyright Information

Copyright 2015 by the author(s). This work is made available under the terms of a Creative Commons Attribution-NonCommercial-NoDerivatives License, available at <https://creativecommons.org/licenses/by-nc-nd/4.0/>

Peer reviewed

**Case presentation**

**Photodistributed granuloma annulare**

**Julia Gittler, MD, Adnan Mir MD PhD, Shane A Meehan MD, and Miriam Keltz Pomeranz MD**

**Dermatology Online Journal 21 (12): 13**

**New York University School of Medicine**

**Special Guest Editor: Nicholas A Soter MD**

---

**Abstract**

Annular elastolytic giant cell granuloma (AEGCG) is a controversial entity that is considered by many to be a variant of granuloma annulare (GA). The majority of cases of AEGCG occur in Caucasian women (3:2) between the ages of 40 and 70, with the distribution of the mostly annular lesions favoring exposed areas of skin and rarely involving covered skin. The most common systemic association has been with diabetes mellitus. We present a 52-year-old woman with an asymptomatic, annular, erythematous, photodistributed eruption of two-years duration. As part of her evaluation, it was detected that she had a hemoglobin A1C of 10.3% and a diagnosis of diabetes mellitus was made. We review the literature on the clinical and histopathologic features of GA and AEGCG and the overlap between these entities.

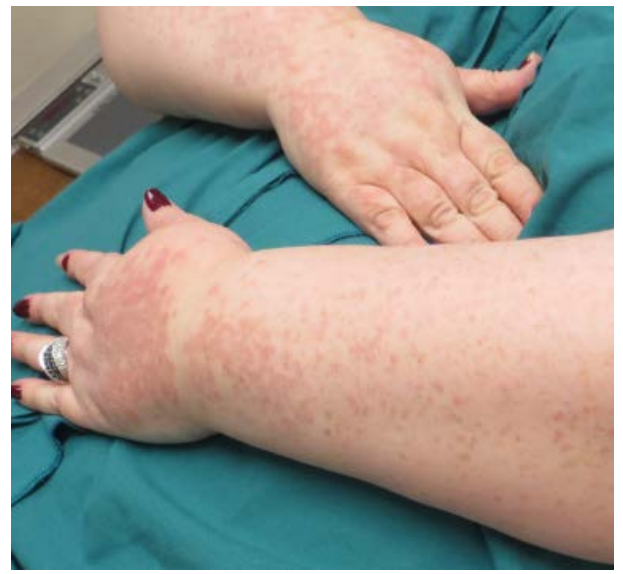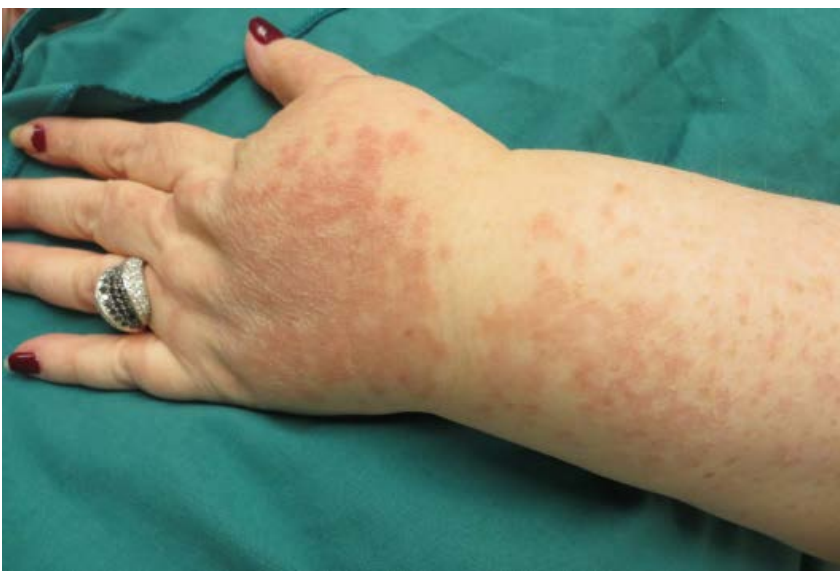**Case synopsis**

**History:** A 52-year-old woman presented to the Skin and Cancer Unit for evaluation of an asymptomatic eruption of two-years duration. Around the time of experiencing stress, she first developed erythematous papules on her right forearm and the dorsal aspect of the right hand that persisted despite treatment with a topical glucocorticoid. Several months prior to presentation, after another stressful life event, the eruption appeared on her dorsal aspect of the left hand and forearm and later spread to her upper chest. The eruption remained asymptomatic. At the time of presentation, she denied recent sun exposure, although she reported sun exposure as a child. She noted many sunburns and inability to tan. The patient denied fever, chills, nausea, vomiting, and diarrhea. She reported recent weight gain.

**Physical examination:** On the dorsal aspects of the hands, forearms, and upper chest were annular, erythematous, thin papules and plaques.

**Laboratory data:** A complete blood count, anti-nuclear antibody, anti-Ro antibody, anti-La antibody, and serum protein electrophoresis were normal or negative. Comprehensive metabolic panel showed glucose of 216 mg/dL and aspartate transaminase and alanine transaminase of at 110 and 108 U/L, respectively. Hemoglobin A1C was at 10.3%.

**Histopathology:** There is a nodular infiltrate of histiocytes, some of which are multinucleated, that surround foci of degenerated collagen and increased connective tissue mucin, as demonstrated by a colloidal-iron stain.



Figures 1,2. Erythematous papules and plaques, some in annular array.

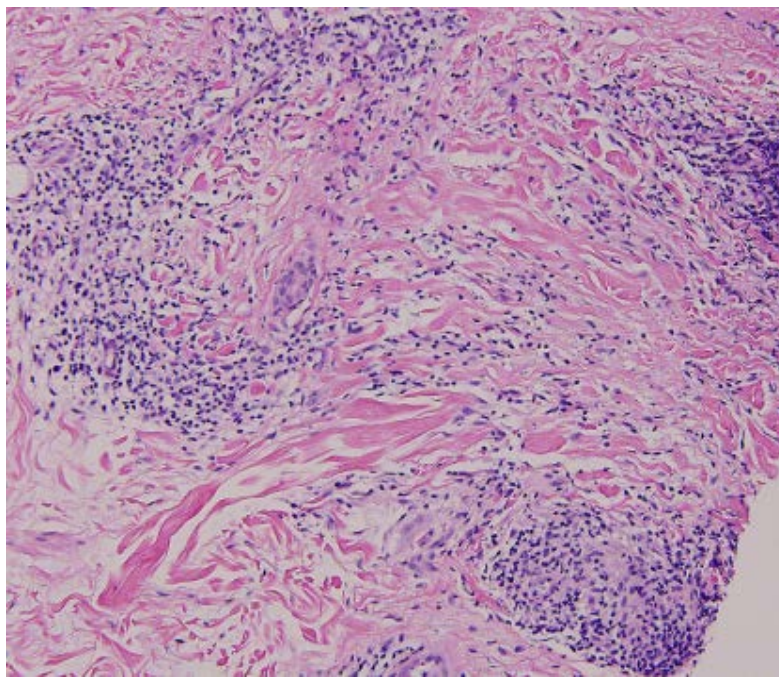


Figure 3. Nodular histiocytic infiltrate with some multinucleated giant cells, foci of degenerated collagen

## Discussion

**Diagnosis:** Photodistributed granuloma annulare

**Comment:** Granuloma annulare (GA) is a benign, granulomatous dermatosis of unknown etiology, which most commonly has a localized distribution. Cases associated with photodistribution are rare and may overlap with annular elastolytic giant cell granuloma (AEGCG). AEGCG is a controversial entity, which was described as a granulomatous dermatologic condition with clinical similarities to GA [1,2]. It is characterized clinically by papules that evolve into annular and serpiginous plaques with elevated borders and histologically by elastolysis along with elastophagocytosis by multinucleated giant cells. Papular and reticular variants have been described [1]. The majority of cases of AEGCG occur in Caucasian women (3:2) between the ages of 40 and 70, with the distribution of the mostly annular lesions favoring exposed areas of skin and rarely involving covered skin. The most common systemic association has been diabetes mellitus [2].

Specific histopathologic findings of AEGCG include a prominent degree of elastolysis and elastophagocytosis by multinucleated giant cells and the lack of necrobiosis or excessive deposition of mucin [2]. It was originally noted that these histopathologic changes were present in annular lesions in sun-damaged skin, and the term actinic granuloma (AG) was suggested for lesions with

a distribution that correspond to sun-exposed skin and to indicate the pathogenic role of solar radiation [3]. However, investigators challenged the notion of AG as a distinct entity from GA, especially because of case reports of AG-like lesions in sun-protected areas. The term annular elastolytic giant cell granuloma (AEGCG) was initially introduced to specifically describe annular lesions with a major granulomatous elastolytic component, which could occur anywhere in the skin, including actinic sites [4].

In a review of the clinicopathologic data of 20 patients whose biopsies demonstrated the histopathologic features of elastolytic granuloma, as well as previously published cases with identical tissue changes, it was determined that the tissue changes of AG and AEGCG are identical and differ from GA because of predominant elastolysis and elastophagocytosis in the absence of necrobiosis and palisading granuloma [2]. However, elastolysis and elastophagocytosis occur in several diseases, which include generalized GA and cutaneous lymphoma and may be incidental to the activation of histiocytes [5]. Authors have attempted to distinguish AEGCG by the distinct zone of elastophagocytosis that is observed and the differing quantity and distribution of giant cells as compared to GA [6]. Yet, biopsies with mixed histopathologic features of GA and AEGCG have been described and attempts to distinguish these lesions by immunohistological methods have not yielded a consensus as many still consider AG and AEGCG to be variants of GA [7]. It has been suggested that cell-mediated immunity with a predominance of helper-inducer T cells plays a role in AG and an individual's predisposition to respond immunologically to altered endogenous collagen or elastic tissue may result in differing histopathologic expressions [8]. Immunohistological studies have demonstrated a predominance of CD4+ cells over CD8+ cells in AEGCG [9]. This may be further altered by an underlying metabolic disorder such as diabetes mellitus, which may induce damage to elastic fibers, and in conjunction with ultraviolet radiation, alter its antigenicity [10]. The existence of a systemic disease, such as diabetes mellitus, may contribute to the overlap histopathologic pattern observed in several cases that showed features that were characteristic of GA, such as palisading granulomas and necrobiosis, and of AEGCG, such as elastolysis and elastophagocytosis [2, 7].

Case reports have described successful treatment of AEGCG with topical, intralesional, and systemic glucocorticoids; clofazimine; cryotherapy; dapsons; cyclosporine; methotrexate; narrowband ultraviolet B phototherapy; retinoids; fumaric acid esters; antimalarials; topical calcineurin inhibitors; and minocycline hydrochloride, although spontaneous regression also has been reported [11, 12].

## References

1. Morita K, et al. Papular elastolytic giant cell granuloma: a clinical variant of annular elastolytic giant cell granuloma or generalized granuloma annulare? *Eur J Dermatol* 1999; 9: 647
2. Limas C. The spectrum of primary cutaneous elastolytic granulomas and their distinction from granuloma annulare: a clinicopathological analysis. *Histopathology* 2004; 44: 277
3. O'Brien JP. Actinic granuloma: an annular connective tissue disorder affecting sun- and heat- damaged (elastotic) tissue. *Arch Dermatol* 1975; 111: 460
4. Hanke CW et al. Annular elastolytic giant cell granuloma. *J Am Acad Dermatol* 1979; 1: 413
5. El-Hkoury J, et al. Elastophagocytosis: underlying mechanisms and associated cutaneous entities. *J Am Acad Dermatol* 2014; 70: 934
6. Goncalves R, et al. Annular elastolytic giant cell granuloma-case report. *Anais Brasileiros de Dermatologia* 2011;86(Suppl 1):S69
7. Revenga F, et al. Annular elastolytic giant cell granuloma- actinic granuloma? *Clin Exp Dermatol* 1996; 21; 51
8. Vehring KH, et al. Das anuläre elastolytische Riesenzellgranulom-eine Differentialdiagnose kutaner Granulomatosen. *Hautarzt* 1991; 42; 391
9. Tsutsui K, et al. Annular elastolytic giant cell granuloma: response to cyclosporine A. *J Dermatol* 1994;21:426
10. Doulaveri G, et al. Annular elastolytic giant cell granuloma in a 70-year-old woman. *Int J Dermatol* 2003;42:290
11. Nanbu A, et al. Annular elastolytic giant cell granuloma successfully treated with minocycline hydrochloride. *Acta Derm Venereol* 2015; epub ahead of print
12. Errichetti E, et al. Annular elastolytic giant cell granuloma treated with topical pimecrolimus. *Indian J Dermatol Venereol Leprol* 2014;80:475