

UC Davis

Dermatology Online Journal

Title

A case of probable trimethoprim-sulfamethoxazole induced circulating antineutrophil cytoplasmic antibody-positive small vessel vasculitis

Permalink

<https://escholarship.org/uc/item/3j9537pg>

Journal

Dermatology Online Journal, 23(8)

Authors

Woodring, Therese
Abraham, Ronnie
Frisch, Stephanie

Publication Date

2017

DOI

10.5070/D3238036014

Copyright Information

Copyright 2017 by the author(s). This work is made available under the terms of a Creative Commons Attribution-NonCommercial-NoDerivatives License, available at <https://creativecommons.org/licenses/by-nc-nd/4.0/>

Peer reviewed

A case of probable trimethoprim-sulfamethoxazole induced circulating antineutrophil cytoplasmic antibody-positive small vessel vasculitis

Therese Woodring¹, Ronnie Abraham² MD and Stephanie Frisch³ MD

Affiliations: ¹University of Illinois College of Medicine at Peoria, Peoria, Illinois, ²Departments of Pathology and Dermatology, University of Illinois College of Medicine at Peoria, Peoria, Illinois, ³Department of Dermatology, University of Illinois College of Medicine at Peoria, Peoria, Illinois

Corresponding Author: Stephanie Frisch MD, 389 South 900, East, Salt Lake City, UT 84102, Email: stephanie.frisch@imail.org

Abstract

Cutaneous leukocytoclastic vasculitis can occur as skin-limited disease or as part of systemic vasculitis. Appropriate workup includes the evaluation of antineutrophil cytoplasmic antibodies (ANCA), with a positive titer raising concern for the associated primary vasculitides including microscopic polyangiitis, granulomatosis with polyangiitis, or eosinophilic granulomatosis with polyangiitis. In the absence of systemic findings, however, a drug etiology must also be considered. Tumor necrosis factor inhibitors, propylthiouracil, levamisole-adulterated cocaine, hydralazine, and minocycline have been previously documented to induce ANCA-positive vasculitis (APV), which may present with conspicuously high ANCA titers. Herein we report trimethoprim-sulfamethoxazole as another culprit in drug-induced APV. Our case reinforces the need to consider drug etiology for APV and cautions against interpreting positive ANCA as equivalent to evidence of systemic disease.

Keywords: cutaneous leukocytoclastic vasculitis, trimethoprim-sulfamethoxazole, adverse drug reaction, anti-neutrophil cytoplasmic antibodies

Introduction

Cutaneous leukocytoclastic vasculitis (LCV) results from inflammatory destruction of postcapillary venules in the skin. In many cases drug exposure or acute infection leads to antigen excess, the formation of circulating immune complexes, and complement-mediated damage to vessel walls [1]. LCV is defined histologically by an influx of degranulating

neutrophils with fragmented nuclei (leukocytoclasia), endothelial damage, and extravasation of red cells and fibrin [2]. Common drug culprits of LCV include NSAIDs, antibiotics (penicillin and trimethoprim-sulfamethoxazole), and antihypertensives (ACE inhibitors and beta-blockers), [3]. The finding of LCV warrants further investigation via thorough review of systems and additional laboratory testing to exclude a systemic vasculitis [1]. Evaluation for the presence of antineutrophil cytoplasmic antibodies (ANCA) is an essential part of this work up.

A positive ANCA in the setting of LCV elicits strong concern for microscopic polyangiitis (MPA), granulomatosis with polyangiitis (GPA), or eosinophilic granulomatosis with polyangiitis (EGPA). When presented with a lack of evidence of systemic involvement, connective tissue disease and drug-induced disease must also be considered [4]. Tumor necrosis factor (TNF) inhibitors, propylthiouracil, levamisole-adulterated cocaine, hydralazine, and minocycline are the leading agents in drug-induced ANCA-positive vasculitis (APV) [5], which may be associated with particularly high titers of p-ANCA [6]. Trimethoprim-sulfamethoxazole is an established drug cause of LCV. However, to our knowledge it has never been reported as a medication that can induce c-ANCA positive vasculitis.

Case Synopsis

An 83-year-old woman with history of polycythemia vera, recurrent thrombosis, pulmonary embolism, and lumbar compression fractures was admitted to the hospital with rapidly progressive, painful, pruritic and hemorrhagic macules and papules on her extremities. Several weeks previously she had

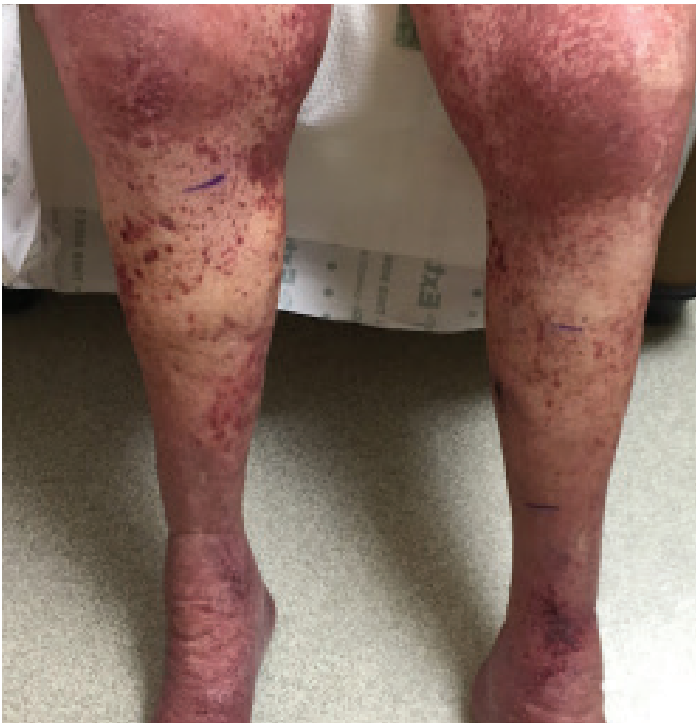

Figure 1. Blanching purpuric macules coalescing into patches with focal hemorrhagic vesicles on medial lower legs.

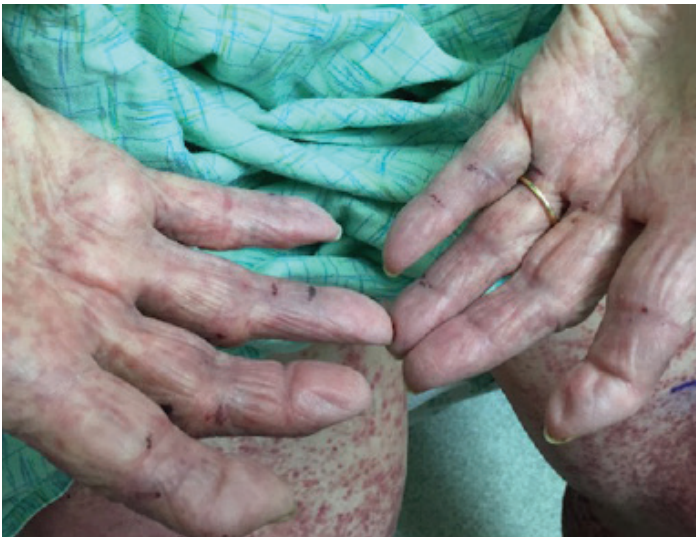

Figure 2. Purpuric macules coalescing into patches on palms.

developed a presumed infection at the inguinal catheterization site for an inferior vena cava (IVC) filter placement. No bacterial culture was performed at the time of antibiotic initiation. A ten-day course of trimethoprim-sulfamethoxazole 800 mg-160 mg 1 tab PO bid (TMP-SMX) was started. Two days after she received TMP-SMX, purpuric macules and thin papules erupted on her feet and spread over the course of the following 6 days proximally to her thighs, trunk, and arms, leading to her admission.

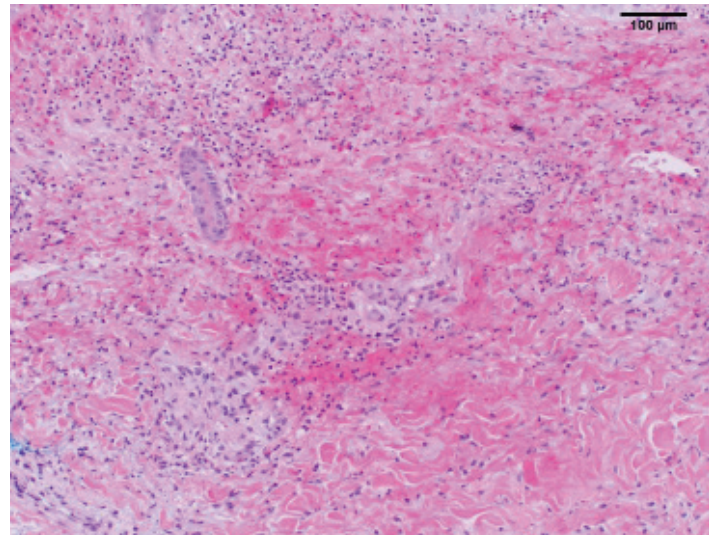


Figure 3. Punch biopsies at the right anterior thigh and pretibial leg showed a perivascular and interstitial inflammatory infiltrate composed of neutrophils and eosinophils, with red cell extravasation, consistent with leukocytoclastic vasculitis (H&E, 10x).

On initial exam, the patient had diffuse non-blanching petechial macules over the lower extremities and flanks and purpuric papules and vesicles over the medial leg. TMP-SMX was discontinued. She was treated with prednisone and dexamethasone for the next 3 days but discontinued owing to concerns regarding her other comorbidities. Despite oral corticosteroid use, the petechiae evolved into confluent purpura with focal vesicles and erosions over the flanks and lower extremities (**Figures 1, 2**). There were no erosions or petechiae on oral exam. Nikolsky sign was negative. Complete blood count, comprehensive metabolic panel, and urinalysis failed to show signs of organ damage. Hepatitis panel was negative. Exhaustive rheumatologic evaluation failed to identify any positive autoimmune antibodies (ANA, ENA, ds-DNA, anti-histone antibody). Two view chest x-ray and a CT angiogram of chest were negative. Given the hemorrhagic appearance and progression of skin lesions, a workup for disseminated intravascular coagulation (DIC) and heparin induced thrombocytopenia (HIT) was performed. Results were indeterminate for HIT antibody but positive by serotonin release assay. Enoxaparin was therefore discontinued and she was bridged to warfarin (coumadin) on argatroban.

Her ANCA immunofluorescence antibody screen was positive for c-ANCA with a notably high titer of >1:5120 (reference <1:20). Punch biopsies at

the right anterior thigh and pretibial leg showed a perivascular and interstitial inflammatory infiltrate composed of neutrophils and eosinophils (eosinophil ratio 4.15, calculated as described in [7]), with red cell extravasation, consistent with leukocytoclastic vasculitis (**Figure 3**). Progression of purpura stabilized in the absence of TMP-SMX with only topical corticosteroids and patient was discharged.

Case Discussion

After exhaustive laboratory work up and multi-specialty evaluation, we believe our patient developed TMX-SMP induced APV associated with positive c-ANCA. The lack of hemoptysis, painful nasal ulceration, or granulomatous inflammation on skin biopsy, as well as her advanced age, normal pulmonary imaging, and normal urinalysis led us to favor drug-induced APV over primary disease such as GPA [8]. Although she suffered from a myeloproliferative disorder (polycythemia vera), the development of clinical signs of LCV within a week of treatment with TMP-SMX, which was the only instance of TMP-SMX exposure on record, provided further support for a drug etiology. Moreover, the tissue eosinophilia on skin biopsy is highly suggestive of drug etiology; four times the mean eosinophil ratio reported for non-drug-induced LCV was noted in our patient's biopsy [7]. Furthermore, the absence of clear fibrinoid necrosis as in our case may be a hallmark of drug-induced small vessel disease [9]. Multiple positive autoantibodies have been described in previous cases of drug-induced APV [5, 10] but are of unknown predictive value and were not observed here. Finally, TMP-SMX has been associated with numerous adverse cutaneous reactions [11] and reported to trigger other diseases with autoantibody formation, such as antiphospholipid antibody syndrome and drug-induced thrombocytopenia [12, 13].

Although ANCA testing can have a 98% positive predictive value for renal manifestations of small vessel vasculitis in a patient with clinical signs of renal disease, the positive predictive value falls to 47% in the absence of hematuria, proteinuria, and creatinine < 1.5 mg/dL [14]. Accordingly, clinicians should resist interpreting ANCAs as proxies for systemic signs, or a substitute for true renal, pulmonary, or head and neck findings. Our case reiterates this need for thoughtful

interpretation of lab results. Despite her positive ANCA result, our patient had no renal or pulmonary manifestations suggesting systemic vasculitis.

The mechanism for autoantibody formation in drug-induced APV remains undetermined. It is also not known whether very high c-ANCA titers are characteristic of drug etiology as may be the case with p-ANCA titers, which in drug-exposed patients can be over 12 times the median titer of patients with APV but no drug exposure [15]. Our case suggests that drug triggers may be more numerous than previously appreciated and that a high c-ANCA titer could raise suspicion for drug etiology.

References

1. James WD, Berger TG, Elston DM. Cutaneous Vascular Diseases: Cutaneous Leukocytoclastic Vasculitis. In James WD, Berger TD, & Elston DM, editors. *Andrews' Diseases of the Skin*. 12th ed: Elsevier, 2016. pp. 830-831.
2. Weedon D. Leukocytoclastic (Hypersensitivity) Vasculitis. In: Weedon D editor. *Weedon's Skin Pathology*. 3rd ed: Elsevier, 2010. pp. 207-9.
3. Bologna JL, Jorizzo JJ, Schaffer JV, editors. *Dermatology*. 3rd ed: Saunders, 2012. p. 351.
4. Tsiveriotis K, Tsirogianni A, Pipi E, et al. Antineutrophil Cytoplasmic Antibodies Testing in a Large Cohort of Unselected Greek Patients. *Autoimmune Dis*. 2011;2011:1-9.[PMID: 21687647].
5. Grau R. Drug-Induced Vasculitis: New Insights and a Changing Lineup of Suspects. *Curr Rheumatol Rep*. 2015; 17(12). [PMID: 26503355].
6. Pendergraft W, Niles J. Trojan horses: drug culprits associated with antineutrophil cytoplasmic autoantibody (ANCA) vasculitis. *Curr Opin Rheumatol*. 2014;26(1):42-49. [PMID: 24276086].
7. Bahrami S, Malone J, Webb K, Callen J. Tissue Eosinophilia as an Indicator of Drug-Induced Cutaneous Small-Vessel Vasculitis. *Arch Dermatol*. 2006;142(2):155-161.[PMID: 16490843].
8. Bloch DA, Michel BA, Hunder GG, et al. The American College of Rheumatology 1990 Criteria for the Classification of Vasculitis. *Arthritis Rheum*. 1990;33(8):1065-67.[PMID: 2390119].
9. Mullick F, McAllister H, Wagner B, Fenoglio J. Drug related vasculitis Clinicopathologic correlations in 30 patients. *Hum Pathol*. 1979; 10(3):313-325. [PMID: 468217].
10. Wiik A. (2008). Drug-induced vasculitis. *Curr Opin Rheumatol*. 2008; 20(1):35-39. [PMID: 18281855].
11. Bactrim and Bactrim DS (sulfamethoxazole and trimethoprim) [package insert]. AR Scientific, Inc., 2013.
12. Silverberg J, Votava H, Smith B. Antiphospholipid antibody syndrome secondary to trimethoprim/sulfamethoxazole. *J Drugs Dermatol*. 2012;11(9):1117-1118.[PMID: 23135659].
13. Nixon C, Cheves T, Sweeney J. Sulfamethoxazole-induced thrombocytopenia masquerading as posttransfusion purpura: a case report. *Transfusion*. 2015;55(11):2738-41.[PMID: 26098194].
14. Jennette J, Wilkman A, Falk R. (1998). Diagnostic predictive value of ANCA serology. *Kidney Int*. 1998;53(3):796-8.[PMID: 9507231].
15. Choi H, Merkel P, Walker A, Niles J. Drug-associated antineutrophil cytoplasmic antibody-positive vasculitis: Prevalence among patients with high titers of antimyeloperoxidase antibodies. *Arthritis & Rheum*. 2000;43(2):405-413.[PMID: 10693882].