

UC Davis
Dermatology Online Journal

Title

Subcorneal pustular dermatosis associated with *Coccidioides immitis*

Permalink

<https://escholarship.org/uc/item/35r6z6bx>

Journal

Dermatology Online Journal, 21(8)

Authors

Iyengar, Sanjana
Chambers, Cindy J
Chang, Shurong
et al.

Publication Date

2015

DOI

10.5070/D3218028426

Copyright Information

Copyright 2015 by the author(s). This work is made available under the terms of a Creative Commons Attribution-NonCommercial-NoDerivatives License, available at <https://creativecommons.org/licenses/by-nc-nd/4.0/>

Peer reviewed

Case presentation

Subcorneal pustular dermatosis associated with *Coccidioides immitis*

Sanjana Iyengar BA¹, Cindy J Chambers MD MPH², Shurong Chang MD PhD², Maxwell A Fung MD^{2,3},
Victoria R Sharon MD DTMH²

Dermatology Online Journal 21 (8): 3

¹Department of Medicine, Florida State University College of Medicine, Tallahassee, FL

²Department of Dermatology, University of California, Davis, Sacramento, CA

³Department of Pathology, University of California, Davis, Sacramento, CA

Correspondence:

Victoria R. Sharon, MD, DTMH
3301 C Street, Suite 1400
Sacramento, CA 95816, USA
Email: vrs2001@gmail.com

Abstract

Coccidioidomycosis (AKA “Valley fever”) is a primary pulmonary infection via airborne spores released from *coccidioides immitis* in the soil. Reactive cutaneous eruptions resulting from the pulmonary infection are difficult to diagnose because skin biopsies do not contain the organism. We present an adolescent male with primary pulmonary *C.immitis* infection manifesting with biopsy proven subcorneal pustular dermatosis. Serological studies revealed increasingly positive titers for coccidioidomycosis and symptoms resolved promptly following initiation of systemic antifungal therapy. Our unique case presentation illustrates subcorneal pustular dermatosis as a reactive eruption owing to primary pulmonary coccidioidomycosis. An association between the two conditions warrants further investigation.

Keywords:Coccidioidomycosis, subcorneal pustular dermatosis

Abbreviation/Acronym List: SPD: subcorneal pustular dermatosis, C.immitis: *Coccidioides immitis*

Introduction

Coccidioidomycosis is a primary pulmonary infection following the inhalation of spores released from *coccidioides immitis* in the soil, most commonly in the southwestern United States, Mexico, and Latin America. Reactive cutaneous eruptions owing to primary pulmonary coccidioidomycosis may be challenging to diagnose because skin biopsies do not contain the organism. Secondary cutaneous eruptions owing to underlying coccidioidomycosis reported thus far include erythema nodosum, acute generalized exanthem, and erythema multiforme. Herein, we present a unique case of subcorneal pustular dermatosis (SPD) in association with acute primary pulmonary coccidioidomycosis.

Case synopsis

A 17-year-old previously healthy male living in Northern California presented to his pediatrician with a pruritic eruption in his right axilla. A brief prednisone taper was prescribed for presumed contact dermatitis. Within days, the eruption generalized to the

remaining folds of the body, trunk, and extremities accompanied by severe headache, high fever, flank and back pain, and tremendous fatigue. Another hospital ruled out meningitis and initiated broad-spectrum antibiotics (doxycycline, ceftriaxone, and levofloxacin). There was no past medical history of psoriasis, atopic dermatitis, or blistering skin disease. The patient had recently been camping and hiking in Central and Northern California, but denied any known tick or animal bite.

On physical examination, brightly erythematous plaques of superficial exfoliation were noted in flexural areas of the upper extremities and flank with discrete collarettes of scale on the scalp. At the time of dermatology consultation, few clinically discernable intact pustules remained.

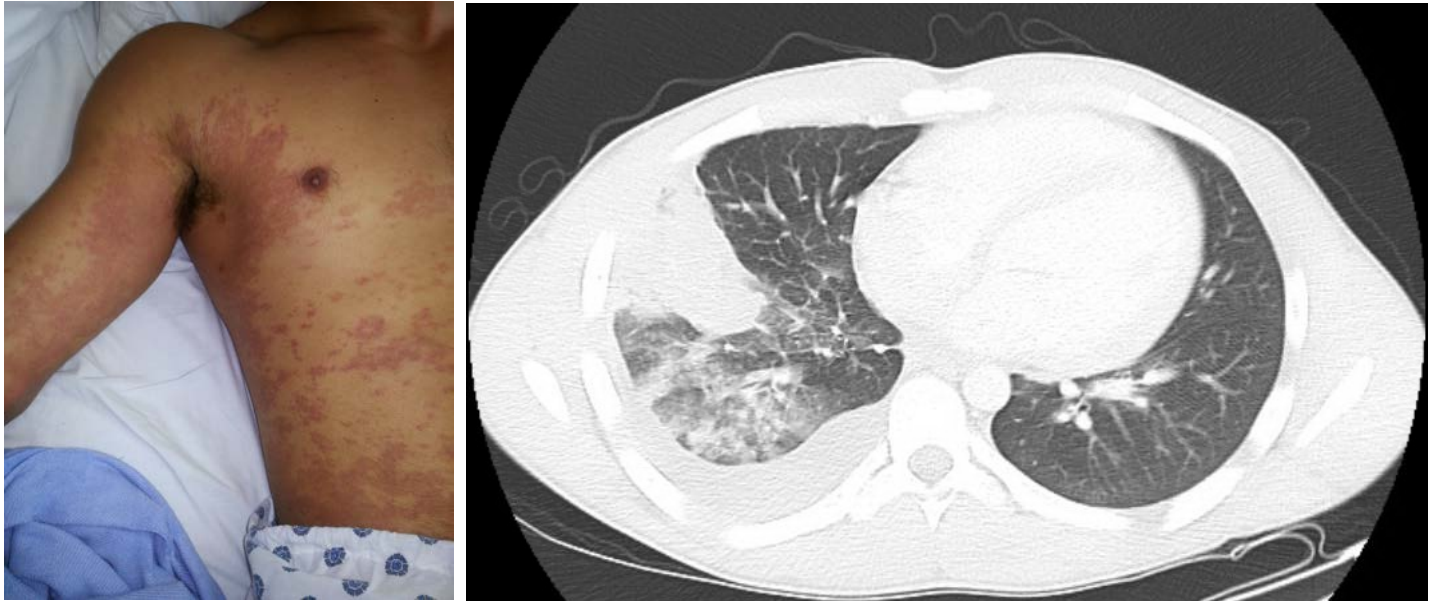

Figure 1. Erythematous plaques of superficial exfoliation noted in flexural areas of the upper extremities and flank. **Figure 2.** CT scan demonstrating right middle and lower lobe infiltrates and consolidation

Serologies for Epstein-Barr virus, mycoplasma, herpes simplex virus, and syphilis were unremarkable; they were slightly above normal for Rocky Mountain spotted fever. Quantiferon-TB Gold test was negative for latent tuberculosis. Despite empiric therapy with doxycycline for Rocky Mountain spotted fever, the patient continued to spike daily fevers and developed a cough on day 5 of hospitalization. Chest X-ray and follow-up CT scan revealed right lower and middle lobe infiltrates and consolidation with reactive hilar adenopathy.

A punch biopsy on the right thigh was performed and revealed subcorneal neutrophilic pustules. Direct immunofluorescence and Periodic acid-Schiff-diastase (PAS-D) stain were negative. Deeper tissue levels were examined without evidence of fungal organisms.

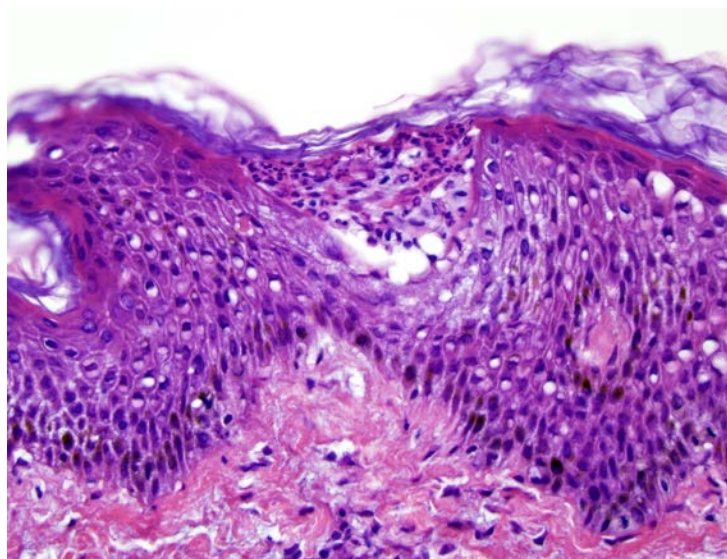


Figure 3. Subcorneal neutrophilic pustules noted on high power magnification (hematoxylin & eosin stain, 40X)

Preliminary coccidioidal serology was positive for IgM. Fluconazole was initiated, leading to resolution of fever within 48 hours. A four-fold rise in *C. immitis* complement fixation titers (to 1:16) was noted four weeks later, confirming a diagnosis of primary pulmonary coccidioidomycosis. He was continued on fluconazole for a planned 6 month course.

Discussion

Coccidioides immitis is endemic in the regions of the southwestern United States including the San Joaquin and Central California Valleys, Mexico, and Latin America with skin findings almost universally secondary to primary pulmonary infection [1]. These skin findings may either represent dissemination of *C. immitis* to the skin, but more often represent a secondary reactive phenomenon. Dissemination of organisms to the skin and other organs occurs in 0.5%-1.5% of infected individuals, may manifest as papules, plaques, indurated subcutaneous nodules, abscesses, or ulcers, and can be confirmed via biopsy [1-3].

Unlike disseminated lesions, reactive eruptions owing to underlying coccidioidomycosis infection contain no viable organisms [4]. It has been reported that 12% of patients with symptomatic pulmonary coccidioidomycosis develop a generalized toxic erythema [2]. Cutaneous manifestations may develop either as the initial sign of infection or several weeks to months following pulmonary complications.

Histopathological evaluation of primary cutaneous lesions reveals characteristic endosporeulating spherules (10-80um) with refractile cell walls and lacy gray or granular cytoplasm diagnostic of *Coccidioides immitis*. Inflammatory infiltrates are typically mixed with polymorphonuclear cells and multinucleated giant cells [1, 3], which may be accompanied by pseudoepitheliomatous hyperplasia [1, 5]. Chest X-ray, tissue culture, serology, and skin testing may additionally be used to aid in diagnosis [4]. Serology is useful in the diagnosis of coccidioidomycosis in immunocompetent patients with complement fixation in a dilution greater than 1:16 in patients with extensively disseminated infection [3]. Detection of antibodies in immunosuppressed patients, however, is often difficult with a 20-50% false negative rate [6].

Although mild clinical or subclinical infections may resolve spontaneously, patients with severe pneumonia and chronic pulmonary or disseminated disease warrant systemic antifungal therapy, such as amphotericin B, fluconazole, or itraconazole. Given a high risk of relapse, treatment of these individuals is typically prolonged for up to two years or lifelong in immunocompromised patients and requires follow-up with an infectious disease specialist [6].

Subcorneal pustular dermatosis, also known as Sneddon-Wilkinson disease, is a common skin disease presenting with sterile flaccid subcorneal pustules primarily on the trunk and skin folds [7]. Although the pathophysiology of SPD is not well understood, it has been associated with monoclonal IgA paraproteinemia, inflammatory bowel disease, rheumatoid arthritis, and mycoplasma infection [7].

Conclusion

This case presents a unique presentation of subcorneal pustular dermatosis in the setting of acute pulmonary coccidioidomycosis. As the diagnosis of coccidioidomycosis was not initially suspected in this patient due to delayed pulmonary symptoms, our differential diagnosis of generalized subcorneal pustules was broad and included drug reaction (acute generalized exanthematous pustulosis), pustular psoriasis, IgA pemphigus, and fungal or bacterial infection. Given the appropriate clinical context, however, it is important to include underlying coccidioidomycosis in the differential diagnosis. Recent travel and current residence should be elicited to evaluate for *C. immitis* exposure with early treatment to reduce complications. The association of subcorneal pustular dermatosis as a reactive eruption related to primary pulmonary coccidioidomycosis warrants further investigation.

References

1. Carpenter JB, Feldman JS, Leyva WS, DiCaudo DJ. Clinical and pathologic characteristics of disseminated cutaneous coccidioidomycosis. *J Am Acad Dermatol.* 2010 May; 62(5): 831-7 [PMID: 20398813]
2. Chen CM, Lee HE, and Li SY. Coccidioidomycosis with cutaneous manifestation of erythema nodosum in Taiwan. *Dermatologica Sinica.* 2010 Dec; 28(4): 154-158 [PMID: unavailable]
3. Wilson JW, Smith CE, and Plunkett OA. Primary cutaneous coccidioidomycosis; the criteria for diagnosis and a report of a case. *Calif Med.* 1953 Sep; 79(3): 233-9 [PMID: 13082426]
4. DiCaudo DJ. Coccidioidomycosis: a review and update. *J Am Acad Dermatol.* 2006 Dec; 55(6): 929-42; quiz 943-5 [PMID: 17110216]
5. Quimby SR, Connolly SM, Winkelmann RK, Smilack JD. Clinicopathologic spectrum of specific cutaneous lesions of disseminated coccidioidomycosis. *J Am Acad Dermatol.* 1992 Jan; 26(1): 79-85 [PMID: 1732341]

6. Galgiani JN, Ampel NM, Blair JE, Catanzaro A, Johnson RH, Stevens DA, Williams PL; Infectious Diseases Society of America. Coccidioidomycosis. *Clinical Infectious Disease*. 2005 Nov; 41(9): 1217-1223 [PMID: 16206093]
7. Lombart F, Dhaille F, Lok C, Dadban A. Subcorneal pustular dermatosis associated with *Mycoplasma pneumoniae* infection. *J Am Acad Dermatol*. 2014 Sep; 71(3): e85-6 [PMID: 25128138]