

UC Davis

Dermatology Online Journal

Title

Use of an oral phosphodiesterase-4 inhibitor (apremilast) for the treatment of chronic, severe atopic dermatitis: a case report

Permalink

<https://escholarship.org/uc/item/3588p0hn>

Journal

Dermatology Online Journal, 23(5)

Authors

Farahnik, Benjamin
Beroukhim, Kourosh
Nakamura, Mio
[et al.](#)

Publication Date

2017

DOI

10.5070/D3235034926

Copyright Information

Copyright 2017 by the author(s). This work is made available under the terms of a Creative Commons Attribution-NonCommercial-NoDerivatives License, available at <https://creativecommons.org/licenses/by-nc-nd/4.0/>

Peer reviewed

Use of an oral phosphodiesterase-4 inhibitor (apremilast) for the treatment of chronic, severe atopic dermatitis: a case report

Benjamin Farahnik¹ BA, Kourosh Beroukhim² MD, Mio Nakamura³ MD, Michael Abrouk⁴ BS, Tian Hao Zhu⁵ BA, Rasnik Singh² BS, Kristina Lee³ BA, Tina Bhutani³ MD, John Koo³ MD, Wilson Liao³ MD

Affiliations: ¹University of Vermont College of Medicine, Burlington, Vermont ²University of California – Los Angeles, David Geffen School of Medicine, Los Angeles, California ³University of California – San Francisco, Department of Dermatology, Psoriasis and Skin Treatment Center, San Francisco, California ⁴University of California – Irvine, School of Medicine, Irvine, California ⁵University of Southern California Keck School of Medicine, Los Angeles, California

Corresponding Author: Benjamin Farahnik Department of Dermatology, University of California, San Francisco 515 Spruce St. San Francisco, CA 94118 Tel. 310-923-3278 Fax. 415-502-4126 Email: Benjamin.farahnik@med.uvm.edu

Abstract

Atopic dermatitis (AD) is a common inflammatory dermatosis characterized by pruritus, erythema, induration, and lichenification. Current treatment options for generalized atopic dermatitis are limited and have potentially serious adverse effects, especially in patients with severe, chronic AD who frequently require systemic anti-inflammatory agents. Apremilast, an oral phosphodiesterase-4 inhibitor, was FDA approved in September 2014 for the treatment of moderate-to-severe plaque psoriasis. However, its upstream anti-inflammatory effects, ease of use as an oral agent, and mild side-effect profile make it an interesting treatment option for AD as well. Herein, we present a patient with a life-long history of AD recalcitrant to topical steroids and cyclosporine who attained subjective and objective improvement in pruritus and erythema after 10-week treatment with apremilast.

Keywords: atopic dermatitis, eczema, apremilast, otezla, EASI, phosphodiesterase-4

Introduction

Atopic dermatitis (AD) is a chronic, inflammatory dermatosis that affects up to 25% of children and 2-3% of adults [1]. It is characterized by pruritus, erythema, induration, and lichenification. A significant proportion of patients with AD remain

undertreated relative to the severity of their disease. Current treatment options for generalized atopic dermatitis such as cyclosporine, azathioprine, mycophenolate mofetil, and methotrexate have potentially serious adverse side effects. Apremilast, an oral phosphodiesterase-4 (PDE4) inhibitor approved for moderate-to-severe plaque psoriasis, provides an interesting alternative treatment option for AD owing to its upstream anti-inflammatory effects. Herein, we present a patient with a life-long history of AD recalcitrant to topical corticosteroids and cyclosporine who attained subjective and objective improvement in pruritus and erythema after 10-week treatment with apremilast.

Case Synopsis

A 55-year-old man with a life-long history of allergies, asthma, and generalized severe AD presented to clinic with worsening AD flares of increasing frequency. He also had a 6 month history of patchy hair loss clinically consistent with new-onset alopecia areata. He had previously failed several therapies for his AD including topical therapies (including class I topical corticosteroids, calcineurin inhibitors, and coal tar) and had required multiple courses of oral prednisone. He was unable to tolerate cyclosporine owing to gastrointestinal discomfort and refused other systemic agents for fear of the same side-effect profile. The patient was also unable to receive regular phototherapy or Goeckerman treatments because of time conflicts with work. Physical exam revealed generalized lichenified, erythematous plaques with

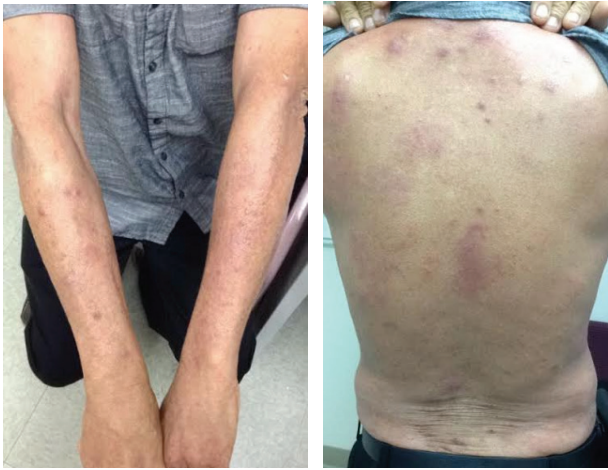

Figure 1. Patient's arms (left) and back (right) prior to treatment with apremilast showing generalized erythematous and lichenified plaques.

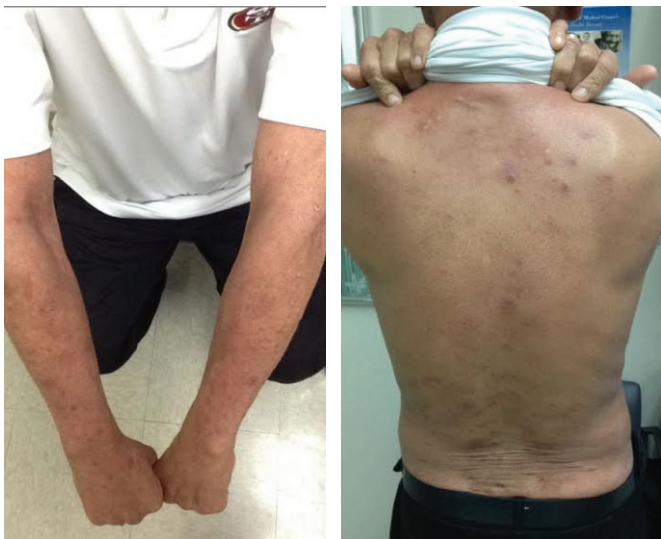

Figure 2. Patient's arms (left) and back (right) 10 weeks into treatment with apremilast. Decrease in erythema, but persistent hyperpigmentation and lichenification are observed.

overlying excoriations on face, neck, arms, back, and legs (**Figure 1**). There was patchy hair loss on his scalp. The decision was made to start the patient on apremilast 30 mg BID. Topical treatments remained unchanged. Four weeks into apremilast therapy, the patient noted subjective improvement in pruritus. There were some visual signs of improvement on skin examination. Ten weeks into apremilast therapy, substantial decrease in erythema was observed, but with persistent hyperpigmentation and lichenification (**Figure 2**). There was also stabilization of hair loss and some hair regrowth of the scalp. Of note, the patient complained of occasional nausea and gas that was tolerable and decreased over time.

Case Discussion

AD is a chronic inflammatory skin condition caused by activation of the T-helper 2 pathway, which releases various inflammatory cytokines. Current treatment options for severe, chronic AD are limited, especially in patients with generalized AD whose symptoms often cannot be controlled solely with topical agents. The most widely utilized systemic treatment options for severe AD are systemic corticosteroids, cyclosporine, azathioprine, and methotrexate, which have potential adverse effects such as immunosuppression and end-organ damage [2]. Phototherapy and Goeckerman therapy, though effective, are not always feasible options owing to inconvenience to patients, as was the case in our patient. Apremilast was FDA-approved in March 2014 for the treatment of psoriatic arthritis and in September 2014 for the treatment of moderate-to-severe plaque psoriasis [3]. Phase III studies have shown 75% improvement in the Psoriasis Area Severity Index (PASI-75) in about 33% of patients [4]. Apremilast is generally well tolerated; the most common adverse side effects include nausea, diarrhea, upper respiratory tract infection, headache, and nasopharyngitis [4].

Although the complete mechanism by which apremilast treats AD has not yet been elucidated, it appears to have many anti-inflammatory effects. Since the 1980s, studies have shown increased levels of phosphodiesterase type 4 (PDE4) in patients with AD [5, 6]. PDE4 is an isoenzyme that converts cyclic adenosine monophosphate (cAMP) to adenosine monophosphate. Apremilast, a novel oral inhibitor of PDE4, directly affects multiple immune cells, including monocytes, dendritic cells, neutrophils, T cells, natural killer cells, and macrophages and likely returns these immune cells to a less active state (**Figure 3**) [7]. It causes an accumulation of cAMP, which in turn activates protein kinase A and other downstream effectors, resulting in the reduction of tumor necrosis factor, interleukin-2, interferon- α , several leukotrienes, and nitric oxide synthase [7, 8].

Topical phosphodiesterase inhibitors have been developed and shown clinically useful in patients with AD [9, 10]. Research into the use of apremilast for the treatment of severe AD in humans has been limited, with only one pilot study [11] and one

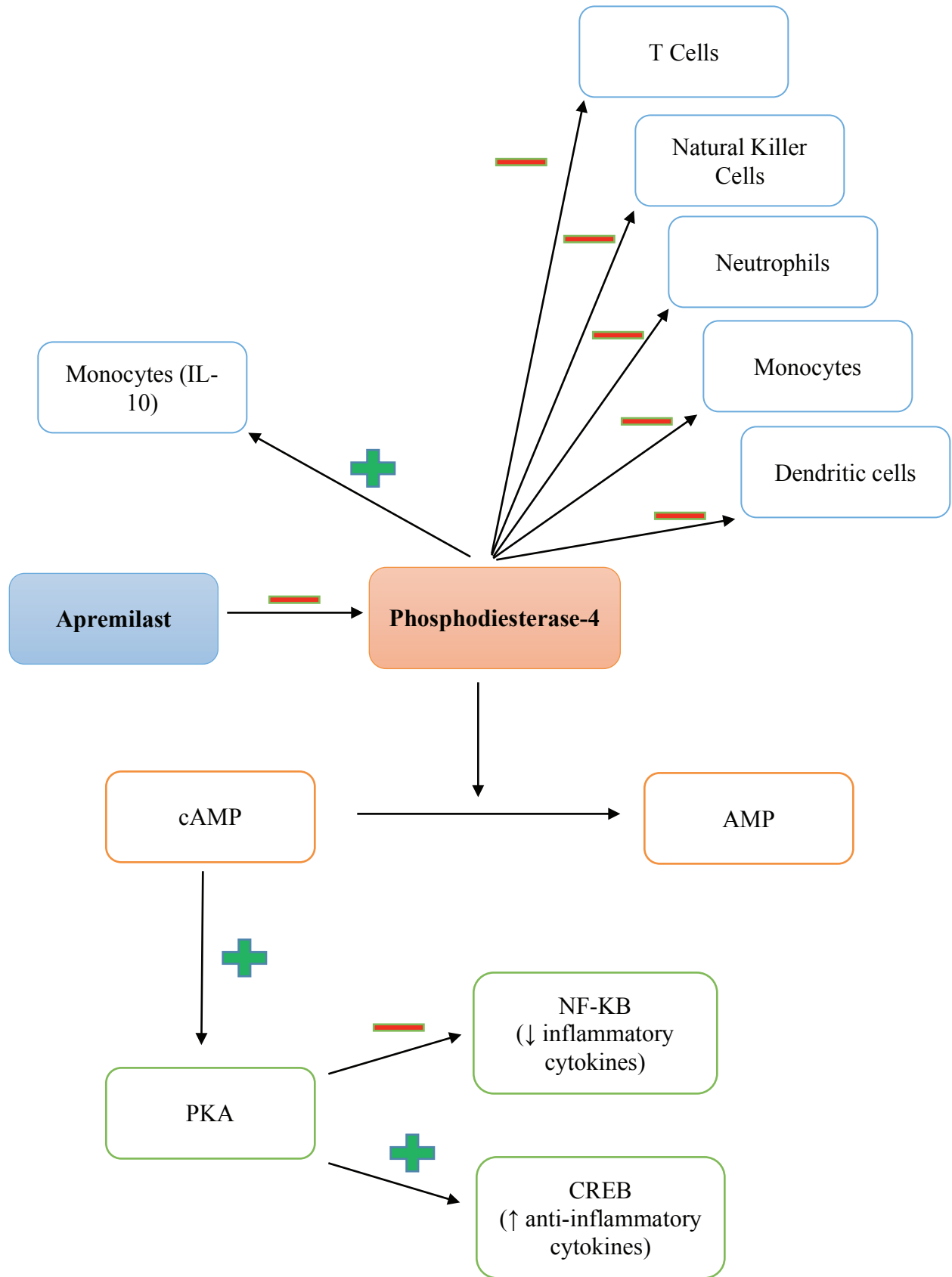


Figure 3. Patient's arms (left) and back (right) 10 weeks into treatment with apremilast. Decrease in erythema, but persistent hyperpigmentation and lichenification are observed.

open-label, investigator-initiated phase 2 study [12] at the time this manuscript was written. The pilot study by Samrao et al. showed that after 3 months of treatment, moderate-to-severe AD patients taking apremilast 20 mg twice daily had a significant reduction from baseline of pruritus ($p=0.021$) and dermatology life quality index (DLQI) ($p=0.003$), and those taking 30 mg twice daily had a significant reduction of the Eczema Area Severity Index (EASI) ($p=0.008$) and the DLQI ($p=0.012$) [11]. Significant improvement was maintained in all outcomes after six months of treatment. In the phase 2 study by Volf et al. apremilast was not shown to be as effective, with only 20% of subjects achieving investigator global assessment improvement of 2 or more, and 20% achieving 75% reduction in EASI or 50% reduction in EASI, 10% each [12]. Of note, however, subjects had either recalcitrant AD or allergic contact dermatitis and the sample size was small, with only 10 patients. Apremilast was well tolerated by all subjects in both trials.

Apremilast may have lower efficacy than current systemic agents such as cyclosporine, phototherapy, or Goeckerman therapy, which can achieve greater than 90% skin clearance and very low erythema and pruritus scores [13]. However, its ease of administration as an oral agent coupled with a relatively safe side-effect profile that has yet to show clinical signs of immunosuppression or major organ toxicities, make it an interesting option for AD treatment. Increased research into the pathogenesis of AD has led to the development of even more novel biologic agents, such as dupilumab. Dupilumab is a fully-human monoclonal antibody directed against the IL-4 receptor α subunit, blocking signaling of both IL-4 and IL-13, key Th2 cytokines. In phase II studies, dupilumab has demonstrated EASI score improvements in all regimens versus placebo ($p<0.0001$), [14].

Conclusion

We report the successful use of apremilast with traditional topical agents in the treatment of a patient with recalcitrant AD. Although we report only one patient, early observation suggests clinically meaningful improvement in several disease parameters including symptomatic and visual improvement. Larger controlled phase III studies are

necessary to further assess the safety and efficacy of apremilast in treating AD.

List of Abbreviations

AD – Atopic Dermatitis
PASI – Psoriasis Area Severity Index
PDE4 – Phosphodiesterase-4
cAMP – Cyclic adenosine monophosphate
IL – Interleukin
DLQI – dermatology life quality index
EASI – Eczema Area Severity Index

Disclosures

Dr. John Koo is a speaker for AbbVie, Leo, and Celgene. Dr. Koo conducts research for Amgen, Janssen, Novartis, Photomedex, Galderma, Pfizer and Merck. Dr. Tina Bhutani is an advisor for Cutanea. Dr. Bhutani conducts research for Abbvie, Janssen, and Merck. Dr. Wilson Liao receives research grants from Abbvie, Janssen, Novartis, and Pfizer. Dr. Liao receives funding from the NIH (R01AR065174, U01AI119125). Dr. Koo, Dr. Bhutani, and Dr. Liao have no stocks, employment or board memberships with any pharmaceutical company. Mr. Benjamin Farahnik, Dr. Mio Nakamura, Mr. Michael Abrouk, Mr. Henry Zhu, Ms. Rasnik Singh, and Ms. Kristina Lee have nothing to disclose.

References

1. Sidbury, R., et al., Guidelines of care for the management of atopic dermatitis: section 3. Management and treatment with phototherapy and systemic agents. *J Am Acad Dermatol*, 2014. 71(2): p. 327-349. [PMID: 24813298]
2. Schmitt, J., et al., Systemic treatment of severe atopic eczema: a systematic review. *Acta Derm Venereol*, 2007. 87(2): p. 100-111. [PMID: 17340015] Available from: http://www.accessdata.fda.gov/drugsatfda_docs/label/2014/206088s000lbl.pdf. Accessed on September 26, 2016.
3. Papp, K., et al., Apremilast, an oral phosphodiesterase 4 (PDE4) inhibitor, in patients with moderate to severe plaque psoriasis: Results of a phase III, randomized, controlled trial (Efficacy and Safety Trial Evaluating the Effects of Apremilast in Psoriasis [ESTEEM] 1). *J Am Acad Dermatol*, 2015. 73(1): p. 37-49. [PMID: 26089047]
4. Grewe, S.R., S.C. Chan, and J.M. Hanifin, Elevated leukocyte cyclic AMP-phosphodiesterase in atopic disease: a possible mechanism for cyclic AMP-agonist hyporesponsiveness. *J Allergy Clin Immunol*, 1982. 70(6): p. 452-457. [PMID: 6128357]
5. Chan, S.C., et al., Immunochemical characterization of the distinct monocyte cyclic AMP-phosphodiesterase from patients with atopic dermatitis. *J Allergy Clin Immunol*, 1993. 91(6): p. 1179-1188. [PMID: 8389777]
6. Schafer, P.H., et al., Apremilast is a selective PDE4 inhibitor with regulatory effects on innate immunity. *Cell Signal*, 2014. 26(9): p. 2016-2029. [PMID: 24882690]
7. Gottlieb, A.B., et al., An open-label, single-arm pilot study in patients with severe plaque-type psoriasis treated with an oral

- anti-inflammatory agent, apremilast. *Curr Med Res Opin*, 2008. 24(5): p. 1529-1538. [PMID: 18419879]
8. Griffiths, C.E., et al., Randomized comparison of the type 4 phosphodiesterase inhibitor cipamfylline cream, cream vehicle and hydrocortisone 17-butyrate cream for the treatment of atopic dermatitis. *Br J Dermatol*, 2002. 147(2): p. 299-307. [PMID: 12174103]
 9. Hanifin, J.M., et al., Type 4 phosphodiesterase inhibitors have clinical and in vitro anti-inflammatory effects in atopic dermatitis. *J Invest Dermatol*, 1996. 107(1): p. 51-56. [PMID:8752839]
 10. Samrao, A., et al., A pilot study of an oral phosphodiesterase inhibitor (apremilast) for atopic dermatitis in adults. *Arch Dermatol*, 2012. 148(8): p. 890-897. [PMID: 22508772]
 11. Volf, E.M., et al., A phase 2, open-label, investigator-initiated study to evaluate the safety and efficacy of apremilast in subjects with recalcitrant allergic contact or atopic dermatitis. *J Drugs Dermatol*, 2012. 11(3): p. 341-346. [PMID:22395585]
 12. Dennis, M., et al., Goeckerman Therapy for the Treatment of Eczema: A Practical Guide and Review of Efficacy. *J Dermatolog Treat*, 2013. 24(1): p. 2-6. [PMID: 21797807]
 13. Thaci, D., et al., Efficacy and safety of dupilumab in adults with moderate-to-severe atopic dermatitis inadequately controlled by topical treatments: a randomised, placebo-controlled, dose-ranging phase 2b trial. *Lancet*, 2016. 387(10013): p. 40-52. [PMID: 26454361]