

UC Davis

Dermatology Online Journal

Title

Eccrine hidrocystomas presenting as multiple papules on the cheeks

Permalink

<https://escholarship.org/uc/item/2w55q440>

Journal

Dermatology Online Journal, 19(8)

Authors

Jabbar, Ahmad S.
Matinpour, Keyan
Orengo, Ida
[et al.](#)

Publication Date

2013

DOI

10.5070/D3198019269

Copyright Information

Copyright 2013 by the author(s). This work is made available under the terms of a Creative Commons Attribution-NonCommercial-NoDerivatives License, available at <https://creativecommons.org/licenses/by-nc-nd/4.0/>

Peer reviewed

Case presentation

Eccrine hidrocystomas presenting as multiple papules on the cheeks

Ahmad S. Jabbar MD¹, Keyan Matinpour MD¹, Ida Orengo MD¹, Paul M. Rodriguez-Waitkus MD², Abdul H. Diwan MD², Kiran Motaparathi MD¹

Dermatology Online Journal 19 (8): 11

Baylor College of Medicine, Departments of Dermatology¹ and Pathology², Houston, Texas

Correspondence:

Kiran Motaparathi MD
Assistant Professor, Dept. of Dermatology
Baylor College of Medicine
1977 Butler Blvd, Ste. E6.200
Houston, TX 77030
Email: motapart@bcm.edu

ABSTRACT

Hidrocystomas are common, benign adnexal neoplasms most frequently found on the eyelids, canthi, or periorcular areas. Herein, we report a case of multiple hidrocystomas distributed over less common facial areas: cheeks and cutaneous lips.

CASE REPORT

A 53-year-old woman presented with 10 to 15-year history of multiple asymptomatic papules on the face. Physical exam disclosed approximately 20-30 translucent blue-grey papules on the cheeks, melolabial folds, and the upper cutaneous lip (Figure 1). Shave biopsy was performed. Histopathologic examination revealed unilocular cystic spaces lined by eccrine epithelium with two layers of cuboidal cells (Figures 2 and 3).

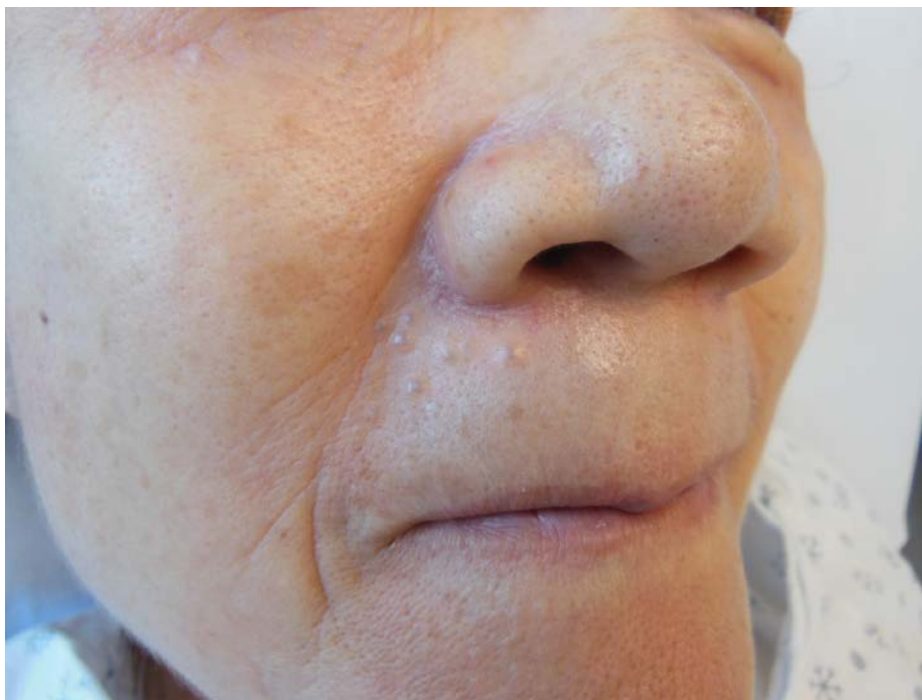

Figure1. Multiple blue-grey, translucent papules on the cheeks and upper cutaneous lip

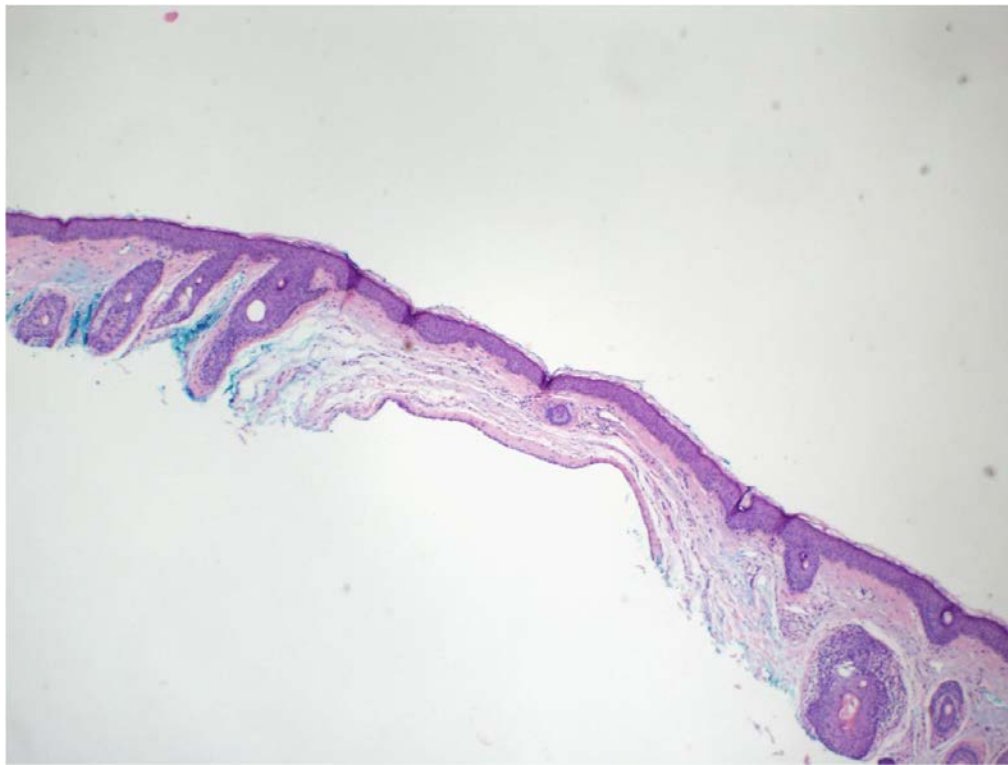

Figure 2. Eccrine hidrocystoma, low-power view: unilocular cystic cavity

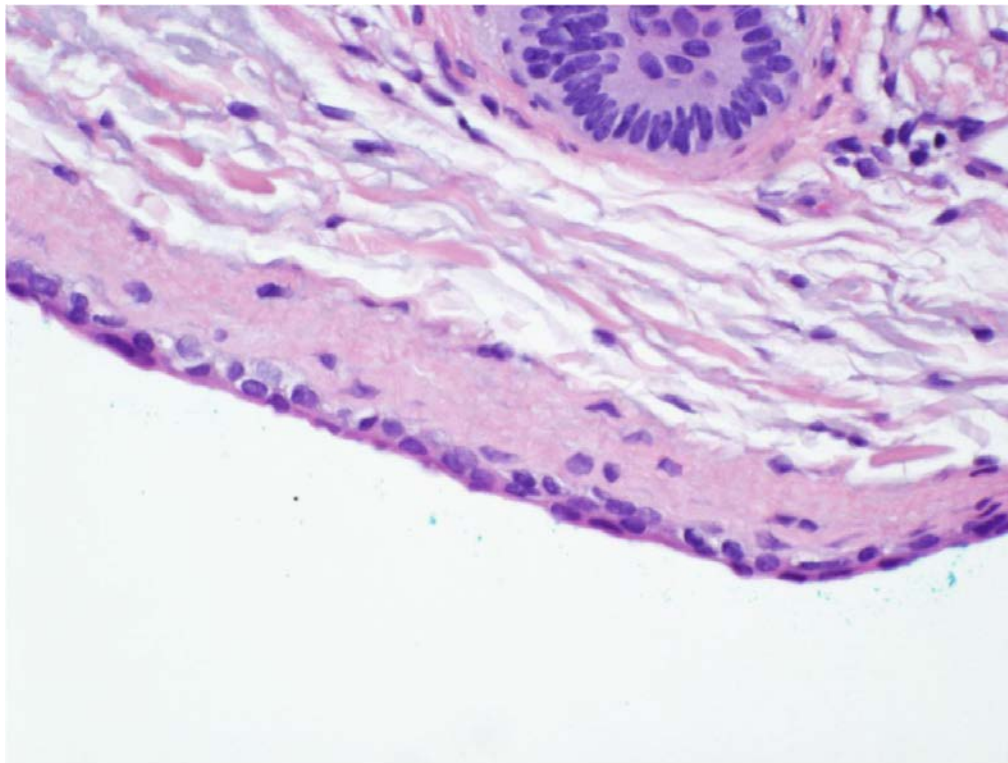


Figure 3. Eccrine hidrocystoma, high-power view: cystic cavity lined by two layers of cuboidal-columnar cells

DISCUSSION

Hidrocystomas (also known as cystadenomas, sudoriferous cysts, and Moll's gland cysts) are adenomas of the sweat (apocrine or eccrine) glands. They are more common in adult women and can become more prominent in warm environments [4]. They typically present as blue-gray, translucent, solitary papules in the periocular areas (especially eyelids and canthi) and range from 1 to 6 millimeters in size [4]. In some patients, multiple lesions may be seen [4]. Apocrine lesions are less likely to occur than eccrine lesions in the periocular areas [1]. Their clinical resemblance to basal cell carcinomas sometimes requires histopathologic examination for distinction.

Rare syndromes associated include Goltz syndrome (focal dermal hypoplasia) and Schopf-Schulz-Passarge syndrome (SSPS). Goltz syndrome usually occurs sporadically in females, with some cases demonstrating X-linked dominant transmission [2]. Features include multiple periocular hidrocystomas, facial and genital papillomas, dermal hypoplasia, ectrodactyly, and mental retardation [2]. Schopf-Schulz-Passarge syndrome (SSPS) presents in adulthood with multiple apocrine hidrocystomas of the eyelids [4]. Additional features of SSPS include onychodystrophy, hypotrichosis, hypodontia, palmoplantar keratoderma, and multiple palmoplantar syringofibroadenomas [3, 4].

Histologic evaluation of apocrine hidrocystoma demonstrates a single cystic cavity lined by two layers of small cuboidal-columnar epithelial cells, along with decapitation secretion [4]. In contrast, eccrine hidrocystomas lack decapitation secretion and are more likely to be multilocular than apocrine hidrocystomas [5].

Solitary lesions can be treated by excision [4]. For multiple lesions, destructive modalities such as laser surgery (with CO₂ or pulsed dye lasers) or electrodesiccation may also be effective [4]. Topical atropine ointment 1% or scopolamine cream 0.01% (1.2 mL of 0.25% scopolamine eyedrops in 30 g of emollient cream) applied once daily has been used with variable success in patients with multiple lesions, although anticholinergic side effects such as mydriasis may occur [4]. Botulinum toxin is another therapeutic option [4]. Oral glycopyrrolate, 1 mg twice daily, may be useful in suppressing exercise- and heat-induced enlargement of hidrocystomas [4].

This case demonstrates that hidrocystomas should be considered in the differential diagnosis in patients presenting with multiple adnexal tumors. Despite an atypical distribution, the blue-grey, translucent appearance of these lesions is helpful in making the correct diagnosis.

REFERENCES

1. Alfadley A, Al Aboud K, Tulba A, Mazen M. Multiple eccrine hidrocystomas of the face. *Int J Dermatol*. 2001 Feb;40(2):125–9. [PMID:11328394]
2. Ascherman JA, Knowles SL, Troutman KC. Extensive facial clefting in a patient with Goltz syndrome: multidisciplinary treatment of a previously unreported association. *Cleft Palate Craniofac J*. 2002 Jul;39(4):469–73. [PMID:12071796]
3. Gira AK, Robertson D, Swerlick RA. Multiple eyelid cysts with palmoplantar hyperkeratosis—quiz case. *Arch Dermatol*. 2004 Feb;140(2):231–6. [PMID:14967804]
4. James WD, Berger TG, Elston DM. In: *Andrews' Diseases of the Skin, Clinical Dermatology*, 11th ed. Philadelphia: Elsevier, 2011:654.
5. Kaur C, Sarkar R, Kanwar AJ, Mohan H. Multiple eccrine hidrocystomas. *J Eur Acad Dermatol Venereol*. 2002 May;16(3):288–90. [PMID:12195577]