

UC Davis

Dermatology Online Journal

Title

Persistent generalized Grover disease: complete remission after treatment with oral acitretin

Permalink

<https://escholarship.org/uc/item/2vm7509r>

Journal

Dermatology Online Journal, 25(3)

Authors

Pasmatzi, Efstathia
Kousparos, George
Mytidou, Chrystalla
et al.

Publication Date

2019

DOI

10.5070/D3253043336

Copyright Information

Copyright 2019 by the author(s). This work is made available under the terms of a Creative Commons Attribution-NonCommercial-NoDerivatives License, available at <https://creativecommons.org/licenses/by-nc-nd/4.0/>

Peer reviewed

Persistent generalized Grover disease: complete remission after treatment with oral acitretin

Efstathia Pasmatzis¹ MD PhD, George Kousparos² MBBS MRCPATH, Chrystalla Mytidou³ MSc, Nayia Nicolaou³ PhD, George A Tanteles³ MD MRCPCH DM, George Badavanis⁴ MD PhD, Alexandra Monastirli^{1,4} MD PhD, Dionysios Tsambaos^{1,4} MD PhD

Affiliations: ¹Department of Dermatology, School of Medicine, University of Patras, Patras, Greece, ²Department of Histopathology, Frimley Park Hospital, NHS Foundation Trust, Camberley, United Kingdom, ³Clinical Genetics Clinic, The Cyprus Institute of Neurology & Genetics, Nicosia, Cyprus, ⁴Center for Dermatologic Diseases, Limassol, Cyprus

Corresponding Author: Efstathia Pasmatzis MD PhD, Department of Dermatology, School of Medicine, University of Patras, Rio-Patras 26504, Greece, Tel: 30-2610 270 577, Fax: 30 2610 270 235, Email: pasmatzis@otenet.gr, pasmatzis@med.upatras.gr

Abstract

Grover disease (GD) is a disorder of unknown origin, clinically characterized by the occurrence of pruritic, erythematous or brownish papules and papulovesicles, which histologically reveal four different patterns of acantholysis. Usually, the eruption is self-limited and spontaneously remit within a few weeks. In some cases, however, it may persist for months or even years and show a therapy-resistant course. We report a 56-year-old woman with recalcitrant, persistent, and generalized GD who showed complete remission after 6 weeks of treatment with oral acitretin (0.8mg/kg/day). The treatment was well-tolerated and laboratory parameters remained unchanged. The patient remains free of any recurrence at 26 months. To the best of our knowledge, this is the first report of a complete remission of the persistent form of GD as a result of oral acitretin monotherapy.

Keywords: Grover disease, acitretin, retinoids

Introduction

Transient acantholytic dermatosis was described for the first time by Ralph Grover in 1970 and bears his name (Grover disease), [1]. It is characterized by the occurrence of pruritic erythematous or brownish papules and papulovesicles on the trunk and the proximal extremities, particularly in middle-aged and elderly males [2]. Usually, the eruption is self-limiting, revealing a spontaneous remission within a

few weeks. In some cases, however, it may persist for months or even years and show a therapy-resistant course [3, 4]. Thus, in view of the potential persistent character of the eruption, it seems that the term Grover disease is more appropriate than the misleading original one, transient acantholytic dermatosis.

In the last three decades, the dramatic efficacy of oral acitretin (representative of the second retinoid generation) in the systemic treatment of severe and recalcitrant keratinization disorders has been established in numerous clinical trials [5]. In contrast to its usually mild mucocutaneous side effects, which are common or relatively common, the systemic adverse reactions of acitretin are uncommon or rare and include teratogenicity, hyperlipidemia, hepatotoxicity, intracranial hypertension, myopathy, and peripheral neuropathy [6].

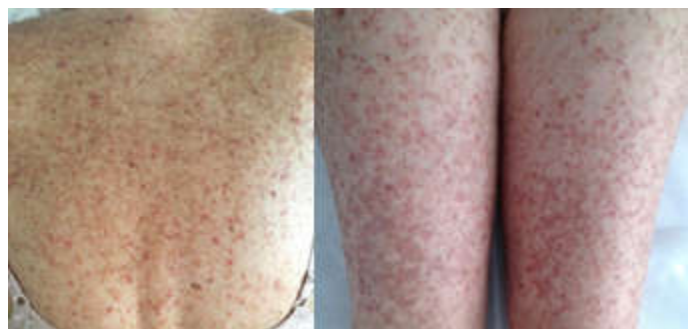

Figure 1. Brownish hyperkeratotic papules and papulovesicles on the back and the lower extremities prior to onset of acitretin monotherapy.

Herein, we report a patient with recalcitrant, persistent, and generalized GD who showed complete remission after 6 weeks of monotherapy with oral acitretin.

Case Synopsis

A 56-year-old HIV-negative and otherwise healthy woman with a 5-month-history of generalized pruritic skin lesions presented to the Center for Dermatologic Diseases in Limassol, Cyprus. Her personal and family medical history for cutaneous or genetic diseases was unremarkable. She had received no systemic or topical drugs, phototherapy or photochemotherapy prior to the occurrence of the eruption. Physical examination was remarkable for numerous 2-3mm reddish-brown papules and papulovesicles on the trunk, the face, and the extremities (**Figure 1**), sparing the palms and soles. Additionally, there were large numbers of acquired and preexisting lentigines particularly on the upper part of the trunk and the extremities, most probably associated with the chronic and excessive sunlight exposure of the patient. There was no evidence of lymphadenopathy or hepatosplenomegaly. The patient had previously been treated with oral

tetracyclines, topical fusidic acid, and corticosteroids (oral and topical) with no improvement.

Histological examination of formalin-fixed and paraffin-embedded biopsy specimens obtained from the lesional skin of the patient was diagnostic of Grover disease (**Figure 2**). Routine hematological, biochemical, and serological tests revealed normal or negative results.

Mutation analysis of *ATP2A2*, that encodes the enzyme sarco/endoplasmic reticulum Ca^{2+} ATPase type 2, was performed at the Cyprus Institute of Neurology and Genetics on genomic DNA extracted from the peripheral leukocytes of the patient and revealed negative results.

All known treatment options (**Box 1**) of GD were discussed with the patient and oral treatment with acitretin was suggested. She was provided with detailed information about the possible side effects of this retinoid and gave a written consent. Oral treatment with 0.8 mg/kg/day acitretin was initiated. By one week after onset of treatment there was a dramatic resolution of pruritus and a significant improvement of the eruption; complete remission was observed after six weeks of continuous

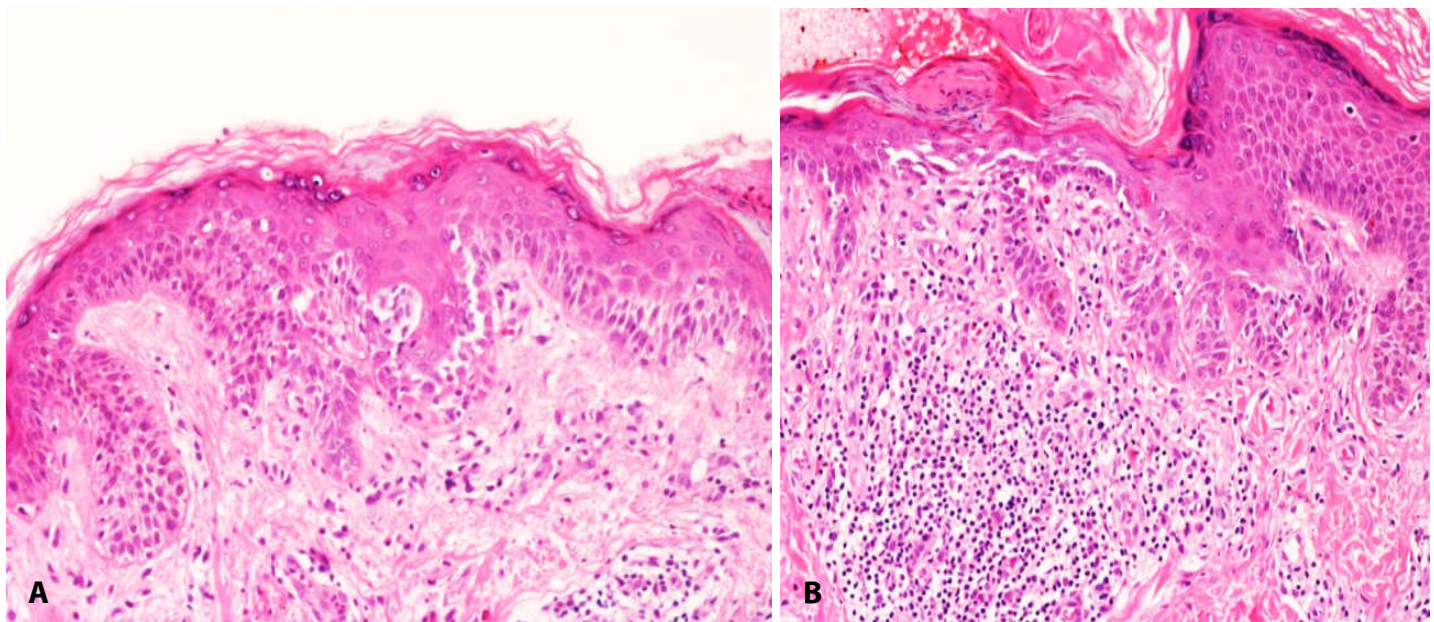


Figure 2. A) The epidermis shows small foci of subtle suprabasal acantholysis and clefting. Mild spongiosis is seen within the adjacent epidermis. Mild hyperparakeratosis is seen overlying the acantholytic focus. Mild chronic perivascular inflammation is noted within the underlying dermis. H&E, 20 \times . **B)** Another focus of acantholysis with occasional dyskeratotic cell and overlying fibrin secondary to excoriation. Associated hyper- and parakeratosis is seen in the adjacent epidermis. The dermal mixed inflammatory cell infiltrate is formed of lymphocytes, histiocytes and occasional eosinophils. There is no evidence of epidermotropism or atypia of the lymphocytes. H&E, 20 \times .

Topical

Zinc oxide
Urea
Lactic acid
Emollient bath oils
Colloidal oatmeal
Corticosteroids
All-*trans* retinoic acid
Vitamin D analogues (tacalcitol, calcipotriol)

Systemic

Antibiotics
Retinoids (isotretinoin, tretinate and acitretin)
Vitamin A
Corticosteroids
Methotrexate
Etanercept

Light-based treatments

Photochemotherapy
Phototherapy,
Photodynamic therapy
Laser

Surgical

Dermabrasion
Chemical peeling

Box 1. *Therapeutic options in Grover disease.*

treatment (**Figure 3**). Acitretin was well tolerated by the patient who experienced a moderate but reversible hair loss and discrete paronychia. All laboratory variables remained unaltered during treatment. The patient is presently completing a 26-month follow-up, remains well, and shows no evidence of relapse.

Case Discussion

GD is an acquired dermatosis that is characterized by highly pruritic papulovesicular lesions resembling those of Darier disease (DD), an autosomal dominant dermatosis with epidermal acantholysis and dyskeratosis, which is caused by mutations in the *ATP2A2* gene [7, 8]. The etiopathogenesis of GD is still poorly understood. It has been observed, however, that this cutaneous disorder may be triggered or exacerbated by heat, exercise, sweating, ionizing radiation, and sunlight exposure. The large number of acquired and preexisting lentigines observed in our patient points toward excessive solar damage. Nevertheless, the question as to whether chronic sunbathing practiced by our patient contributed to

the occurrence of GD remains to be elucidated. Some cases of GD have reportedly been associated with diverse benign and malignant cutaneous or systemic disorders and drugs and these are summarized in **Box 2** [9-14].

Acantholysis, the histologic hallmark of Grover disease, may be associated with spongiosis or reveal a pattern similar to that found in Hailey-Hailey disease, pemphigus vulgaris/foliaceus, and DD [15]. Apart from the combination of spongiosis and focal acantholytic dyskeratosis, which is unique in GD and has also been found in the case presented here, the overall histological findings in skin biopsy specimens derived from patients with the DD pattern of GD may be almost identical to those found in genuine DD.

The striking resemblance of these diseases in clinical, histological, and ultrastructural terms [16] has led some authors to hypothesize that either GD represents a “forme fruste” of DD or that both diseases share a common genetic defect [17]. However, in previous molecular genetic studies in patients with GD no mutations in *ATP2A2* gene could be detected [18-21].

In our attempt to exclude the possibility that the eruption of our patient might represent an abortive

Dermatoses

Asteatotic eczema, atopic, allergic and irritant contact dermatitis, pemphigus foliaceus, pemphigus vulgaris, psoriasis, pyoderma gangrenosum

Infections

Human immunodeficiency virus, scabies

Malignant disorders

Acute myeloid leukemia, gastric and larynx carcinoma, leukemia cutis, myelodysplastic syndrome

Transplantation

Bone marrow, heart, kidney, liver

Kidney disorders

Membranous glomerulonephritis, chronic kidney failure, peritoneal dialysis

Drugs

Anastrozole, cetuximab, interleukin 4, ipilimumab, rivabirin, sulfadoxine-pyrimethamine, penicillamine, 2-chlorodeoxyadenosine, cyclophosphamide, cytarabin, daunorubicin.

Box 2. *Disorders and drugs associated with Grover disease.*

form of Darier disease (DD), we carried out a molecular analysis of *ATP2A2* (defective gene in DD) on DNA extracted from the peripheral leukocytes of the patient, but were unable to find any mutations. Our findings taken together with those of other groups suggest that the etiopathogenetic mechanisms underlying GD and DD are different. We should bear in mind, however, that in several patients with DD no genetic defect can be detected.

A wide variety of therapeutic modalities have been employed in the management of GD with variable success and recurrence rates [22]. Obviously, owing to the transient nature of GD, a reliable evaluation of the therapeutic efficacy of these modalities is possible only in the persistent form of the disease.

In contrast to the disappointing results of oral vitamin A in the treatment of GD [23], the response of this dermatosis to oral synthetic retinoids seems to be promising. Helfman (1985), [24] reported four patients with persistent GD who were treated with oral 13-cis retinoic acid (isotretinoin), a representative of the first retinoid generation, at a dose of 40mg/day. Three-to-eight weeks after onset of treatment, three patients responded with remissions of up to 10 months, whereas one patient who obtained partial remission, relapsed when the retinoid administration was discontinued because of an elevation in triglycerides.

Oral administration of etretinate (0.25-0.50mg/kg/day), representative of the second retinoid generation and parent compound of acitretin, to two patients with persistent GD resulted in a distinct improvement of the skin lesions within 6

weeks of treatment [25]. Also, Dodd and Sarkany (1984), [26] reported a clinical improvement of a patient with persistent GD after treatment with oral etretinate (50mg/day) over an unknown period of time. Mokni et al. (1993), [27] reported a patient with persistent acantholytic dermatosis (possibly GD) who revealed an 80% remission of his lesions after 6 months of therapy with oral acitretin (0.50mg/kg/day). On the other hand, Miljkovic and Marko (2004), [28] reported that combined topical calcipotriol and oral acitretin treatment of a patient with persistent GD brought about a complete remission within three weeks.

To the best of our knowledge, this is the first report of a complete remission of the persistent form of GD subsequent to oral acitretin monotherapy. The drug was well tolerated by our patient, who has completed a 26-month follow-up with no evidence of relapse. In view of the impressive therapeutic results of this retinoid reported herein, further studies are now warranted to define the mechanisms underlying the therapeutic action of oral acitretin and to definitely answer the question as to whether this compound may be regarded as an effective therapeutic modality for the management of persistent GD.

Conclusion

We report herein the first patient case, to our knowledge, of a 26-month complete remission of the persistent form of GD with oral acitretin monotherapy. The drug was well-tolerated and may prove to be a useful treatment for other patients with this condition.

Potential conflicts of interest

The authors declare no conflicts of interests.

References

1. Grover RW. Transient acantholytic dermatosis. *Arch Derm* 1970; 101:426-34. [PMID: 5440816].
2. Heenan PJ, Quirk CJ. Transient acantholytic dermatosis. *Br J Dermatol* 1980;102:515-20. [PMID: 7387898].
3. Simon RS, Bloom D, Ackerman AB. Persistent acantholytic dermatosis. A variant of transient acantholytic dermatosis (Grover

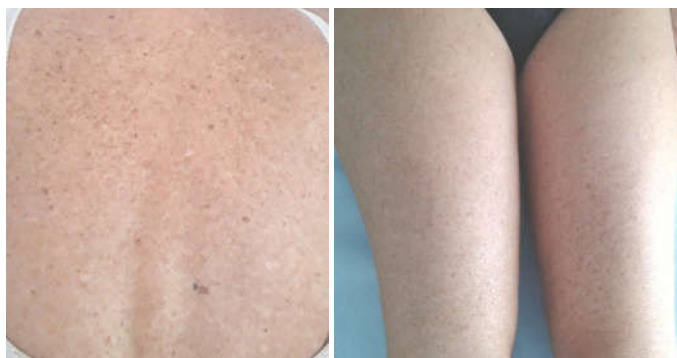

Figure 3. Clinical aspect of the back and the lower extremities of the patient subsequent to six weeks of acitretin monotherapy.

- disease). *Arch Dermatol* 1976;112:1429-31. [PMID: 786177].
4. Tsambaos D, Goerz G. Persistent acantholytic dermatosis Grover. *Akt Dermatol* 1978;4:151-55.
 5. Tsambaos D. Retinoids: a new chapter of systemic dermatotherapy. *Dermatosen in Beruf und Umwelt* 1996;44:182-83.
 6. Chroni E, Monastirli A, Tsambaos D. Neuromuscular adverse effects associated with systemic retinoid dermatotherapy: monitoring and treatment algorithm for clinicians. *Drug Saf* 2010;33:25-34. [PMID: 20000864].
 7. Burge S, Wilkinson J. Darier-White disease: a review of the clinical features in 163 patients. *J Am Acad Dermatol* 1992;27:40-50. [PMID: 1619075].
 8. Sakuntabhai A, Burge S, Monk S, Hovnanian A. Spectrum of novel ATP2A2 mutations in patients with Darier's disease. *Hum Mol Genet* 1999;8:1611-19. [PMID: 10441323].
 9. Ippoliti G, Paulli M, Lucioni M, D'Armini AM, Lauriola M, Saleb RMH. Grover's disease after heart transplantation: A case report. *Case Rep Transplant* 2012;126592. [PMID: 23320241].
 10. Moon H-R, Lee J-H, Rhee D-Y, Won CH, Chang SE, Lee MW, Choi JH, Moon KC. Grover's disease in a liver transplant patient. *Ann Dermatol* 2014;26:117-18. [PMID: 24648700].
 11. Munoz J, Guillot B, Dereure O, Du-Thanh A. First report of ipilimumab-induced Grover disease. *Br J Dermatol* 2014;171:1236-37. [PMID: 24749658].
 12. Rodríguez-Pazos L, Vilas-Sueiro A, González-Vilas D, Durana C. Grover's disease in chronic kidney failure. *Nefrologia* 2015;35:331-34. [PMID: 26299177].
 13. Lim PPL, Penas PF, Gottlieb D. Transient acantholytic dermatosis (Grover's disease) after bone marrow transplantation. *Australasian J Dermatol* 2016; 57:120-22. [PMID: 27358215].
 14. Matsudate Y, Urano Y, Hashimoto T. Grover's disease in a patient with pemphigus vulgaris. *Int J Dermatol* 2017;56:1052-54. [PMID: 28766705].
 15. Weaver J, Bergfeld WF. Grover disease: (Transient acantholytic dermatosis). *Arch Pathol Lab Med* 2009;133:1490-94. [PMID: 19722762].
 16. Biagini G, Costa AM, Laschi R. An electron microscope study of Darier's disease. *J Cutan Pathol* 1975;2(1):47-9. [PMID: 1225937].
 17. Carapeto FJ, Armijo M. Darier's disease with minimal lesions or Darier-like variant of Grover's disease. *Ann Dermatol Venereol* 1979;106:279282. [PMID: 485025].
 18. Powell J, Sakuntabhai A, James M, Burge S, Hovnanian A. Grover's disease, despite despite histological similarity to Darier's disease, does not share an abnormality in the ATP2A2 gene. *Br J Dermatol* 2000;143:658. [PMID: 10971355].
 19. Asahina A, Ishiko A, Hasegawa K, Sawamura D, Nakano H. Grover's disease following bilateral Blaschko lines: A rare clinical presentation with genetic and microscopic analyses. *Dermatology* 2012;225:183-87. [PMID: 23075809].
 20. Miyauchi T, Fujita Y, Morita Y, Suzuki S, Mizuno O, Saito N, Nomura T, Shimizu H. Pruritic papules following lumbar corset use: A quiz. *Acta Derm Venereol* 2015;95:762-65. [PMID: 25708298].
 21. di Meo N, Ulessi B, Trevisini S, Noal C, Nan K, Vichi S, Trevisan G. Monolateral Grover's disease with Blaschkoid distribution. *Acta Dermatovenerol Croat* 2017;25:310-11. [PMID: 30064609].
 22. Norman R, Chan V. Use of etanercept in treating pruritus and preventing new lesions in Grover disease. *J Am Acad Dermatol* 2011;64:796-97. [PMID: 21414507].
 23. Rohr JB, Quirk CJ. Treatment for transient acantholytic dermatosis. *Arch Dermatol Res* 1979; 115(9):1033-4. [PMID: 485173].
 24. Helfman RJ. Grover's disease treated with isotretinoin. Report of four cases. *J Am Acad Dermatol* 1985;12:981-84. [PMID: 3859501].
 25. Fawcett HA, Miller JA. Persistent acantholytic dermatosis related to actinic damage. *Br J Dermatol* 1983;109:349-54. [PMID: 6615722].
 26. Dodd HJ, Sarkany I. Persistent acantholytic dermatosis. *Clin Exp Dermatol* 1984;9(4):431-4. [PMID: 6744656].
 27. Mokni M, Aractingi S, Grossman R, Verola O, Letessier S, Civatte J, Dubertret L. Persistent acantholytic dermatosis: Sex-related differences in clinical presentation? *Acta Derm Venereol* 1993;73:69-71. [PMID: 8095759].
 28. Miljkovic J, Marko PB. Grover's disease: successful treatment with acitretin and calcipotriol. *Wien Klin Wochenschr* 2004 116 (S2):81-83. [PMID: 15506319].