

UC Davis

Dermatology Online Journal

Title

Photo recall reaction following the use of vancomycin

Permalink

<https://escholarship.org/uc/item/2t95p3m2>

Journal

Dermatology Online Journal, 19(11)

Authors

Jibbe, A
Tefft, K
Weir, G
et al.

Publication Date

2013

DOI

10.5070/D31911020396

Copyright Information

Copyright 2013 by the author(s). This work is made available under the terms of a Creative Commons Attribution-NonCommercial-NoDerivatives License, available at <https://creativecommons.org/licenses/by-nc-nd/4.0/>

Letter

Photo recall reaction following the use of vancomycin

Jibbe A, Tefft K, Weir G, Aires D, Liu D

Dermatology Online Journal 19 (11): 15

Affiliation: Division of Dermatology; University of Kansas School of Medicine, Dermatology

Correspondence:

Liu, Deede Y MD;
The University of Kansas Physicians Medical Office Building
3901 Rainbow Blvd MS 2025 Kansas City, KS 66160
913-588-3840; dliu@kumc.edu

Abstract

Drug-induced erythema in the distribution of prior sunburn is called photo recall. Although more commonly induced by chemotherapeutics, it has also been associated with antibiotics such as ampicillin, cephalosporin, and gentamicin. Vancomycin has not been previously reported as a causal agent. This case report describes photo recall in a fifty-three year old woman undergoing treatment with vancomycin for a MRSA infection of the spine. Her eruption followed a photo-distributed pattern on the chest, shoulders, neck and face sparing areas previously protected by her bathing suit. Of note, she reported a similar eruption following vancomycin two years prior.

Keywords: Photo recall, Photo-recall, Sunburn, Vancomycin, Ultraviolet radiation

II. Introduction

When drugs or other agents induce erythema that is limited to areas of prior radiotherapy or sunburn, the resulting eruption is termed a “photo recall reaction”. The sun or radiotherapy exposure may have been weeks to months prior to the reaction, and the skin would have fully recovered prior to the offending chemotherapeutic or, in this case, antibiotic [1]. Chemotherapy-induced erythema in the distribution of a previous sunburn is widely known, but antibiotic-induced recall reactions have also been reported. We now present a patient who experienced a photo recall reaction following the use of vancomycin to treat a Methicillin-resistant Staphylococcus aureus (MRSA) infection of the spine.

III. Case Report

A fifty-three year old woman presented with an erythematous eruption limited to previously sun exposed areas following the use of vancomycin to treat a MRSA infection of the spine. The patient developed progressive, confluent, flat, mildly pruritic, burning erythema with superficial desquamation on previously sun exposed areas including the arms, upper chest, neck, and face. Symptoms started one week after initiation of vancomycin treatment. Well demarcated sparing of the “shoulder strap” region was present. The patient’s lower lip was mildly swollen with some superficial scale. No blisters were observed. Of note the patient experienced sunburn two weeks prior to starting vancomycin therapy, but was hospitalized and received no sun exposure during vancomycin treatment. The skin changes and scaling associated with her previous sunburn had completely resolved by the time vancomycin was started.

Upon further questioning, the patient recalled a similar reaction to vancomycin two years ago. We suspect this previous reaction also represented a photo recall eruption secondary to vancomycin. The primary team was concerned about an IgE mediated response to vancomycin. The prior history of photo distributed lesions following vancomycin and the recurrence after this

vancomycin rechallenge lead us to conclude that her response was not an IgE mediated allergy. In contrast, an IgE mediated response would have been diffuse rather than photo distributed and would likely be associated with other symptoms such as urticaria, angioedema, generalized pruritus, tachycardia, hypotension, nausea, vomiting, lightheadedness, or hypotension [2]. Other dermatoses which can be caused by vancomycin include “red man syndrome,” which is related to non-immunologic mast degranulation, and linear IgA bullous dermatosis. “Red man syndrome” is unlikely since it is not generally restricted to areas of prior photo-damage, and it is generally associated with hypotension, which our patient did not experience. Linear IgA bullous dermatosis can be excluded because it is characterized by vesicles and bullae, neither of which were present in our patient.

Vancomycin was discontinued and treatment with daptomycin was initiated. The patient applied hydrocortisone 2.5% ointment twice daily to the face and neck and triamcinolone 0.1% ointment twice daily to the affected areas of the trunk. Her eruption subsided and daptomycin treatment was continued with no noteworthy dermatologic side effects.

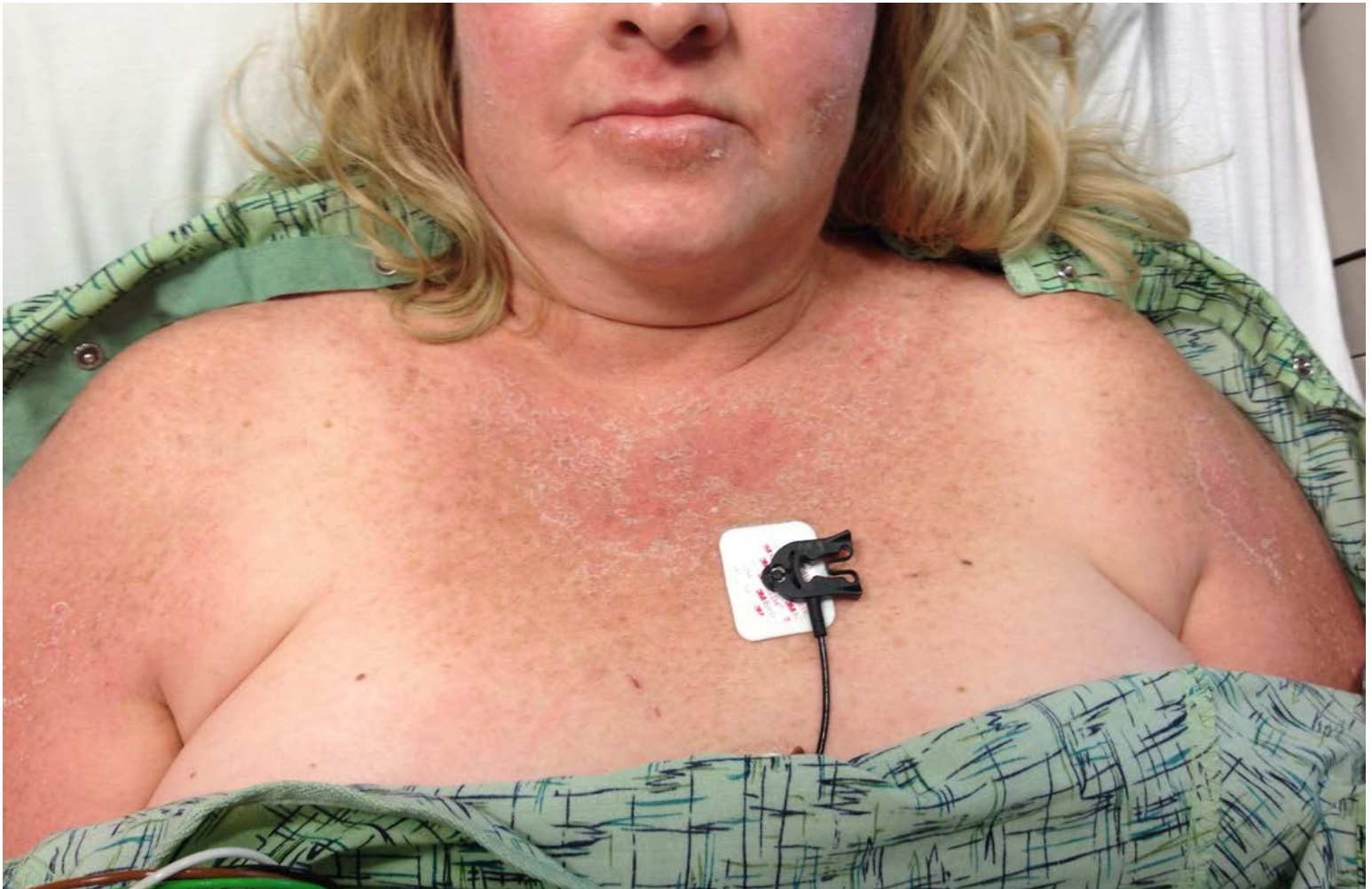


Figure 1. Erythematous eruption with sparing of the “shoulder strap” region

IV. Discussion

A few cases of antibiotic-induced photo recall have been reported. Associated antibiotics include ampicillin, cephalosporins, gentamicin, piperacillin, tobramycin, ciprofloxacin, and trimethoprim-sulfamethoxazole. Vancomycin had not been reported until now [3-6]. In 1990, Flax and Leujeune reported a case of a photo recall-like phenomenon in a woman being treated with cefazolin and gentamicin sulfate for a urinary tract infection. They described an erythematous, maculopapular eruption localized to areas previously damaged by sun exposure and strictly excluding areas covered by the patient’s bathing suit [3]. In 2001, Krishnan et al reported a morbilliform eruption on the sun-exposed areas in a woman receiving piperacillin, tobramycin, and ciprofloxacin. The lesions corresponded to sites of an intense sunburn that occurred a month before antibiotic administration [4]. Most recently, Blanco et al described a case in which a woman suffered from an itchy, erythematous skin eruption after taking ampicillin for tonsillitis. The lesions were restricted to areas that were mildly sunburned two months prior to treatment [5].

In this case, our patient exhibited erythema with very mild scale in a photo distributed pattern on the chest and shoulders with well demarcated sparing of the “shoulder strap” region. This distribution coupled with her previous sunburn and a lack of sun exposure during hospitalization points toward a photo recall reaction. The patient received vancomycin prior to the eruption and the eruption cleared upon termination, suggesting a causative role.

While the mechanism of photo recall induced by chemotherapeutic agents is not fully understood, current thinking holds that genetic traits render some individuals more susceptible to ultraviolet toxic insult. Ultraviolet radiation results in cumulative direct DNA damage and oxidative stress [7, 8, 9]. This interferes with DNA replication, transcription, and translation. A photo recall reaction then occurs when this previously damaged tissue cannot repair itself following a second insult (such as a chemotherapeutic or antibiotic) [7, 8, 9]. Another theory holds that chemotherapeutic-induced photo recall involves UV -induced damage to cutaneous vasculature. These vascular changes can be long lasting, explaining why recall reactions can occur months after the initial sun exposure [10]. Some speculate that similar mechanisms may underlie antibiotic-induced recall. Because these mechanisms are not well established, further investigation is needed.

V. Conclusion

Our patient experienced photo recall following the use of vancomycin to treat a MRSA infection of the spine. Two episodes of vancomycin-induced photo recall were observed: one episode two years prior and another episode following a vancomycin rechallenge. This represents the first report of photo recall following the use of vancomycin.

References

1. Tan E. Skin Toxicity of Chemotherapy Drugs [Internet]. New Zealand: New Zealand Dermatological Society Incorporated; 2007. Available from: www.dermnetz.org.
2. Weller PF, Adkinson FN, Feldwig AM. Vancomycin Hypersensitivity [Internet]. 2012 Sept 11. Available from: www.uptodate.com.
3. Flax SH, Uhle P: Photo recall-like phenomenon following the use of cefazolin and gentamicin sulfate. *Cutis*. 1990; 46: 59–61. [PMID:2384020]
4. Krishnan RS, Lewis AT, Kass JS, and Hsu S. Ultraviolet Recall-like Phenomenon Occurring after Piperacillin, Tobramycin, and Ciprofloxacin Therapy. *J Am Acad Dermatol*. 2001; 44: 1045-1048. [PMID:11369921]
5. Blanco J, Manzanedo L, Gutierrez MC, Fuentes M. Ultraviolet Recall Phenomenon Following the Use of Ampicillin. *Journal of Investigational Allergology*. 2002; 12 (3): 215-216. [PMID:12530122]
6. Shelley WB, Shelley ED, Campbell AC, Weigensberg IJ. Drug Eruptions Presenting at Sites of Prior Radiation Damage (Sunlight and Electron Beam). *Journal of the American Academy of Dermatology*. 1984; 11(1): 53-57. [PMID:6234333]
7. Sanborn RE, Sauer DA. Cutaneous Reactions to Chemotherapy: Commonly Seen, Less Described, Little Understood. *Dermatology Clinics*. 2008; 26(1): 103-119. [PMID:18023774]
8. Solberg LA Jr, Wick MR, Bruckman JE. Doxorubicin-enhanced Skin Reaction after Whole-body Electron-beam Irradiation for Leukemia Cutis. *Mayo Clinic Proceedings*. 1980; 55(11): 711-715. [PMID:6777613]
9. Smith KJ, Germain M, Skelton H. Histopathologic features seen with radiation recall or enhancement eruptions. *J Cutan Med Surg* 2002;6:535–40. [PMID:12362258]
10. Lowitt MH, Eisenberg M, Sina B, sKao GF. Cutaneous eruptions from suramin: a clinical and histopathologic study of 60 patients. *Arch Dermatol* 1995; 131:1147-1153. [PMID:7574831]