

UC Davis

Dermatology Online Journal

Title

Hyperkeratotic variant of porokeratosis in a patient with Hepatitis C virus infection and a concomitant immunosuppressed state

Permalink

<https://escholarship.org/uc/item/2sc54934>

Journal

Dermatology Online Journal, 21(11)

Authors

Parekh, Vishwas
Kabihting, Filamer D
Junkins-Hopkins, Jacqueline M

Publication Date

2015

DOI

10.5070/D32111029288

Copyright Information

Copyright 2015 by the author(s). This work is made available under the terms of a Creative Commons Attribution-NonCommercial-NoDerivatives License, available at <https://creativecommons.org/licenses/by-nc-nd/4.0/>

Peer reviewed

Case presentation

Hyperkeratotic variant of porokeratosis in a patient with Hepatitis C virus infection and a concomitant immunosuppressed state.

Vishwas Parekh MD¹, Filamer D Kabigting MD², Jacqueline M Junkins-Hopkins²

Dermatology Online Journal 21 (11): 8

¹Department of Pathology, University of Alabama at Birmingham, Birmingham, AL, and ²Ackerman Academy of Dermatopathology, New York, NY.

Correspondence:

Jacqueline M. Junkins-Hopkins, MD
Ackerman Academy of Dermatopathology
145 E 32nd St 10th floor,
New York, NY 10016
Phone: 212-889-6225; 800-553-6621
Fax: 212-889-8268
Email: jakki22@gmail.com

Abstract

Porokeratoses are acquired and hereditary disorders of keratinization that share a distinctive lesion characterized by raised keratotic borders corresponding histologically to an angled column of parakeratotic cells, called a cornoid lamella. Although a precise mechanistic explanation is lacking, ultraviolet radiation and immunosuppressed states are considered causally-associated with most cases of acquired porokeratosis. Hepatitis C virus (HCV) infection has been proposed as a link between the immunosuppressed states and development of acquired porokeratosis. Among the various recognized clinical entities that constitute this group, rare cases of hyperkeratotic variants have been described that may pose a diagnostic challenge. Herein we describe a remarkable case of the hyperkeratotic variant of porokeratosis that occurred in a patient with known HIV and HCV infections and a coexisting therapy-related immunosuppressed state. We also provide a review of the relevant literature.

Keywords: porokeratosis, Hepatitis C virus skin, immunosuppression skin

Introduction

Porokeratoses are disorders of keratinization with a very characteristic clinical and histopathologic appearance. Typical lesions present as well-circumscribed, slightly atrophic macules, patches, or plaques with a distinctive peripheral keratotic ridge, called the cornoid lamella. A histopathologic hallmark of porokeratosis, the cornoid lamella consists of a column of parakeratosis sitting in a shallow epidermal depression and projecting at an approximately 45° angle through the stratum corneum. The epidermis underneath the parakeratotic column shows dyskeratotic keratinocytes and an absence of a granular cell layer. This characteristic and generally pathognomonic appearance is believed to arise as the result of a clonal expansion of atypical keratinocytes, migrating away from their point origin [1].

Generally a relatively straightforward clinical diagnosis, rare cases of porokeratosis exhibit marked hyperkeratosis and may pose a diagnostic challenge owing to their unusual clinical appearance [2-6]. Additionally, there are some variants in which the pattern of cornoid lamella formation is less well circumscribed, or obscured by verruciform hyperplasia, requiring correlation with the clinical presentation to elicit the appropriate diagnosis. Herein, we describe such a case of the hyperkeratotic variant of

porokeratosis that occurred in a patient with known HIV and HCV infections and a therapy-related immunosuppressed state. Additionally, we provide a review of relevant literature and highlight the potential relationship between porokeratosis, HCV infection and immunosuppressed states.

Case synopsis

A 53-year-old man with a history of chronic intense sun exposure, intravenous drug abuse, severe psoriatic arthritis, and Hepatitis B, HCV, and HIV infections presented with a complaint of recent development of painful lesions on the palms of the hands and soles of the feet. His CD4 T-cell count was 1000 cells/mm³, and he had no history of HIV-associated AIDS. He was being treated with an immunosuppressive regimen for psoriatic arthritis. Family history was non-contributory.

On physical examination, the patient had severely deformed hands and feet related to the psoriatic arthritis, and several missing digits. Diffuse hyperkeratotic patches and plaques on the hands as well as ankles and plantar aspects of the feet were evident (Figure 1). The clinical differential diagnosis included psoriasis, widespread verruca vulgaris, and fungal infection. A representative hyperkeratotic lesion on the right foot was biopsied and sent for histopathologic examination.

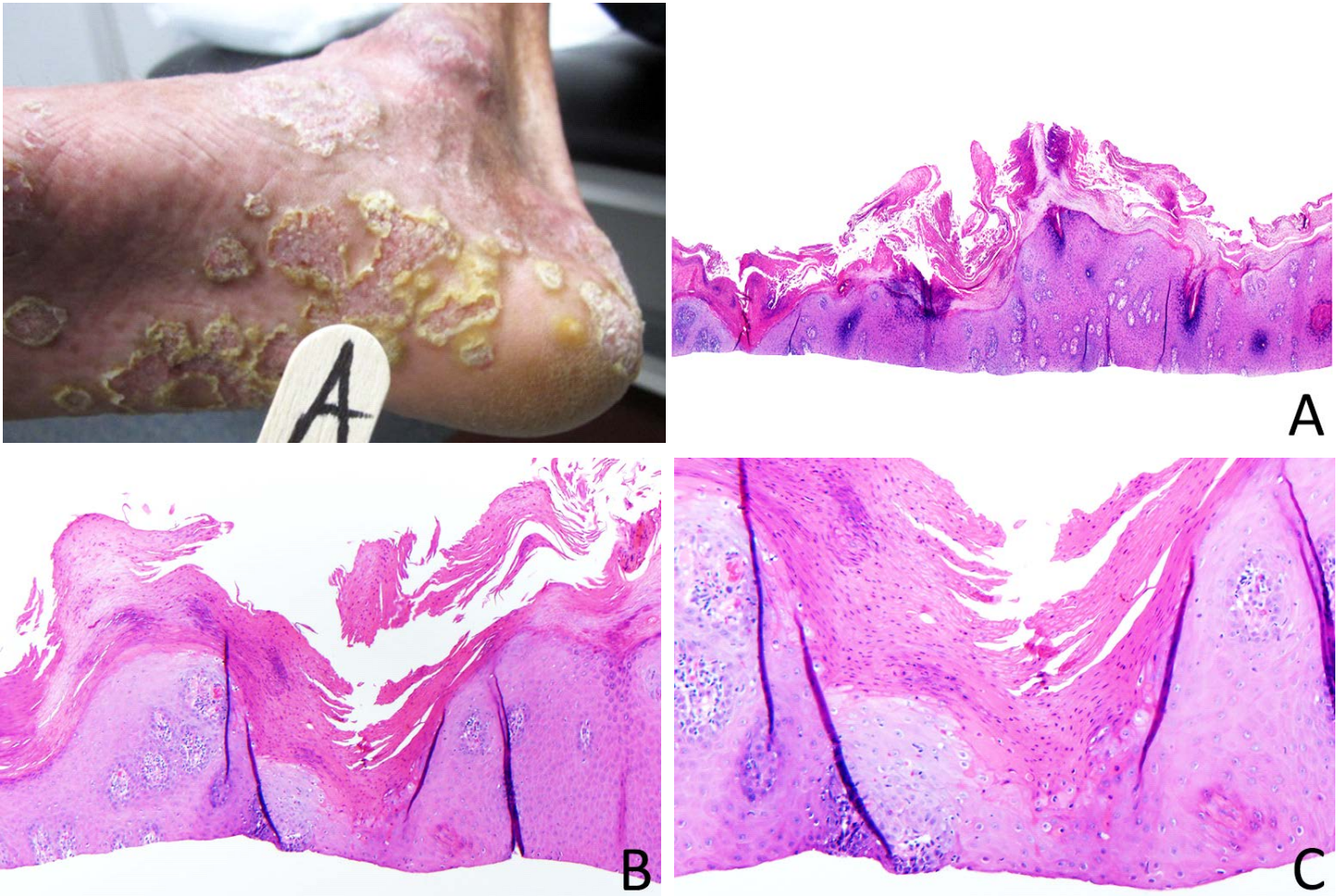


Figure 1. Diffuse hyperkeratotic patches and plaques on the ankle and plantar aspect of the right foot. **Figure 2.** H&E stained section of superficial shave biopsy from right foot demonstrates a marked psoriasiform and verrucous epidermal hyperplasia, original magnification 40x (A); A column of parakeratosis consistent with a cornoid lamella, original magnification 100x (B) and 200x (C).

The hematoxylin and eosin (H&E) stained sections of a superficial shave biopsy demonstrated marked psoriasiform and verrucous epidermal hyperplasia, surmounted by a thickened compact stratum corneum with ortho- and parakeratotic scale. Beneath columns of parakeratosis, the granular layer was absent, and dyskeratotic keratinocytes were identified, consistent with a cornoid lamella (Fig 2 A-C). Intraepithelial neutrophils to favor a diagnosis of psoriasis were not evident on H&E and myeloperoxidase staining. PAS and GMS stains for fungal microorganisms were negative. Immunohistochemical studies for HPV and HHV-8 were negative. A diagnosis of hyperkeratotic variant of porokeratosis was made.

Discussion

Originally described in 1893 by Vittorio Mibelli, porokeratosis was designated as such because Mibelli believed that the cornoid lamellae represented ostia (pores) of the sweat ducts [7, 8]. In the ensuing years, this misconception has been resolved, but the

erroneously coined term has endured. Several clinical variants have been described, which include disseminated superficial actinic porokeratosis (DSAP) - the most common form, classical porokeratosis of Mibelli, disseminated superficial porokeratosis (DSP), porokeratosis plantaris palmaris et disseminata (PPPD), linear porokeratosis, punctate porokeratosis, porokeratoma, eruptive porokeratosis, and ptychotropic porokeratosis (verrucous porokeratosis of the gluteal cleft) [9-12]. Familial cases of porokeratosis are inherited in an autosomal dominant fashion with variable penetrance such that members of a family may exhibit different variants [13]. Among the acquired forms of porokeratoses, sunlight and artificial ultraviolet (UV) rays are considered to be the prime triggers of an abnormal keratinocyte clone proliferation [14]. A significant proportion of cases are associated with immunosuppressed states [15-16], chiefly in the setting of immunosuppressive regimens for organ transplantation [17], autoimmune diseases [18], chronic liver diseases [19-20], and diabetes mellitus [21]. At least four cases have been described in a background of HIV-associated acquired immunodeficiency syndrome (AIDS) [22-23]. Of pertinent interest to this case report, HCV infection has been proposed as a link between the immunosuppressed states and development of porokeratosis [24-25]. Although porokeratosis is considered a benign disease process with a favorable prognosis, malignant transformation, usually in the form of squamous cell carcinoma, is not uncommon [26].

This case of hyperkeratotic variant of porokeratosis initially posed a diagnostic challenge, owing to the fact that a cornoid lamella was not present in the initial sections examined, and the clinical presentation of abrupt onset of lesions prompted a diagnosis of worsening psoriasis. Fortunately, the clinical image documenting the keratotic rim supported our histologic finding of a cornoid lamella, allowing the diagnosis to be made. In addition to highlighting the need for close inspection for cornoid lamellae, this case also offers additional insight into other diagnostic clues. A clinical picture such as in this case, of a sudden appearance of hyperkeratotic lesions in a patient with therapy-related immunosuppression, should alert one to a possibility of acquired porokeratosis. Moreover, this patient's history of concomitant HCV infection and immunosuppression is intriguing and further contributes to the overall diagnostic presentation. The potential causal relationship between porokeratosis, HCV infection, and immunosuppression was first proposed in 1999 by Misukawa and Shioharas. They presented three such cases of porokeratosis and performed an exhaustive review of the past case reports of porokeratosis in the setting of immunosuppression. They found that 69% of these cases (35 of 51) also harbored identifiable risk factors for HCV infection such as organ transplant, transfusion of blood products, intravenous drug use, or plasmapheresis, in an era when HCV screening was not routine (before 1991-92) [24]. In a subsequent paper, they describe how the HCV-induced immune dysregulation and genomic instability could potentially trigger the development of porokeratosis in immunosuppressed individuals [25]. Similarly, Kono T. et al. described synchronous development of DSP and HCV-related hepatocellular carcinoma in three cases in an acute manner reminiscent of the present case [27]. In these cases, liver cirrhosis contributed to the immunosuppressed state. From a mechanistic point of view, HCV has been shown to repress p21 (waf1) in a p53-dependent manner [28-30], whereas overexpression of p53 and diminished expression of mdm2 and p21 (waf1) have been demonstrated within keratinocytes underlying the cornoid lamella [31].

Table 1. Case reports for porokeratosis in the background of concomitant HCV infection and immunosuppressed state.

Reference	Year	Sex	Age (yrs)	HCV infection	HCV risk factor	Immunosuppressed state	HIV infection	Clinical variant	Location	Family history
Mizukawa et al. ¹⁶	1999	M	80	Yes	None	Liver dysfunction	ND	DSP	Extremities and trunk	Negative
		M	64	Yes	Acupuncture	Psoriasis Rx	ND	PM	Buttock and genitalia	Negative
		F	41	Yes	Blood transfusion	SLE Rx	ND	PM	Left lower leg	Negative
Kono et al. ²⁴	2000	M	67	Yes	ND	Liver cirrhosis	ND	DSP	Extremities and trunk	Negative
		M	62	Yes	ND	Liver cirrhosis	ND	DSP	Entire body	Negative
		F	58	Yes	ND	Liver cirrhosis	ND	DSP	Extremities and trunk	Negative
Present case	2014	M	53	Yes	IV drug use	Psoriatic arthritis Rx	Yes	Hyperkeratotic	Hands and Feet	Negative

Footnote: HCV: Hepatitis C virus, F: Female, M: Male, IV: intravenous, HIV: Human Immunodeficiency Virus, ND: Not documented, Rx: Treatment, SLE: Systemic Lupus Erythematosus, DSP: Disseminated Superficial Porokeratosis, PM: Porokeratosis of Mibelli.

Although the link between porokeratosis, HCV infection and immunosuppressed states remains clinically anecdotal (Table 1), by reporting this case, we aim to bring attention to this relationship to allow others to recognize the presence of HCV infection as a potential clue to the diagnosis of acquired porokeratosis. Pursuit of additional investigations by the dermatologic and scientific community will potentially allow a better understanding of the pathogenesis of this relationship.

Conclusion

We report a rare hyperkeratotic variant of porokeratosis in the setting of HCV and HIV infections and an immunosuppressed state associated with therapy for psoriatic arthritis. In the absence of a family history, we favor this to be an acquired form of porokeratosis, associated with immunosuppression and/or HCV infection. Furthermore, in the light of previous literature, we postulate that the HCV infection may be a link between immunosuppressed states and development of porokeratosis.

References

1. Reed RJ, Leone P. Porokeratosis--a mutant clonal keratosis of the epidermis. I. Histogenesis. *Arch Dermatol*. 1970 Mar;101(3):340-7. [PMID: 5414891]
2. Marghescu S, Anton-Lamprecht I, Melz-Rothfuss B. Disseminated bilateral hyperkeratotic variant of porokeratosis Mibelli. *Arch Dermatol Res*. 1987;279 Suppl:S38-47. [PMID: 3662603]
3. Jacyk WK, Esplin L. Hyperkeratotic form of porokeratosis of Mibelli. *Int J Dermatol*. 1993 Dec;32(12):902-3. [PMID: 8125699]
4. Schaller M, Korting HC, Kollmann M, Kind P. The hyperkeratotic variant of porokeratosis Mibelli is a distinct entity: clinical and ultrastructural evidence. *Dermatology*. 1996;192(3):255-8. [PMID: 8726642]
5. Jang KA, Choi JH, Sung KJ, Moon KC, Koh JK. The hyperkeratotic variant of disseminated superficial actinic porokeratosis (DSAP). *Int J Dermatol*. 1999 Mar;38(3):204-6. [PMID: 10208617]
6. Yu HJ, Park KT, Oh DH, Kim JS, Park YW. A case of the hyperkeratotic variant of porokeratosis Mibelli. *J Dermatol*. 2006 Apr;33(4):291-4. [PMID: 16674797]
7. Mibelli V. Contributo allo studio della ipercheratosi dei canali sudoriferi (porokeratosi). *G It Mal Vener Pelle* 1893; 28: 313-355. (Translation: Mibelli V. Contribution to the study of hyperkeratosis of the sweat canals (porokeratosis). *Ital J Vener Di*. 1893;28:313-55)
8. Allegra F. The man behind the eponym. Vittorio Mibelli and the tale of "porokeratosis". *Am J Dermatopathol*. 1986 Apr;8(2):169-72. [PMID: 3521366]
9. Johnson BL, Honig P. Congenital diseases (genodermatoses). In: Elder DE, Elenitsas R, Johnson BL, Murphy GF. *Lever's Histopathology of the Skin*. 9th ed. Philadelphia, PA. Lippincott Williams & Wilkins; 2005.
10. Kanitakis J, Rival-Tringali AL, Chouvet B, Vignot E, Claudy A, Faure M. Porokeratoma (porokeratotic acanthoma): immunohistological study of a new case. *J Cutan Pathol*. 2009 Jul;36(7):804-7. [PMID: 19519614]
11. Takiguchi RH, White KP, White CR Jr, Simpson EL. Verrucous porokeratosis of the gluteal cleft (porokeratosis ptychotropica): a rare disorder easily misdiagnosed. *J Cutan Pathol*. 2010 Jul;37(7):802-7. [PMID: 19638069]
12. Goulding JM, Teoh JK, Carr RA, Humphreys F, Gee BC. Eruptive disseminated superficial porokeratosis with rapid resolution: a drug-induced phenomenon? *Clin Exp Dermatol*. 2009 Dec;34(8):895-7. [PMID: 19508573]
13. Anderson DE, Chernosky ME. Disseminated superficial actinic porokeratosis. Genetic aspects. *Arch Dermatol*. 1969 Apr;99(4):408-12. [PMID: 5769326]
14. Chernosky ME. Porokeratosis. *Arch Dermatol*. 1986 Aug;122(8):869-70. [PMID: 3740870]
15. Bencini PL, Crosti C, Sala F. Porokeratosis: immunosuppression and exposure to sunlight. *Br J Dermatol*. 1987 [PMID: 3814507]
16. Lederman JS, Sober AJ, Lederman GS. Immunosuppression: a cause of porokeratosis? *J Am Acad Dermatol*. 1985 Jul;13(1):75-9. [PMID: 3861628]
17. Macmillan AL, Roberts SO. Porokeratosis of Mibelli after renal transplantation. *Br J Dermatol*. 1974 Jan;90(1):45-51. [PMID: 4590663]
18. Terranova M, Amato L, Massi D, Fabbri P. Disseminated superficial actinic porokeratosis in a patient with Sjögren syndrome. *Skinmed*. 2003 Nov-Dec;2(6):390-1. [PMID: 14673257]
19. Venencie PY, Verola O, Puissant A. Porokeratosis in primary biliary cirrhosis during plasmapheresis. *J Am Acad Dermatol*. 1986 Oct;15(4 Pt 1):709-10. [PMID: 3771845]
20. Dippel E, Haas N, Czarnetzki BM. Porokeratosis of Mibelli associated with active chronic hepatitis and vitiligo. *Acta Derm Venereol*. 1994 Nov;74(6):463-4. [PMID: 7701882]
21. Nakamura M, Fukamachi S, Tokura Y. Acute onset disseminated superficial porokeratosis associated with exacerbation of diabetes mellitus due to development of anti-insulin antibodies. *Dermatoendocrinol*. 2010 Jan;2(1):17-8. [PMID: 21547143]
22. Kanitakis J, Misery L, Nicolas JF, Lyonnet S, Chouvet B, Haftek M, Faure M, Claudy A, Thivolet J. Disseminated superficial porokeratosis in a patient with AIDS. *Br J Dermatol*. 1994 Aug;131(2):284-9. [PMID: 7917997]
23. Rodríguez EA, Jakubowicz S, Chinchilla DA, Carril A, Viglioglia PA. Porokeratosis of Mibelli and HIV-infection. *Int J Dermatol*. 1996 Jun;35(6):402-4. [PMID: 8737872]
24. Mizukawa Y, Shiohara T. Porokeratosis in patients with hepatitis C virus infection: does hepatitis C virus infection provide a link between porokeratosis and immunosuppression? *Br J Dermatol*. 1999 Jul;141(1):163-4. [PMID: 10417540]
25. Mizukawa Y, Shiohara T. Virus-induced immune dysregulation as a triggering factor for the development of drug rashes and autoimmune diseases: With emphasis on EB virus, human herpesvirus 6 and hepatitis C virus. *J Dermatol Sci*. 2000;22(3):169-180. [PMID: 10698154]
26. Sasson M, Krain AD. Porokeratosis and cutaneous malignancy. A review. *Dermatol Surg*. 1996 Apr;22(4):339-42. [PMID: 8624658]

27. Kono T, Kobayashi H, Ishii M, Nishiguchi S, Taniguchi S. Synchronous development of disseminated superficial porokeratosis and hepatitis C virus-related hepatocellular carcinoma. *J Am Acad Dermatol*. 2000 Nov;43(5 Pt 2):966-8. [PMID: 11044835]
28. Ray RB, Steele R, Meyer K, Ray R. Hepatitis C virus core protein represses p21WAF1/Cip1/Sid1 promoter activity. *Gene*. 1998 Feb 27;208(2):331-6. [PMID: 9524287]
29. Kwun HJ, Jung EY, Ahn JY, Lee MN, Jang KL. p53-dependent transcriptional repression of p21(waf1) by hepatitis C virus NS3. *J Gen Virol*. 2001 Sep;82(Pt 9):2235-41. [PMID: 11514734]
30. Majumder M, Ghosh AK, Steele R, Ray R, Ray RB. Hepatitis C virus NS5A physically associates with p53 and regulates p21/waf1 gene expression in a p53-dependent manner. *J Virol*. 2001 Feb;75(3):1401-7. [PMID: 11152513]
31. Nelson C, Cowper S, Morgan M. p53, mdm-2, and p21 waf-1 in the porokeratoses. *Am J Dermatopathol*. 1999 Oct;21(5):420-5. [PMID: 10535569]