

UC Davis

Dermatology Online Journal

Title

Toxic epidermal necrolysis due to voriconazole: case report and review

Permalink

<https://escholarship.org/uc/item/2pt32578>

Journal

Dermatology Online Journal, 20(9)

Authors

Gomulka, Jennifer
Wilson, Barbara D
Joyce, Joel C

Publication Date

2014

DOI

10.5070/D3209023901

Copyright Information

Copyright 2014 by the author(s). This work is made available under the terms of a Creative Commons Attribution-NonCommercial-NoDerivatives License, available at <https://creativecommons.org/licenses/by-nc-nd/4.0/>

Peer reviewed

Case Report

Toxic epidermal necrolysis due to voriconazole: case report and review

Jennifer Gomulka BS¹, Barbara D. Wilson MD¹, Joel C. Joyce MD²

Dermatology Online Journal 20 (9): 1

¹Medical College of Wisconsin, Milwaukee, Wisconsin

²NorthShore University Health System, Skokie, Illinois

Correspondence:

Joel C. Joyce, M.D.
Division of Dermatology
9933 Woods Drive
Skokie, Illinois 60077
Email: joeljoyce@gmail.com
Phone: 847-663-8060

Abstract

Toxic epidermal necrolysis is an uncommon but potentially life-threatening adverse cutaneous drug reaction characterized by variable degrees of epidermal necrosis and detachment leading to morbidity and risk of mortality. We describe a 67-year-old woman who underwent allogeneic peripheral blood stem cell transplantation as treatment for chronic lymphocytic leukemia. She developed toxic epidermal necrolysis after she was transitioned to voriconazole, which was a component of her post-transplant regimen. The diagnosis of toxic epidermal necrolysis in our patient was made clinically and confirmed histologically. Based on the temporal initiation of voriconazole therapy and the development of her adverse cutaneous reaction, we concluded that voriconazole was the offending agent. There are limited reported cases of voriconazole-induced toxic epidermal necrolysis; we report this case to increase awareness of this potential life-threatening complication.

Keywords: toxic epidermal necrolysis, voriconazole, severe cutaneous adverse reaction, drug reaction, bullous disorder

Introduction

Toxic epidermal necrolysis is a severe cutaneous adverse reaction characterized by variable degrees of epidermal necrosis with subsequent blister formation and detachment as well as mucosal involvement. It is often a drug-induced reaction and has been associated with exposure to a variety of medications. It carries substantial risk of morbidity and mortality [1]. Herein we report a case of a 67-year-old woman who developed severe epidermal necrosis and detachment while on antifungal therapy with voriconazole.

Case synopsis

A 67-year-old woman with chronic lymphocytic leukemia underwent allogeneic peripheral blood stem cell transplant six months prior to readmission for a rapidly progressive painful blistering dermatitis. Her post-transplant course was complicated by systemic infections requiring antimicrobial therapy as well as Grade IV intestinal graft-versus-host disease treated with elevated doses of her post-transplant regimen of methylprednisolone, mycophenolate, tacrolimus, and tocilizumab. Several days prior to

discharge from her prolonged hospital stay, her antifungal regimen was transitioned to oral voriconazole. A week later, she was readmitted with a two day history of an expanding painful red eruption with blistering and desquamation. The dermatology service was consulted for urgent evaluation.

Physical examination revealed diffuse 2-10mm round to oval atypical targets with dusky red centers coalescing into red-brown dusky plaques on the torso and thighs. She also had tense blisters on the back, axillae, and thighs (Figure 1), some of which had ruptured resulting in painful denuded skin (Figure 2). There was no mucosal involvement, but the patient was febrile. The body surface area involved at presentation was ~35%. Clinical suspicion was high for toxic epidermal necrolysis.

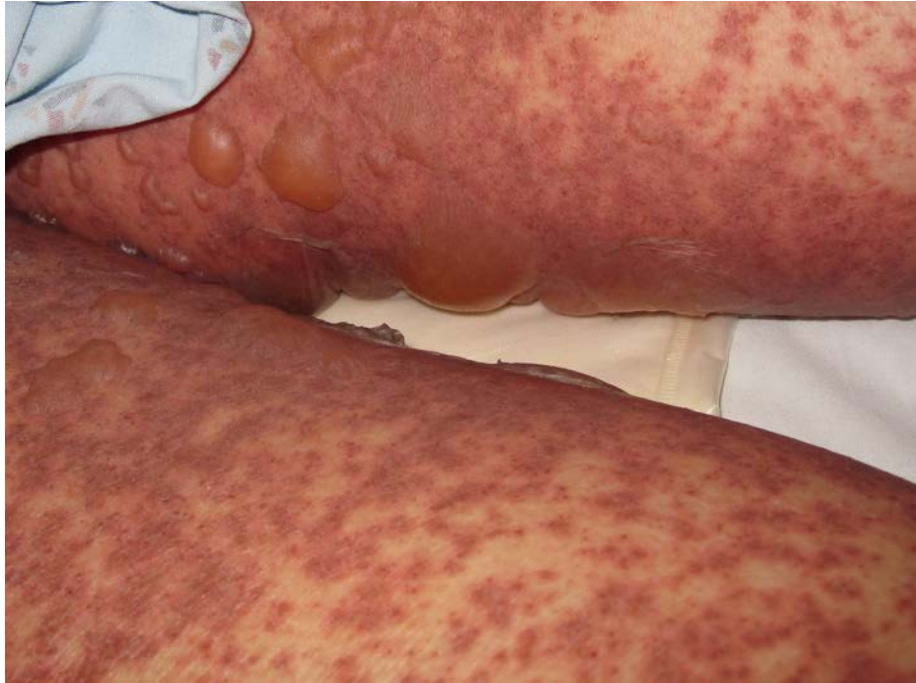

Figure 1. Tense blisters on a background of dusky red macules and plaques located on the thighs of a 67-year-old woman on the day of hospital consultation

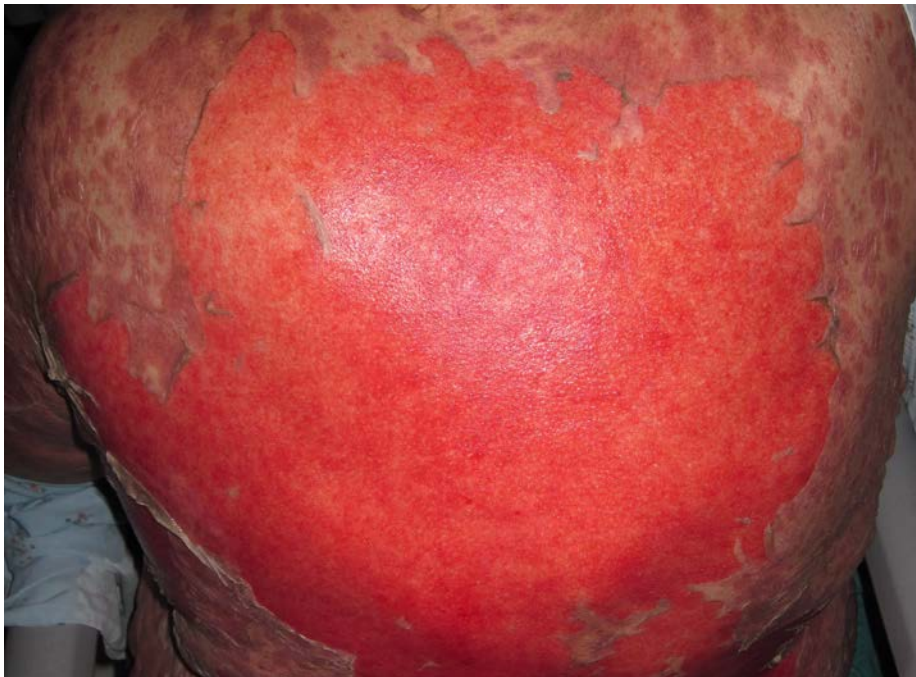


Figure 2. Substantial area of denuded skin located on the back of our patient one day after presentation

A punch biopsy was obtained from the back (Figure 3). Findings from a lesional biopsy revealed a subepidermal blister with overlying confluent epidermal necrosis. In addition, a mild perivascular and interstitial lymphocytic infiltrate was present. The histologic findings combined with her clinical appearance confirmed the diagnosis of toxic epidermal necrolysis.

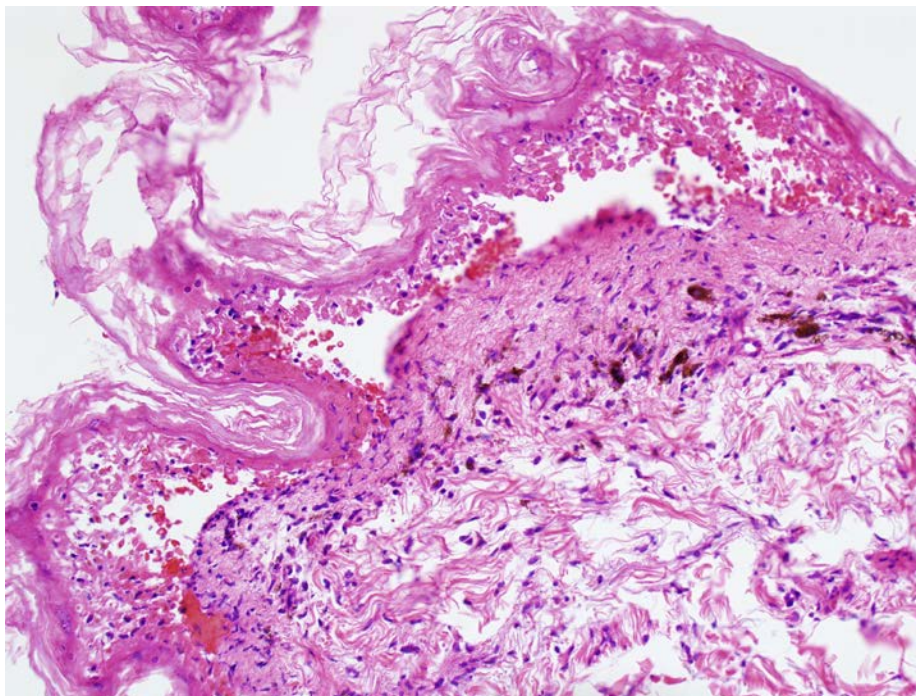
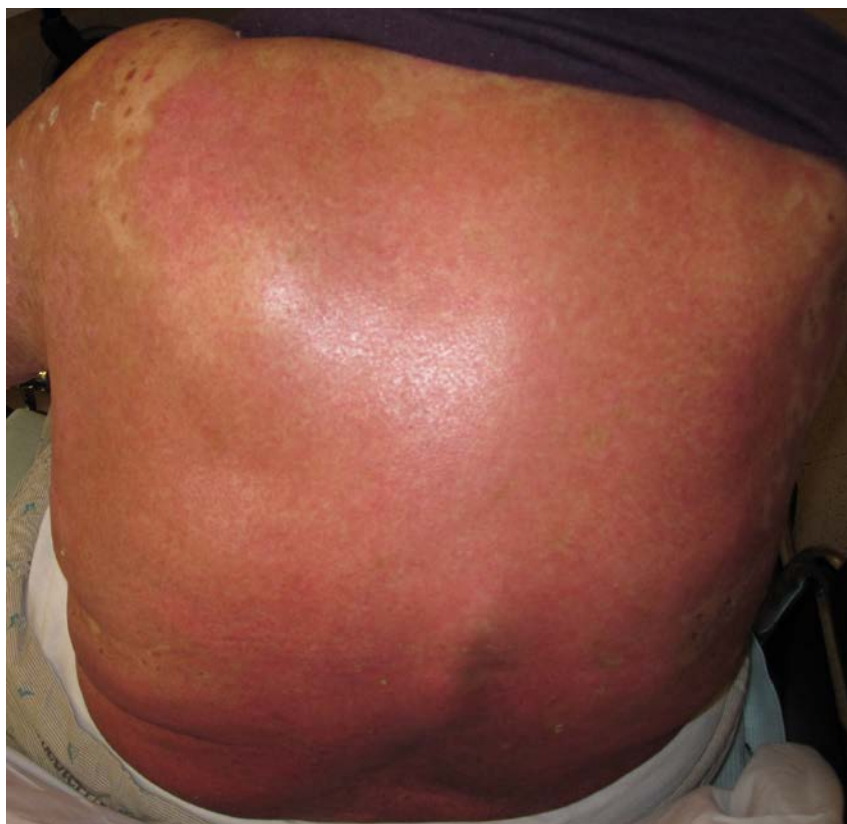

Figure 3. Low magnification H&E stain of punch biopsy specimen from back: Shown is a subepidermal blister with overlying confluent epidermal necrosis as well as a mild perivascular and interstitial lymphocytic infiltrate.

Extensive review of her medications including time of initiation and duration of exposure was undertaken. Voriconazole was identified as the most likely offending agent because it was the only new medication introduced one week prior to the development of her extensive blistering. Given her diagnosis of toxic epidermal necrolysis, her SCORTEN value was calculated at 4 (of 7) with estimated mortality of 58.3%. Voriconazole was discontinued and the patient was given intravenous immunoglobulin 3g/kg total dose. Methylprednisolone, mycophenolate, and tacrolimus were continued. Meticulous wound care with silicone dressings and white petrolatum was undertaken. Pain and fluid management were optimized and empiric antimicrobial coverage was administered. Maximal body surface involvement was approximately 45%.

Despite her poor prognosis, re-epithelialization occurred after 3 weeks (Figure 4) and she was discharged to rehabilitation without major complications. At 3 months' follow-up, she noted hyperpigmentation but no other cutaneous sequelae such as scarring, pain, or other discomfort.



Discussion

Toxic epidermal necrolysis is a rare, subepidermal blistering disease that is often an adverse drug reaction. Dusky red and/or purpuric macules, papules, and plaques of irregular size and shape first appear on the trunk, neck, and face and are usually tender and painful. Atypical target lesions may be present. Area of involvement can progress rapidly and the erythema tends to coalesce. A gray hue and blister formation is indicative of epidermal necrosis and detachment. Extensive epidermal loss leads to intense pain, fluid imbalance, and infection risk. Classically fever, stinging eyes, and dysphagia accompany the skin findings. Mucous membrane involvement occurs in 90% of cases, but is not required for diagnosis [2].

Toxic epidermal necrolysis and Stevens-Johnson syndrome exist along a spectrum of body surface area involvement, with Stevens-Johnson syndrome involving <10% body surface area and toxic epidermal necrolysis involving >30% body surface area. A Stevens-Johnson syndrome / toxic epidermal necrolysis overlap exists for intermediate involvement between 10% and 30% body surface area [3]. Risk of death is correlated with degree of epidermal detachment [4]. A validated disease severity index, SCORTEN, was developed to estimate prognosis at presentation for individuals suspected to have toxic epidermal necrolysis [3]. Traditionally erythema multiforme was thought to occur on the same spectrum of Stevens-Johnson syndrome / toxic epidermal necrolysis. However, current understanding classifies erythema multiforme and its variants as conditions distinct from Stevens-Johnson syndrome / toxic epidermal necrolysis. Erythema multiforme is usually associated with infectious causes and carries a markedly lower risk of mortality than Stevens-Johnson syndrome / toxic epidermal necrolysis [5].

Characteristic histologic features of toxic epidermal necrolysis include confluent epidermal necrosis, often with basal vacuolar change and a subepidermal split leading to bulla formation and/or complete dermo-epidermal separation. A paucicellular lymphocytic infiltrate is usually present in the dermis with occasional epidermal exocystosis [6].

The majority of cases of toxic epidermal necrolysis are attributed to medications, yet only two other cases of toxic epidermal necrolysis secondary to voriconazole have been reported [7, 8] (see below). Commonly associated medications include anti-infectious sulfonamides, allopurinol, carbamazepine, phenytoin, phenobarbital, lamotrigine, and nevirapine. Less common associations include other antimicrobials (cephalosporins and fluoroquinolones) and non-steroidal anti-inflammatories [9]. Numerous other medications and infections have been implicated as well. The risk of developing toxic epidermal necrolysis is highest in the first two weeks of therapy [2]. The pathogenesis of keratinocyte death remains unclear but is thought to include granulysin, tumor necrosis factor-alpha, Fas ligand, and/or reactive oxygen species in the activation of cytotoxic or apoptotic pathways [4].

The use of intravenous immunoglobulin in toxic epidermal necrolysis has become common practice [10]; corticosteroids have become controversial as first line therapy for toxic epidermal necrolysis [4]. Although isolated studies have shown decreased mortality (12% versus 25-30% expected mortality) with the early use of intravenous immunoglobulin in toxic epidermal necrolysis [11], a recent meta-analysis of the use of intravenous immunoglobulin in toxic epidermal necrolysis did not find sufficient evidence for decreased mortality when compared with supportive care, but demonstrated trends towards improved mortality with high-dose intravenous immunoglobulin in adults and good prognosis in children [12]. Intensive care and discontinuation of the offending medication are imperative. Re-challenge has led to disease recurrence [4].

Voriconazole is a triazole antifungal used systemically to treat serious antifungal infections. It is indicated for use in the treatment of: invasive aspergillosis, disseminated *Candida* infections, esophageal candidiasis, and other serious fungal infections such as those caused by *Fusarium* species and *Scedosporium apiospermum* [13]. It has gained favor in the treatment of serious fungal infections, particularly in immunocompromised individuals, including those having undergone bone marrow transplantation, organ transplantation, and those suffering from hematologic and other malignancies undergoing chemotherapy. It has also been used as prophylactic antifungal therapy for individuals affected by these conditions.

Voriconazole has been observed to cause a number of cutaneous side effects. Most notable are the photosensitivity and phototoxicity reactions [14,15]. The photosensitivity reactions range from an acute phototoxicity to chronic photodamage of the skin leading to increased risk for cutaneous malignancies. Patients on long term therapy have been found to develop squamous cell carcinoma of the skin [16]. Severe cutaneous adverse reactions including toxic epidermal necrolysis, as we are reporting here, have been reported before and are summarized below [7,8]. Less serious cutaneous side effects such as fixed drug eruption, maculopapular eruption, eczema, dry skin and pruritus, among others, have been reported [13].

Table 1. Reported and Potential Cutaneous Side Effects of Treatment with Voriconazole [7,8,13,14,15,16]

Alopecia	Herpes simplex infection	Skin discoloration
----------	--------------------------	--------------------

Angioedema	Maculopapular rash	Skin disorder, unspecified
Contact dermatitis	Melanoma	Skin, dry (xerosis)
Discoid lupus erythematosus	Melanosis	Skin pain
Eczema	Photosensitivity skin reaction	Stevens-Johnson syndrome
Erythema multiforme	Phototoxicity reaction	Squamous cell carcinoma
Exfoliative dermatitis	Pruritus	Sweating
Fixed drug eruption	Pseudoporphyria	Toxic epidermal necrolysis
Furunculosis	Psoriasis	Urticaria

In addition to our case reported here, at least two prior cases (Huang et al. in 2004 and Curigliano et al. in 2006) have been reported in the literature of voriconazole exposure leading to toxic epidermal necrolysis. In the first case [7], an 81 year-old woman developed signs and symptoms of toxic epidermal necrolysis 10 days after receiving a 7 day course of voriconazole for a *Candida krusei* urinary tract infection. She ultimately developed 40% body surface area involvement, including mucosal involvement, and was treated with intravenous immunoglobulin, 3 g/kg total dose. She survived without reported sequelae. In the second case [8], a 39-year-old man with breast cancer with metastasis received voriconazole as treatment for pulmonary aspergillosis and developed signs and symptoms of toxic epidermal necrolysis 5 days after initiation of voriconazole therapy. He ultimately suffered from 85% body surface area involvement including mucosa and was treated with intravenous immunoglobulin 2g/kg total dose. He survived without reported sequelae. These three cases highlight the risk of developing toxic epidermal necrolysis while undergoing treatment with voriconazole.

Table 2. Demographic and Clinical Characteristics of Reported Cases [7,8]

Cases	Age and Gender	Underlying Condition	Indication for Voriconazole	Time to Onset of Skin Findings	Extent of Skin Involvement	Mucosal Involvement	Treatment	Outcome	Reference
1	81 yo woman	<i>Candida krusei</i> urinary tract infection	Treatment of infection	Ten days	40 percent	Yes (conjunctival hyperemia, oral and vaginal ulcerations)	Intravenous immunoglobulin 3g/kg total dose	Survival without sequelae	Huang et al [7]
2	39 yo man	Breast cancer with metastasis on chemotherapy	Pulmonary aspergillosis infection	Five days	85 percent	Yes (conjunctival injection and oropharyngeal ulcerations)	Intravenous immunoglobulin 2g/kg total dose	Survival without sequelae	Curigliano et al [8]
3	67 yo woman	Chronic lymphocytic leukemia status post allogeneic peripheral blood stem cell transplant	Post-transplant antifungal regimen	Seven days	45 percent	No	Intravenous immunoglobulin 3g/kg total dose	Survival with re-epithelialization with hyperpigmentation	This case report

Clinicians should be aware of voriconazole as a cause of toxic epidermal necrolysis. Physicians are advised to use SCORTEN to evaluate the degree of severity of toxic epidermal necrolysis and to consider the use of intravenous immunoglobulin if toxic epidermal necrolysis is suspected [10]. If a patient develops an exfoliative cutaneous reaction, then voriconazole should be discontinued immediately [13].

References

1. Diaz L and Ciurea AM. Cutaneous and systemic adverse reactions to antibiotics. *Dermatol Ther.* 2012;25:12-22. [PMID: 22591496]
2. French LE. Toxic epidermal necrolysis and Stevens Johnson syndrome: our current understanding. *Allergol Int.* 2006;55(1):9-16. [PMID: 17075281]

3. Bastuji-Garin S RB, Stern RS, Shear NH, Naldi L, Roujeau J-C. Clinical classification of cases of toxic epidermal necrolysis, Stevens-Johnson syndrome, and erythema multiforme. *Arch Dermatol.* 1993;129(1):92-96. [PMID: 8420497]
4. Downey A, Jackson C, Harun N, Cooper A. Toxic epidermal necrolysis: review of pathogenesis and management. *J Amer Acad Dermatol.* 2012;66(6):995-1003. [PMID: 22169256]
5. Auquier-Dunant A, Mockenhaupt M, Naldi L et al. Correlations between clinical patterns and causes of erythema multiforme majus, Stevens-Johnson syndrome, and toxic epidermal necrolysis. *Arch Dermatol.* 2002;138:1019-1024. [PMID: 12164739]
6. Quinn AM, Brown K, Bonish BK, et al. Uncovering histologic criteria with prognostic significance in toxic epidermal necrolysis. *Arch Dermatol.* 2005;141(6):683-687. [PMID: 15967913]
7. Huang DB, Wu JJ, Lahart CJ. Toxic epidermal necrolysis as a complication of treatment with voriconazole. *South Med J.* 2004;97(11):1116-1117. [PMID: 15586606]
8. Curigliano G, Formica V, De Pas T, et al. Life-threatening toxic epidermal necrolysis during voriconazole therapy for invasive aspergillosis after chemotherapy. *Ann Oncol.* 2006;17(7):1174-1175. [PMID: 16410362]
9. Mockenhaupt M, Viboud C, Dunant A, et al. Stevens-Johnson syndrome and toxic epidermal necrolysis: assessment of medication risks with emphasis on recently marketed drugs. The EuroSCAR-Study. *J Invest Dermatol.* 2008;(128):35-44. [PMID: 17805350]
10. Walsh S, Creamer D. IVIG in TEN: time to re-evaluate the efficacy of intravenous immunoglobulin in the management of toxic epidermal necrolysis. *Br J Dermatol.* 2012;167:230-231. [PMID: 22835022]
11. Knowles S, Shear NH. Clinical risk management of Stevens-Johnson syndrome/toxic epidermal necrolysis spectrum. *Dermatol Ther.* 2009;22(5):441-451. [PMID: 19845721]
12. Huang YC, Li YC, Chen TJ. The efficacy of intravenous immunoglobulin for the treatment of toxic epidermal necrolysis: a systematic review and meta-analysis. *Br J Dermatol.* 2012;167:424-432. [PMID: 22458671]
13. VFEND (voriconazole) highlights of prescribing information. <http://labeling.pfizer.com/ShowLabeling.aspx?id=618> (Accessed on June 10, 2014).
14. Malani AN, Aronoff DM. Voriconazole-induced photosensitivity. *Clin Med Res.* 2008;6(2):83-85. [PMID: 18801950]
15. Riahi, RR, Cohen, PR. Voriconazole-associated phototoxicity. *Derm Online J.* 2011;17(2). [PMID: 21382298]
16. Morice C, Acher A, Soufir N, et al. Multifocal aggressive squamous cell carcinomas induced by prolonged voriconazole therapy: a case report. *Case Rep Med.* 2010;351084 [PMCID: PMC3014742]