

# UC Davis

## Dermatology Online Journal

### Title

Erythema elevatum diutinum in a patient with rheumatoid arthritis

### Permalink

<https://escholarship.org/uc/item/2pk4t34w>

### Journal

Dermatology Online Journal, 29(5)

### Authors

Bittencourt, Maraya Semblano  
Serruya, Tally  
Loureiro, Luana de Oliveira  
et al.

### Publication Date

2023

### DOI

10.5070/D329562408

### Copyright Information

Copyright 2023 by the author(s). This work is made available under the terms of a Creative Commons Attribution-NonCommercial-NoDerivatives License, available at <https://creativecommons.org/licenses/by-nc-nd/4.0/>

Peer reviewed

# Erythema elevatum diutinum in a patient with rheumatoid arthritis

Maraya Semblano Bittencourt, Tally Serruya, Luana de Oliveira Loureiro, Aline Dias Coelho de Souza, Camilla Correa Neri, Ana Thais Machado Moutinho, Caren dos Santos Lima

Affiliations: Centro Universitário do Estado do Pará, Belém, Pará, Brazil

Corresponding Author: Maraya de Jesus Semblano Bittencourt, Vileta, 1289 Pedreira, Belém-Pará, Brazil, Tel: 55-91981165237, Email: [marayabittencourt@hotmail.com](mailto:marayabittencourt@hotmail.com)

## Abstract

Erythema elevatum diutinum (EED) is a rare cutaneous neutrophilic vasculitis with many associated diseases reported in the literature. We report a 65-year-old woman with painful and itchy lesions on her elbows, hands, knees, and foot for a year. Histopathologic examination confirmed the diagnosis of erythema elevatum diutinum and treatment with dapsone produced significant clinical improvement within few weeks. Erythema elevatum diutinum is a rare disease that should be considered in patients with violaceous nodular plaques located over the extensor regions of the limbs. Knowledge of this unusual pathology and its association helps to avoid misdiagnosis and late treatment.

Keywords: arthritis, rheumatoid, vasculitis

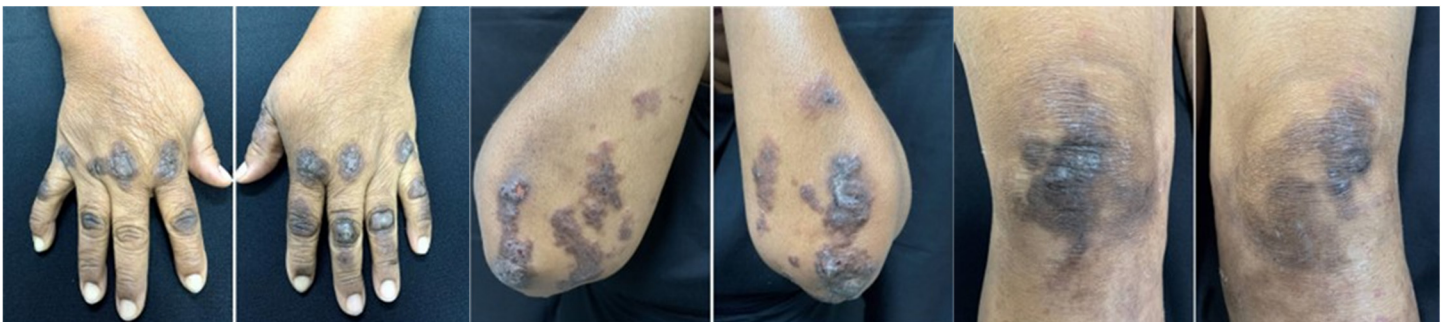## Introduction

Erythema elevatum diutinum (EED) is a rare chronic cutaneous vasculitis that affects adults between 30 and 60 years of age [1]. The classic cutaneous manifestations of EED are papules, nodules, and

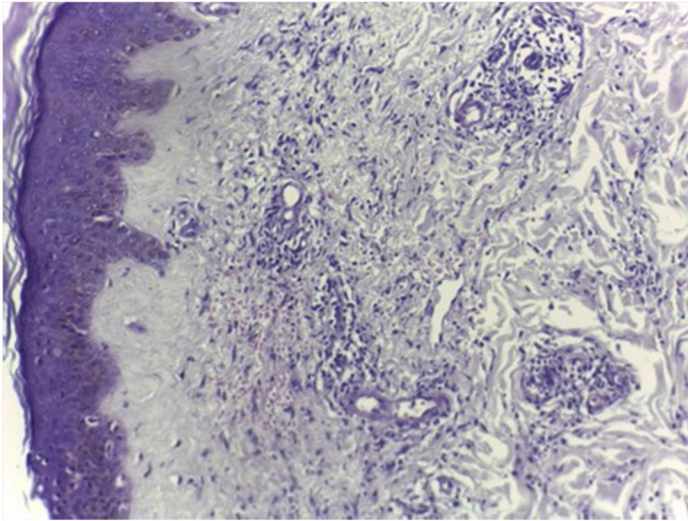
erythematous or violaceous plaques that are usually asymptomatic. Distribution tends to be bilateral and symmetric on extensor surfaces. Extracutaneous manifestations, which are less common, include arthralgias, clinical constitutional manifestations, and eye disease [2].

## Case Synopsis

We report a 65-year-old woman, who presented with painful and itchy lesions on her elbows, hands, knees, and feet for a year. She reported that after four months they progressed to focal ulcerations and were associated with arthralgia. She denied fever or other systemic symptoms. She had a previous history of arterial hypertension, diabetes, and rheumatoid arthritis for 45 years. She was taking methotrexate 20mg per week and prednisone 5mg per day. On dermatological examination she exhibited violaceous infiltrated plaques, some ulcerated, with clear margins and irregular contours. The plaques varied from 2 to 10cm and were located symmetrically on the hands, elbows, knees, and legs (**Figure 1**).



**Figure 1** Violaceous papules and nodules involving the extensor surface of the hand. Indurated violaceous papules and plaques involving the elbow. Violaceous plaques involving the extensor surface of the knees.



**Figure 2.** Medium-power H&E photomicrograph of punch biopsy showing characteristic vascular changes including thickened blood vessel walls with luminal and mural neutrophils, 40 $\times$ .

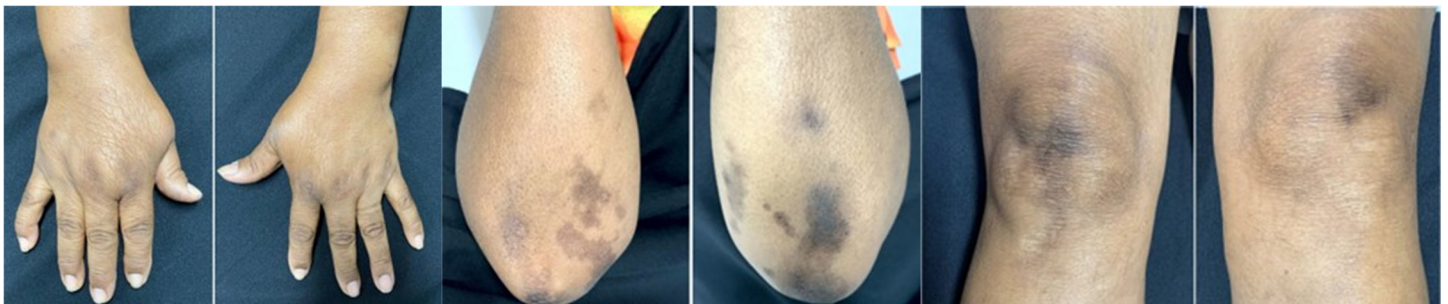Histopathological examination showed vascular proliferation at different levels of the dermis, in which the proliferating elements showed thickening and fibrinoid deposits on the walls, permeated by an inflammatory infiltrate consisting of lymphocytes, histiocytes, and neutrophils with karyorrhexis (**Figure 2**). Fibrosis and diffuse interstitial erythrocyte extravasation were associated. This chronic fibrosing inflammatory process with leukocytoclastic vasculitis was considered to be compatible with EED. Serologies for HIV, hepatitis B, and hepatitis C were negative and serum protein electrophoresis was normal. Rheumatoid factor was present at high titers (90.9IU/ml, normal 10–15IU/ml). The patient was treated with dapsons 100mg per day, with significant improvement of lesions and arthralgia after two weeks of treatment (**Figure 3**).

## Case Discussion

Erythema elevatum diutinum is a rare chronic disease, manifested by erythematous-violaceous papules, nodules, and plaques of symmetrical distribution on the extensor surfaces of the hands, feet, elbows, knees, buttocks, and lower limbs. Other presentations such as vesicular, bullous, and ulcerative morphology have also been reported [3]. Lesions can occur in atypical areas such as the trunk, retroauricular area, or palmoplantar region. Initially, the lesions have a soft consistency and, as they progress, they become hardened due to fibrosis [1]. Plaques are commonly asymptomatic but may be associated with itching, pain, and underlying arthralgias [4]. The course of the disease is chronic with frequent relapses [3].

The pathophysiology of EED involves the deposition of immune complexes in small blood vessels, which leads to an inflammatory response and leukocyte recruitment. The underlying etiology is unknown, but it is suggested to be related to high levels of circulating antibodies formed in response to repeated infection [4]. Erythema elevatum diutinum has been associated with several systemic diseases, including systemic infections, autoimmune conditions, and hematologic diseases [1,5]. Many of the conditions associated with EED are immunogenic and are believed to produce immune dysregulation that initiates the inflammatory cascade, which ultimately leads to clinical disease [4].

Regarding autoimmune diseases associated with EED, there are reports of association with systemic lupus erythematosus, rheumatoid arthritis [6,7], Wegener granulomatosis, and polychondropathies.



**Figure 3.** Residual postinflammatory hyperpigmentation of hand, elbow, and knee lesions after two weeks of dapsons therapy.

Hematologic disorders include monoclonal IgA gammopathy, multiple myeloma, and myelodysplasia [1]. When EED occurs with rheumatoid arthritis, it is a frequent indicator of active disease, often associated with high titers of rheumatoid factor [8]. In our case, the patient had arthralgias concomitant with the skin lesions, which improved after the start of treatment; medication adjustment for rheumatoid arthritis was not necessary.

The histopathology of the lesions shows leukocytoclastic vasculitis, with neutrophilic infiltrate in the small vessels of the upper and middle dermis initially. In advanced stages, capillary walls may show fibrinoid necrosis or fibrosis. None of these findings are pathognomonic for EED [3]. The differential diagnosis should also include Sweet syndrome and neutrophilic rheumatoid dermatitis. Old lesions can be confused with tuberous xanthoma, granuloma annulare, rheumatoid nodules, and multicentric reticulohistiocytosis [1].

The most used treatment is oral dapsone, at a dose of 50 to 150mg per day, with a response rate of up to

80%. It is believed that the efficacy of dapsone in EED is the result of its ability to inhibit myeloperoxidase, chemotaxis, and neutrophil function [9]. As sulfasalazine also has this feature, it has been selected as a potential replacement for dapsone [9]. Erythema elevatum diutinum evolution tends to chronicity, but complete resolution is possible [10].

## Conclusion

Erythema elevatum diutinum is a rare disease that should be considered in patients with violaceous papulonodular plaques located in the extensor surfaces of the extremities. Knowledge of this unusual pathology and its association with rheumatoid arthritis helps to avoid misdiagnosis and late treatment.

## Potential conflicts of interest

The authors declare no conflicts of interest.

## References

1. Mançano VS, Dinato SLM, Almeida JRP, Romiti N. Erythema elevatum diutinum. *An Bras Dermatol*. 2018;93:614-5. [PMID: 30066783].
2. Sandhu JK, Albrecht J, Agnihotri G, Tsoukas MM. Erythema elevatum et diutinum as a systemic disease. *Clin Dermatol*. 2019;37:679-83. [PMID: 31864448].
3. Nguyen GH, Guo EL, Norris D. A rare case of erythema elevatum diutinum presenting as diffuse neuropathy. *JAAD Case Rep*. 2016;21;3:1-3. [PMID: 28050587].
4. Doktor V, Hadi A, Hadi A, Phelps R, Goodheart H. Erythema elevatum diutinum: a case report and review of literature. *Int J Dermatol*. 2019;58:408-15. [PMID: 30074624].
5. Cardis MA, Sowash MG, Mosojane KI, Kovarik C, Williams V. HIV-associated erythema elevatum diutinum: a case report and review of a clinically distinct variant. *Dermatol Online J*. 2018;24(5). [PMID:30142732].
6. Zhao J, Wang Y. Erythema elevatum diutinum: an unusual cutaneous vasculitis associated with rheumatoid arthritis. *Rheumatology (Oxford)*. 2020;15:keaa177. [PMID: 32294207].
7. Collier PM, Neill SM, Branfoot AC, Staughton, RC. Erythema elevatum diutinum— a solitary lesion in a patient with rheumatoid arthritis. *Clin Exp Dermatol*. 1990;15:394-5. [PMID: 2225548].
8. Nakajima H, Ikeda M, Yamamoto Y, Kodama H. Erythema elevatum diutinum complicated by rheumatoid arthritis. *J Dermatol*. 1999;26:452-6. [PMID: 10458086].
9. Chen ML, Chlopik A, Hoang MP, Smith GP. Complete resolution of erythema elevatum diutinum using oral sulfasalazine. *Dermatol Online J*. 2017; 23:(10). [PMID: 29469798].
10. Wollina U, Krönert C, Koch A, Schönlebe J, Vojvodic A, Lotti T. Erythema elevatum diutinum - two case reports, two different clinical presentations, and a short literature review. *Open Access Maced J Med Sci*. 2019; 7:3039-42. [PMID: 31850118].