

UC Davis

Dermatology Online Journal

Title

Porokeratosis ptychotropica: a rare variant that is commonly misdiagnosed

Permalink

<https://escholarship.org/uc/item/1vh663z3>

Journal

Dermatology Online Journal, 26(6)

Authors

Hoang, Nguyen
Harper, Haleigh E
Jibbe, Atieh
et al.

Publication Date

2020

DOI

10.5070/D3266049327

Copyright Information

Copyright 2020 by the author(s). This work is made available under the terms of a Creative Commons Attribution-NonCommercial-NoDerivatives License, available at <https://creativecommons.org/licenses/by-nc-nd/4.0/>

Peer reviewed

Porokeratosis ptychotropica: a rare variant that is commonly misdiagnosed

Nguyen Hoang¹ MD, Haleigh E Harper² BS, Atieh Jibbe³ MD, Spyros M Siscos³ MD, Allison L Cargnel⁴ MD, David L Kaplan³ MD

Affiliations: ¹Department of Pediatrics, Children's Mercy Hospital, Kansas City, Missouri, USA, ²University of Kansas School of Medicine, Kansas City, Kansas, USA, ³Department of Internal Medicine, Division of Dermatology, University of Kansas Medical Center, Kansas City, Kansas, USA, ⁴ Department of Dermatopathology, Menorah Medical Center, Overland Park, Kansas, USA

Corresponding Author: Atieh Jibbe MD, 3901 Rainbow Boulevard MS 2025, Kansas City, KS 66160, Tel: 316-992-3876, Email: ajibbe@kumc.edu

Abstract

Porokeratosis ptychotropica (PP) is a rare variant of porokeratosis characterized by pruritic, scaly papules and plaques localized to the perianal and gluteal cleft regions. Clinically, PP resembles other common disorders, resulting in frequent misdiagnosis. The diagnosis of PP often takes several years to make, therefore many reported cases in the literature described the late stages of PP. We report a case of PP diagnosed at an early stage. By presenting our patient, we aim to raise further awareness of PP to avoid a delay in diagnosis, thus preventing long term complications of this rare entity.

Keywords: porokeratosis ptychotropica, cornoid lamella, porokeratoses

Introduction

Porokeratosis is a group of cutaneous disorders characterized by abnormal keratinization leading to the formation of cornoid lamellae, the characteristic histological feature. Clinically, porokeratosis presents as distinctive keratotic papules or annular plaques with elevated, ridge-like borders [1]. The lesions are generally asymptomatic, although some may present with intermittent pruritis or discomfort. Several clinical variants of porokeratosis have been described, with disseminated superficial actinic porokeratosis being the most common type [1].

Porokeratosis ptychotropica (PP) is a rare variant characterized by lesions limited to the perianal and gluteal regions. Porokeratosis ptychotropica is frequently mistaken for other skin conditions and it often takes several years for the diagnosis to be confirmed [1, 2]. There are about 30 reported cases of this rare variant and of these 30 cases, very few describe the early manifestations of the disease as seen in our case. We present a patient with PP that was diagnosed during the early stages. By bringing awareness to the early signs of PP, we hope to improve diagnostic accuracy and prevent long-term complications of this rare entity.

Case Synopsis

A 50-year-old man presented for an annual skin examination with itchy lesions on the gluteal cleft of several months' duration. The patient initially noticed a small pruritic bump on the right medical buttock, thought to be an insect bite. He soon developed multiple new lesions on his left medial buttock. On physical exam, a 13mm, well-demarcated, hypopigmented, annular, scaly, hyperkeratotic plaque was noted along the left gluteal cleft (**Figure 1A**), and similar hyperkeratotic papules were observed on the right gluteal cleft (**Figure 1B**). Biopsy of a plaque revealed cornoid lamellae with classic changes consistent with porokeratosis. (**Figure 2**). Lesions were treated with

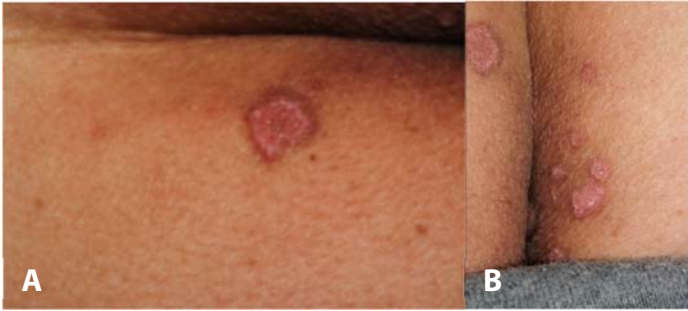

Figure 1. **A)** Hyperkeratotic, oval plaque with scaling characteristic of porokeratosis ptychotropica. **B)** Satellite lesions in various stages on the right gluteal cleft.

liquid nitrogen cryotherapy with improvement in both appearance and symptoms.

Case Discussion

Porokeratosis ptychotropica is a rare variant of porokeratosis confined to the gluteal cleft and

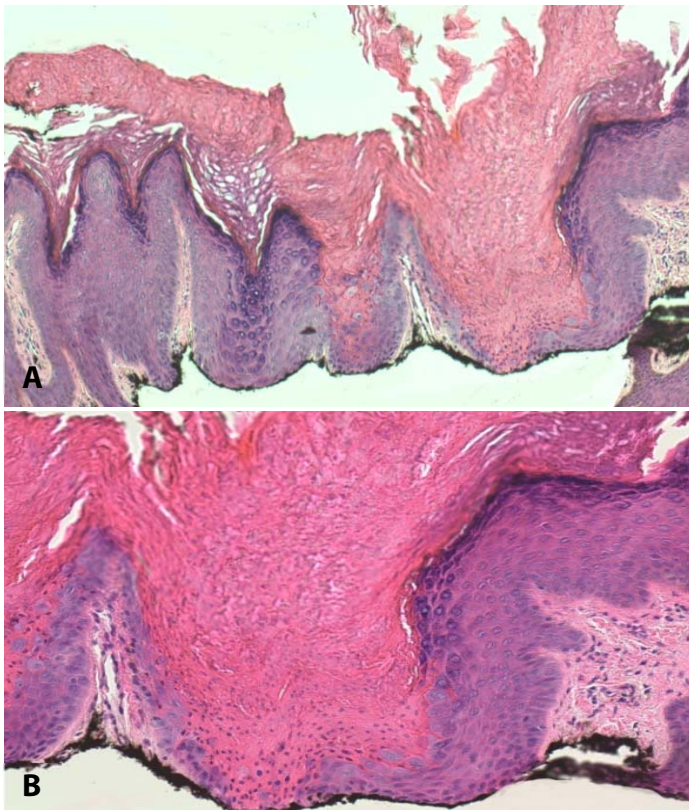


Figure 2. **A)** Invagination of squamous epithelium forming an epidermal dell. There is underlying loss of the granular cell layer, and an overlying column of parakeratosis. H&E, 4 \times . **B)** Cornoid lamella. Closer observation of an epidermal dell demonstrating a lack of granular cell layer with retention of nuclei at the superficial layer characteristic of parakeratosis. H&E, 20 \times .

perianal region. The etiology is not completely understood, but it is considered a multifactorial disease of abnormal epidermal keratinization [3]. A case series has described PP in two brothers and a maternal aunt, suggesting that an autosomal dominant mode of inheritance may be associated [4]. Porokeratosis ptychotropica occurs more frequently in males than females. In a review of twenty-three cases, 90% of patients were males between the ages of 27 and 84 years [4].

Porokeratosis ptychotropica initially presents as reddish-brown papules and plaques localized to the gluteal cleft. Unlike other variants of porokeratosis, PP is commonly associated with pruritis. Additionally, it lacks the classic elevated peripheral ridges, presenting instead as hyperkeratotic or verrucous plaques [1, 3, 4]. Satellite lesions develop over the course of several years and eventually coalesce into a large, symmetric, scaly plaque with a “butterfly-shaped” appearance [1]. This classic characterization is commonly used to describe PP, although it pertains mainly to late presentations of the disease. In almost all reported cases of PP in the literature, the time from onset of lesion to diagnosis of PP ranged between one year and thirty years. Many reported cases took decades before the diagnosis was confirmed [1, 3, 4].

Histologic findings are essential for confirming the diagnosis of PP. The appearance of epidermal hyperkeratosis, cornoid lamellae, and dyskeratotic keratinocytes are distinctive findings. Unlike other porokeratosis variants, the cornoid lamellae found in PP are not limited to the periphery, but rather found throughout the lesion [3]. This characteristic aids in distinguishing PP from other similar disorders. Immunohistochemistry of cornoid lamella has been found to demonstrate an overexpression of p53 and downregulation of p16, suggesting the role of chronic inflammation and genomic instability in the progression of porokeratosis to cancer [2]. Malignant transformation has been reported in all major variants of porokeratosis, with squamous cell carcinoma being the most common. Recently, a case of malignancy associated with PP was reported and described the development of squamous cell carcinoma in a 70-year-old patient with an eighteen-

year history of PP [5]. The long history of PP supports the idea of chronic inflammation as a role in malignancy. Many PP cases are diagnosed decades after the onset of lesions, making the chronicity of the disease a significant risk factor for malignancy. Therefore, diagnosing PP at an earlier stage is important in avoiding long-term complications that may arise.

Compared to other types of porokeratosis, the subtle elevated ridges in PP makes the diagnosis challenging. An insidious, scaly, circular plaque on the buttock is most commonly psoriasis and was our leading diagnosis. Other common conditions were considered, such as atopic dermatitis and lichen simplex chronicus. Infections such as candidiasis and dermatophyte infection were lower on our differential diagnosis, given the pale appearance and lack of erythema. A painless lesion with raised borders should raise the question for syphilis. However, our patient's older age and lack of sexual contact, combined with persistence of the condition for several months made syphilis a less likely diagnosis. The biopsy showed distinctive parakeratotic columns with underlying dyskeratosis and pale keratinocytes, which are characteristic of cornoid lamella and confirmed PP as the diagnosis.

References

1. Joshi R, Minni K. Genitogluteal porokeratosis: a clinical review. *Clin Cosmet Investig Dermatol*. 2018;11:219-29. [PMID: 29750048].
2. Contreras-Ruiz J, Toussaint-Caire S, Torres-Camacho P, Villa-Castro VB. Porokeratosis ptychotropica: a diagnostic and therapeutic challenge. *J Eur Acad Dermatol Venereol*. 2018;32:e114-e5. [PMID: 28940636].
3. Yeo J, Winhoven S, Tallon B. Porokeratosis ptychotropica: a rare and evolving variant of porokeratosis. *J Cutan Pathol*. 2013;40:1042-7. [PMID: 24274427].
4. Takiguchi RH, White KP, White CR Jr., Simpson EL. Verrucous porokeratosis of the gluteal cleft (porokeratosis ptychotropica): a rare disorder easily misdiagnosed. *J Cutan Pathol*. 2010;37:802-7. [PMID: 19638069].
5. Mazori DR, Shvartsbeyn M, Meehan SA, Tarsis SL. Transformation of porokeratosis ptychotropica into invasive squamous cell carcinoma. *Int J Dermatol*. 2017;56:679-80. [PMID: 28197991].
6. Ferreira FR, Lessa PP, Alvarenga ML. Genitogluteal porokeratosis - case report. *An Bras Dermatol*. 2013;88:438-40. [PMID: 23793197].

Treatment of this condition remains discouraging with variable responses to keratolytics, cryotherapy, 5-fluorouracil, imiquimod, calcipotriol, diclofenac, corticosteroids, topical antifungals, and lasers [1, 6]. Fortunately, our patient's condition responded remarkably well to cryotherapy.

Conclusion

Porokeratosis ptychotropica is a rare variant of porokeratosis with about 30 reported cases in the literature. The diagnosis of PP often takes several years to make, with many patients suffering for decades before the diagnosis is made. This is concerning given the reported risk of malignant transformation associate with long-term PP. We present this case to provide more information on the early presentation of PP. Raising further awareness of this rare entity may lead to an early diagnosis, and ultimately preventing long-term complications such as cancer in our patients.

Potential conflicts of interest

The authors declare no conflicts of interest.