

UC Davis

Dermatology Online Journal

Title

Unusually extensive scalp ulcerations manifested in pemphigus erythematosus

Permalink

<https://escholarship.org/uc/item/1vd4j2t2>

Journal

Dermatology Online Journal, 24(1)

Authors

Chandan, Neha
Lake, Eden P
Chan, Lawrence S

Publication Date

2018

DOI

10.5070/D3241037928

Copyright Information

Copyright 2018 by the author(s). This work is made available under the terms of a Creative Commons Attribution-NonCommercial-NoDerivatives License, available at <https://creativecommons.org/licenses/by-nc-nd/4.0/>

Peer reviewed

Unusually extensive scalp ulcerations manifested in pemphigus erythematosus

Neha Chandan MPH, Eden P Lake MD, Lawrence S Chan MD

Affiliations: University of Illinois College of Medicine, Chicago, Illinois

Corresponding Author: Neha Chandan, University of Illinois College of Medicine, 808 S. Wood Street, R380 MC624, Chicago, IL 60612, Email: nchand8@uic.edu

Abstract

Senear-Usher Syndrome, or pemphigus erythematosus, is an autoimmune skin blistering disorder with an overlapping clinical presentation of pemphigus foliaceus and lupus erythematosus. Lesions typically involve the scalp, face, and upper chest or back. This case study focuses on a patient who presented with progressive scalp ulcers, hyperpigmentation, and eroded plaques with overlying hemorrhagic crust. Pemphigus erythematosus was diagnosed with direct immunofluorescence, demonstrating immunoglobulin G and complement deposition both intercellularly and at the dermoepidermal junction. The patient is continuing treatment with systemic steroids and steroid-sparing immunosuppressants.

Keywords: pemphigus erythematosus, Senear-Usher Syndrome, lupus erythematosus, pemphigus foliaceus, dermoepidermal junction

Introduction

Senear-Usher syndrome or pemphigus erythematosus (PE) is a rare autoimmune blistering disease that is a more localized form of pemphigus foliaceus (PF). Classically, patients present with small, flaccid bullae with scaling and crusting; mucous involvement is rare [1, 2]. Diagnosis is made via a combination of pathological findings of PF and direct immunofluorescence (DIF) demonstrating immunoglobulin G (IgG) and complement deposition both intercellularly and at the dermoepidermal junction (DEJ), [3]. Specifically, DIF shows IgG autoantibodies from the patient's sera binding to

the epithelial cell surface; this DIF finding is the most consistent diagnostic feature with variable serology and clinical presentation. However, the significance and etiology of the linear deposition of IgG and complement at the DEJ is under academic debate.

Case Synopsis

A 24-year-old woman presented to the emergency department (ED) with several months of a progressive scalp ulcer. The ulcer began originally in 2012 as a coin-shaped lesion and was initially diagnosed as discoid lupus erythematosus with histology confirmation. The patient was treated with topical triamcinolone cream, which was ineffective. A few months prior to her ED presentation, the patient noted skin lesions also progressed to involve her back, arms, and face and she finally presented to ED owing to increased

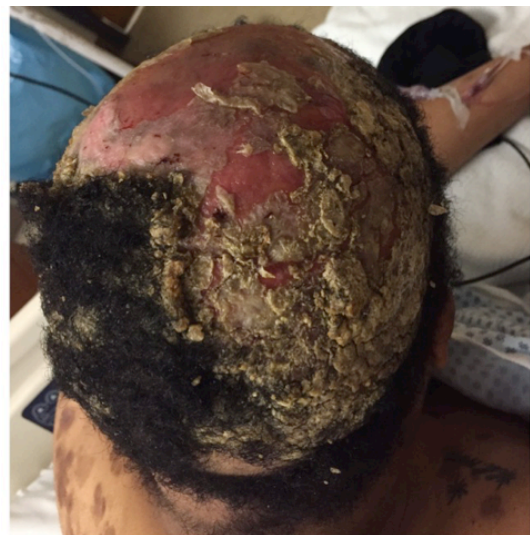

Figure 1. Patient's right scalp, face, and upper back. The scalp is superficially debrided, revealing an erythematous, eroded, boggy scalp. Crusting yellow-brown debris is seen on the remaining scalp. Facial/malar sparing is evident.

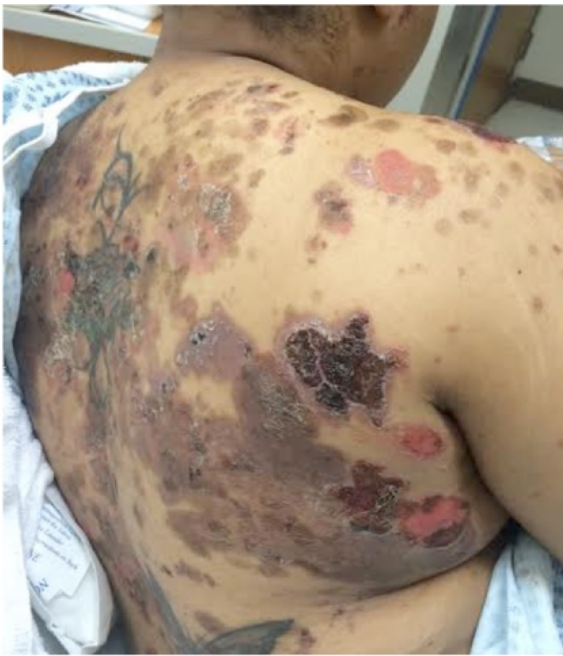

Figure 2. The upper back shows violaceous and hyperpigmented patches as well as flaccid, slightly erythematous bullae.

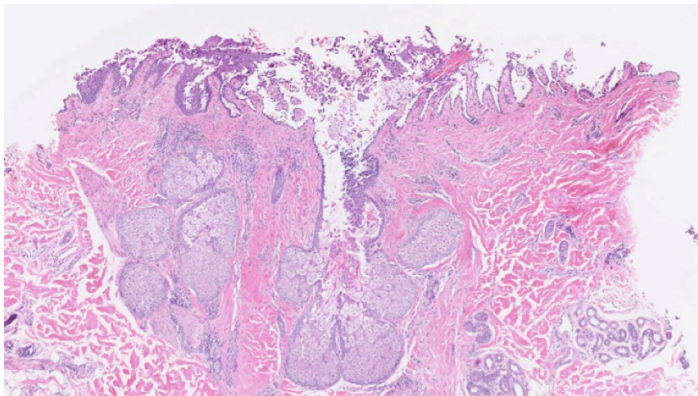


Figure 3. H&E of skin of right scalp demonstrates suprabasilar and intraepidermal acantholysis with no interface or basal vascular changes. H&E, 4%.

pain and purulence from the scalp ulcer.

Upon physical examination, the patient's scalp was superficially debrided, revealing an erythematous, eroded, boggy scalp that was very tender to palpation (**Figure 1**). The remaining scalp showed crusting and scale adherent to the residual hair, with yellow to brown debris. Her face had a few erythematous papules and numerous faint hyperpigmented macules, with overall facial and malar sparing. There was no conjunctival injection of the eyes and no erosion or erythema on the oral mucosa. The bilateral extensor arms had erythematous, hyperpigmented macules and patches as well as crusted plaques and a few flaccid bullae, one of which showed a positive

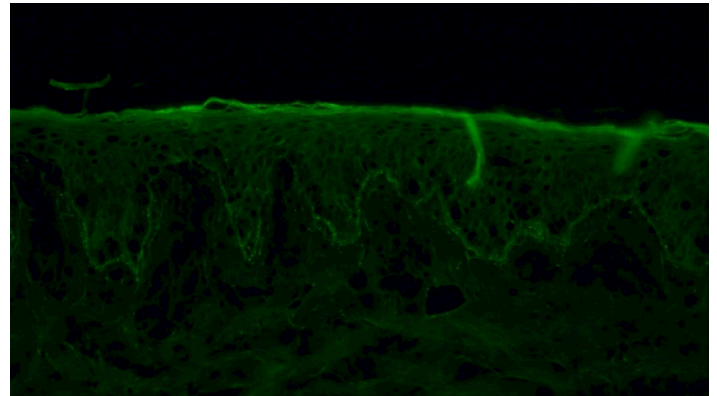


Figure 4. IgG R forearm. Strong direct immunofluorescence is seen with granular IgG deposition along the dermoepidermal junction as well as intraepidermal intercellular deposition. 4%.

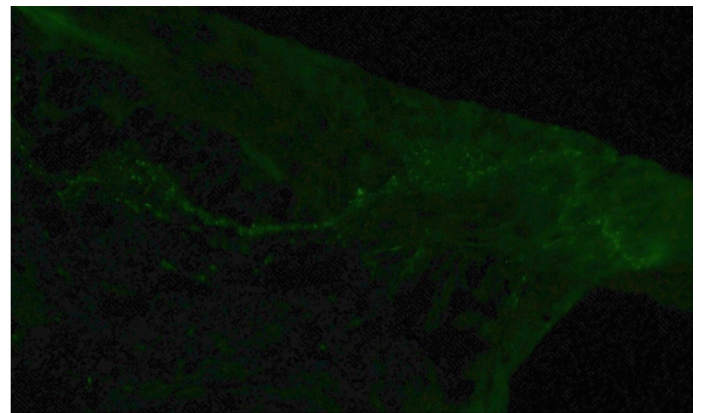


Figure 5. Pathology C3 of right forearm. Strong direct immunofluorescence is seen with speckled-to-granular deposition of C3 along the dermoepidermal junction. 4%.

Alboe-Hansen sign with adjacent bulla extension with lateral pressure. The bilateral anterior lower extremities had erythematous crusted plaques. The lower abdomen had one large erythematous erosion as well as hyperpigmented macules and patches and one violaceous plaque with overlying crust. The upper to mid-back had erythematous, violaceous, and hyperpigmented patches and eroded plaques, some with overlying hemorrhagic crust (**Figure 2**). Some macules and patches were annular in configuration with a hyperpigmented rim and central hypopigmentation. The upper back had a few flaccid, slightly erythematous bullae. Overall, 20% of body surface was affected, with significantly more scalp

involvement than was noted on the rest of the body.

Laboratory testing showed elevated complement 3 levels of 177 mg/dl (normal: 79-152) and an elevated erythrocyte sedimentation rate of 55 mm/hr (normal: 0-20). Enzyme Linked Immunosorbent Assays (ELISA) for IgG desmoglein 3 and 1 antibodies were elevated to 69 units and 340 units, respectively (normal: < 20). Of note, a full workup for systemic lupus by a rheumatology consultant was negative during the patient's treatment course. Her labs were negative or within normal limits for complete blood count, basic metabolic profile, urinalysis, antinuclear antibody, antibodies to double-stranded DNA and single-stranded DNA, HIV antibody, hepatitis acute panel, and Quantiferon Gold assay. Blood culture showed no growth and an X-ray of the skull was negative for osseous destruction. Histopathology of the skin of the right scalp using hematoxylin and eosin stains showed suprabasilar and intraepidermal acantholysis with no interface or basal vacuolar changes (**Figure 3**). Herpes simplex virus and periodic acid-Schiff stains were also negative. DIF of the skin of the right forearm was consistent with PE with positive IgG deposition along the dermal-epidermal junction as well as intercellularly (**Figure 4**) and positive C3 along the DEJ (**Figure 5**).

The patient was treated with systemic steroids during her hospitalization. She received intravenous vancomycin and oral clindamycin for superimposed infection of the scalp with methicillin-resistant *Staphylococcus aureus*. Upon discharge from her first hospitalization, the patient was prescribed oral prednisone 60 milligrams daily, which she took for one month. The patient was asked to return for follow-up but could not, owing to lack of insurance. Instead, she presented again to the ED after six weeks, seeking further treatment. She had improved with the prednisone but was observing recurrence. No additional medications could be started owing to lack of insurance. At her most recent visit, upon obtaining insurance coverage, the workup was initiated to start her on a steroid-sparing immunosuppressant.

Case Discussion

Pemphigus erythematosus was first described in 1926 by Dr. Senear and Dr. Usher in a case series of 11 patients [4]. The case series demonstrated an

overlapping clinical presentation of PF and lupus erythematosus, seen in middle-aged patients with higher prevalence in females. Clinically, the patient often has malar involvement that mimics a severe seborrheic dermatitis with well-defined erythematous, scaly, crusted plaques [4]. Non-facial lesions may begin as small, flaccid bullae with positive Absoe-Hansen and Nikolsky signs, favoring the upper trunk and face, although lesions have been reported to extend to the feet [2, 4]. Lesions often resolve with hyperpigmentation. Consistent with the clinical findings in PF, mucosal involvement in PE is rare [1]. This patient has an unusual presentation with significant scalp involvement and lack of a prominent facial seborrheic or malar dermatitis.

Diagnosis of PE is made with DIF demonstrating IgG and complement deposition both intercellularly and at the DEJ, along with clinical and pathological findings of pemphigus foliaceus. This DEJ deposition (defined particularly in non-lesional skin) is occasionally referred to as a lupus band [5]. It should be noted that complement at the basement membrane may be seen in PF. However, the presence of immunoglobulins at the junction is rare [3]. Positive antinuclear antibody serology is variably positive; 30-80% of patients have positive ANA titers. PE patients rarely meet the full diagnostic criteria for systemic lupus erythematosus [2]. Cases have been reported with normal lupus serologies, normal complement studies, and normal inflammatory markers [3]. ELISA serology is also helpful, often yielding positivity for both antibodies to desmoglein 1 and desmoglein 3, as seen in this patient. Histopathology alone demonstrates acantholysis within the superficial epidermis, consistent with PF [1, 6].

There is an academic debate regarding the significance and etiology of the linear deposition of IgG and complement at the DEJ. Both PE and PF have been reported to have severe exacerbations with UV exposure. It has been demonstrated that in vivo high doses of ultraviolet (UV) exposure can induce cleavage of the desmoglein 1 ectodomain, and in PF the auto-antibodies to desmoglein 1 can precipitate the cleaved ectodomain along the basement membrane, resulting in DEJ deposition (often referred to as a lupus band), [7]. These findings may be present on only UV-exposed sites in a patient

with PE. This same finding can be seen in other forms of cutaneous lupus, with DEJ deposition present on sun-exposed lesional skin but not on sun-exposed non-lesional skin [8].

Pemphigus erythematosus is often easier to manage than pemphigus vulgaris. Treatments such as systemic prednisone as well as topical corticosteroids and dapsone may be particularly effective [1, 9]. Other potential treatments include methotrexate, cyclophosphamide, and azathioprine. Avoidance of UV exposure is critical for the overall management of both PE and PF.

Conclusion

Pemphigus erythematosus presents as overlapping pemphigus foliaceus and lupus erythematosus. This patient has an unusual presentation with significant scalp involvement and lack of a prominent facial seborrheic or malar dermatitis. Pemphigus erythematosus is most consistently diagnosed via DIF demonstrating IgG and complement deposition both intercellularly and at the DEJ. High doses of ultraviolet exposure induce cleavage of the desmoglein 1 ectoderm, and autoantibodies to desmoglein 1 produce a lupus band on UV-exposed sites. Current treatment of PE consists of systemic corticosteroids, dapsone, and/or immunosuppressants.

References:

1. Amerian M, and Ahmed R. Pemphigus Erythematosus: Senear-Usher Syndrome. *Int J Dermatol*. 1985; 16-25. [PMID: 3888871].
2. Pritchett EN, et al. Pruritic, Pink Scaling Plaques on the Face and Trunk. Pemphigus Erythematosus. *JAMA Derm*. 2015; 151(10):1123-4. [PMID: 26267852].
3. Chorzelski T, et al. Immunopathological investigations in the Senear Usher syndrome (coexistence of pemphigus and lupus erythematosus). *Br J Dermatol*. 1967; 80(4):211-217. [PMID: 4869676].
4. Jordan RE. "An unusual type of pemphigus combining features of lupus erythematosus" by Senear and Usher, June 1926. Commentary: Pemphigus erythematosus, a unique member of the pemphigus group. *Arch Dermatol*. 1982;118(10):723-42. [PMID: 6753755].
5. Okatrina DAM, et al. The IgG "Lupus-Band" Deposition Pattern of Pemphigus Erythematosus. *Arch Derm*. 2012; 148(10):1173-1174. [PMID: 22801864].
6. Pérez-Pérez ME, et al. Autoantibodies in Senear-Usher syndrome: cross-reactivity or multiple autoimmunity? *Autoimmune Dis*. 2012; 2012:296214. [PMID: 23320149].
7. Makino T, et al. Induction of skin lesions by UVB irradiation in a case of pemphigus erythematosus. *Acta Derm Venereol*. 2014; 94(4):487-488. [PMID: 24356850].
8. Reis VM, et al. UVB-induced acanthosis in endemic Pemphigus foliaceus (Fogo selvagem) and Pemphigus vulgaris. *J Am Acad*

- Dermatol*. 2000; 42(4):571-6. [PMID: 10727300].
9. Amerian M and Ahmed R., Pemphigus erythematosus. *J Amer Acad Dermatol*. 1984; 10(2):215-222. [PMID: 6371067].