

UC Davis

Dermatology Online Journal

Title

Vulvar syringomas as a part of nonfamilial generalized eruptive form: Unusual lesions leading to pseudohyper-trophy of the labia majora

Permalink

<https://escholarship.org/uc/item/1rx2v8hc>

Journal

Dermatology Online Journal, 24(3)

Authors

Kavak, Ayşe
Yıldız, Nimet Yeşim
Topkarci, Zeynep
[et al.](#)

Publication Date

2018

DOI

10.5070/D3243038620

Copyright Information

Copyright 2018 by the author(s). This work is made available under the terms of a Creative Commons Attribution-NonCommercial-NoDerivatives License, available at <https://creativecommons.org/licenses/by-nc-nd/4.0/>

Peer reviewed

Vulvar syringomas as a part of nonfamilial generalized eruptive form: Unusual lesions leading to pseudohypertrophy of the labia majora

Ayşe Kavak¹, Nimet Yeşim Yıldız¹, Zeynep Topkarcı¹, Bilgen Erdoğan¹, Nurten Sever², Didem Canoğlu²

Affiliations: ¹Bakırköy Dr. Sadi Konuk Research & Training Hospital, Dermatology Clinic, İstanbul, Turkey, ²Bakırköy Dr. Sadi Konuk Research & Training Hospital, Pathology Clinic, İstanbul, Turkey

Corresponding Author: Ayşe Kavak MD, Bakırköy Dr. Sadi Konuk Research&Training Hospital, Dermatology Clinic, İstanbul, Turkey, Tel: 90 532 3616264, Email: ayse.kavak1@gmail.com

Abstract

We present a case of eruptive generalized syringoma with vulvar involvement. This case is unique in terms of being a nonfamilial, linear variant, leading to pseudohypertrophy of the labia majora.

Keywords: eruptive, generalized, nonfamilial, syringoma, vulva

Introduction

The vulva is the second and third most common location in localized and familial syringomas, respectively. However, prevalence of vulvar syringomas is not well-known in the nonfamilial generalized variant [1]. Herein, we presented a patient with nonfamilial, eruptive generalized syringomas leading to pseudohypertrophy of the labia majora. The lesions also had a roughly linear pattern.

Case Synopsis

A 44-year-old woman was referred to the vulvar clinic for asymptomatic lesions. She had been diagnosed as having eruptive generalized syringomas with synchronous development of the vulvar papules for 15 years. Her medical and family histories were unremarkable.

Dermatologic examination revealed asymptomatic, multiple, 3-10 mm, reddish-brown, yellow-brown, hyperpigmented papules, some forming plaques, with a symmetric distribution on the labia majora. Lesions were arranged linearly, roughly in a dermatomal pattern (**Figure 1**). Multiple, yellowish-brown, 2-3 mm papules were noted on the neck, axilla, submammary and inguinal areas, and upper portion of the lower extremities. Periorbital region, oral mucosa, and nails were spared.

Complete blood count, erythrocyte sedimentation rate, fasting glucose, HbA1C, TSH, and hepatic and

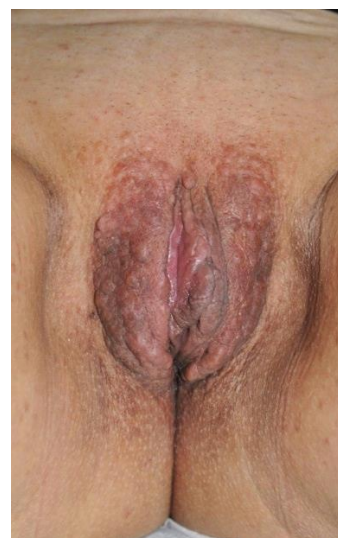

Figure 1. Widespread papules with linear array and pseudohypertrophy of the labia majora.

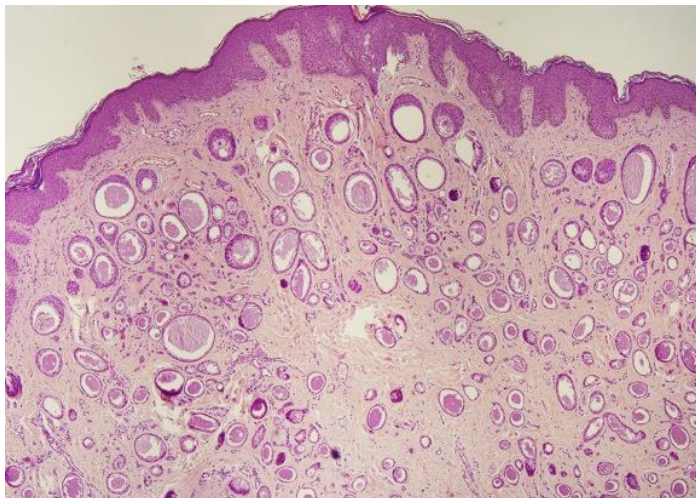


Figure 2. Numerous ductules lined by flattened cuboidal epithelium, some with colloid-like luminal debris. (H&E, 40 \times).

renal function tests were within normal limits. Histopathologic examination of an incisional biopsy revealed a benign, well-circumscribed, dermal-located neoplastic lesion showing small solid and ductal structures in the sclerotic collagenized stroma without epidermal involvement. Ductal structures were usually lined by two rows of flattened cuboidal epithelium with small nuclei; most of them had colloid-like material in the lumens. In addition, "comma-like" or "tadpole-like" patterns were observed. Mitotic figures were absent (**Figure 2**). Similar findings had been observed in a punch biopsy from extragenital papules.

Vulvar syringomas associated with the eruptive generalized variant were diagnosed. The patient was informed about the entity and planned to follow-up without treatment.

Case Discussion

Unusual locations for sporadic syringomas such as vulva, palms, and neck are common in familial syringoma cases [1]. In the localized variant, syringomas can be seen with isolated vulvar

involvement or associated with periorbital and cheek lesions [2]. Williams and Shinkai [1] reported that eruptive syringomas were mostly distributed over the trunk, neck, and extremities (92.6%), with some distributed over the face and neck (7.4%). To our knowledge, vulvar syringoma as a nonfamilial eruptive generalized variant has not been reported in the English literature.

Vulvar syringomas usually consist of bilateral, small, pruritic, multiple flesh-colored or brownish papules [2]. However, atypical presentations might be seen with nodular, cystic, and tumoral forms. Widespread involvement of the entire vulva is unusual. Other unusual presentations may clinically mimic milia, lichen planus, and lichen simplex chronicus as well [1-4]. Our patient had an extraordinary clinical presentation with pseudohypertrophy of the labia majora mimicking tumors. In addition, the roughly linear arrangement of papules noted in this case has not been mentioned before. This linearity was consistent with a dermatomal pattern even if not a perfect match. Parallel arrangement along skin lines of eruptive syringomas in extragenital areas might be comparative to the pattern of vulvar lesions seen in our case.

Syringoma is rarely associated with Down syndrome and diabetes mellitus [1]. An association of some tumoral syndromes such as Brooke-Spiegler syndrome has been mentioned [1]. The presented patient had neither abnormal clinical and laboratory findings nor other cutaneous tumors.

Conclusion

Our presented case had some unique features in terms of a linear or dermatomal pattern that lead to hypertrophy of the labia majora. Although the vulva is a common location for familial and localized forms of syringomas, it seems these are rarely encountered in nonfamilial, eruptive generalized cases.

References

- Williams K, Shinkai K. Evaluation and management of the patient with multiple syringomas: A systematic review of the literature. *J Am Acad Dermatol.* 2016;74(6):1234-40 e9. [PMID: 26850654].
- Huang YH, Chuang YH, Kuo TT, Yang LC, Hong HS. Vulvar syringoma: a clinicopathologic and immunohistologic study of 18 patients and results of treatment. *J Am Acad Dermatol.* 2003;48(5):735-9. [PMID: 12734503].
- Ciarloni L, Frouin E, Bodin F, Cribier B. Syringoma: A clinicopathological study of 244 cases. *Ann Dermatol Venerol.* 2016;143(8-9):521-8. Epub 2016/04/27. [PMID: 27112697].
- Dereli T, Turk BG, Kazandi AC. Syringomas of the vulva. *Int J GynaecolObstet.* 2007;99(1):65-6. Epub 2007/06/26. [PMID: 17588575].

