

UC Davis

Dermatology Online Journal

Title

Eruptive purpuric papules on the arms; a case of chemotherapy-induced inflammation of actinic keratoses and review of the literature

Permalink

<https://escholarship.org/uc/item/1151d3qx>

Journal

Dermatology Online Journal, 20(1)

Authors

Chambers, Cindy J
Liu, Helen
White, Clifton R
et al.

Publication Date

2014

DOI

10.5070/D3201021246

Copyright Information

Copyright 2014 by the author(s). This work is made available under the terms of a Creative Commons Attribution-NonCommercial-NoDerivatives License, available at <https://creativecommons.org/licenses/by-nc-nd/4.0/>

Peer reviewed

Case Presentation

Eruptive purpuric papules on the arms; a case of chemotherapy-induced inflammation of actinic keratoses and review of the literature

Cindy J. Chambers, MD, MAS, MPH¹, Helen Liu, MD², Clifton R. White, MD², Kevin P. White², and Victoria R. Sharon, MD^{1,2}

Dermatology Online Journal 20 (1): 5

¹University of California, Davis

²Oregon Health and Science University

Correspondence:

Victoria Sharon, MD
University of California, Davis
Department of Dermatology
3301C Street, Suite 1400

Abstract

Chemotherapy-induced inflammation of actinic keratosis can present in patients with subclinical actinic keratoses that become erythematous and pruritic within weeks of initiating systemic chemotherapy. The reaction is limited to sun-exposed areas and, classically, histologic findings of parakeratosis and epidermal necrosis with keratinocyte nuclear pleomorphism are present. Exuberant reactions with extensive epidermal necrosis may lead to subepidermal vesiculation. We report a case of a 67-year-old man with a history of chronic hepatitis B virus infection and recently diagnosed squamous cell carcinoma of the lung who was noted to have progressive asymptomatic violaceous papules on the extensor forearms and distal upper arms while hospitalized for possible sepsis following initiation of chemotherapy. A dermatology consultation was requested to rule out possible vasculitis. It is important to recognize chemotherapy-induced inflammation of actinic keratoses in predisposed patients; it may be managed successfully with topical corticosteroids and does not necessitate discontinuation of the offending chemotherapeutic agent.

Keywords: Chemotherapy eruption, Actinic Keratoses, Purpura, Purpuric Papules, Violaceous Papules, Purple Red Macules, Vasculitis, Sepsis

Case synopsis

A 67-year-old man with a history of chronic hepatitis B virus infection and recently diagnosed squamous cell carcinoma of the lung was noted to have asymptomatic violaceous papules of the extensor forearms and distal upper arms while hospitalized for possible sepsis following initiation of chemotherapy. The lesions started two weeks after chemotherapy with carboplatin and paclitaxel, and appeared as “bruise-like” red macules that gradually evolved into purpuric papules over the course of one week. The inpatient Dermatology service was consulted to rule out possible vasculitis. Review of systems was negative for arthralgia, abdominal pain, hematochezia, and hematuria.

Physical examination revealed multiple dark red macules, purpuric papules, and occasional hemorrhagic vesicles limited to the bilateral extensor forearms, distal upper arms, and dorsal hands (**Figure 1**). In contrast to the upper extremities, the patient did not have extensive sun damage of the face or other common photoexposed sites. The remainder of the skin examination was unremarkable. A punch biopsy was obtained from a papule on the right forearm for routine histopathologic examination (**Figure 2** and **Figure 3**).

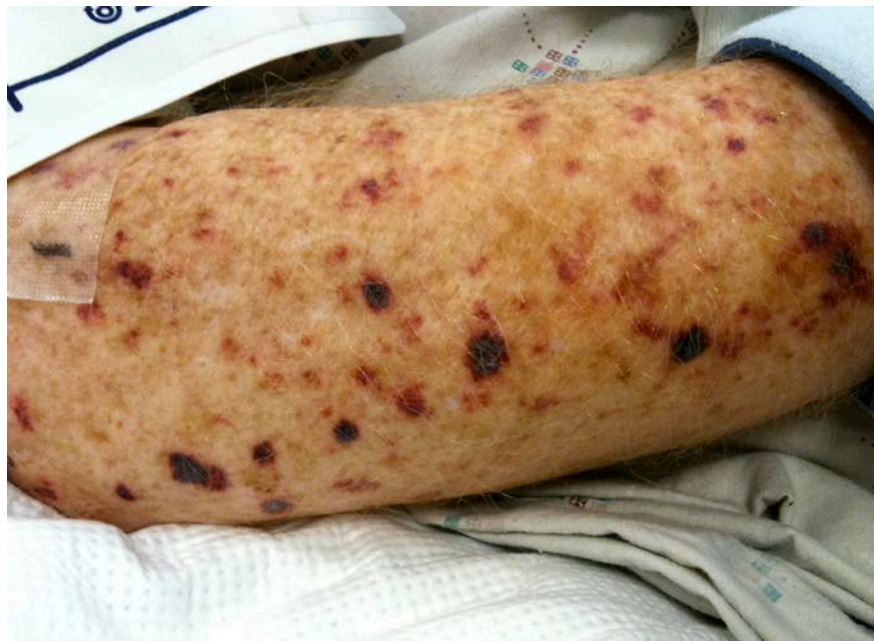

Figure 1: dark red macules, purpuric papules, and occasional hemorrhagic vesicles

Microscopic findings: Histopathologic examination of the biopsy specimen from the right forearm (Figure 2 and Figure 3) revealed partial to full thickness epidermal necrosis with subepidermal separation and numerous extravasated red blood cells in the papillary dermis. In areas of intact epidermis, basilar keratinocytes with enlarged pleomorphic nuclei were noted. Marked solar elastosis was present. There was no evidence of vasculitis.

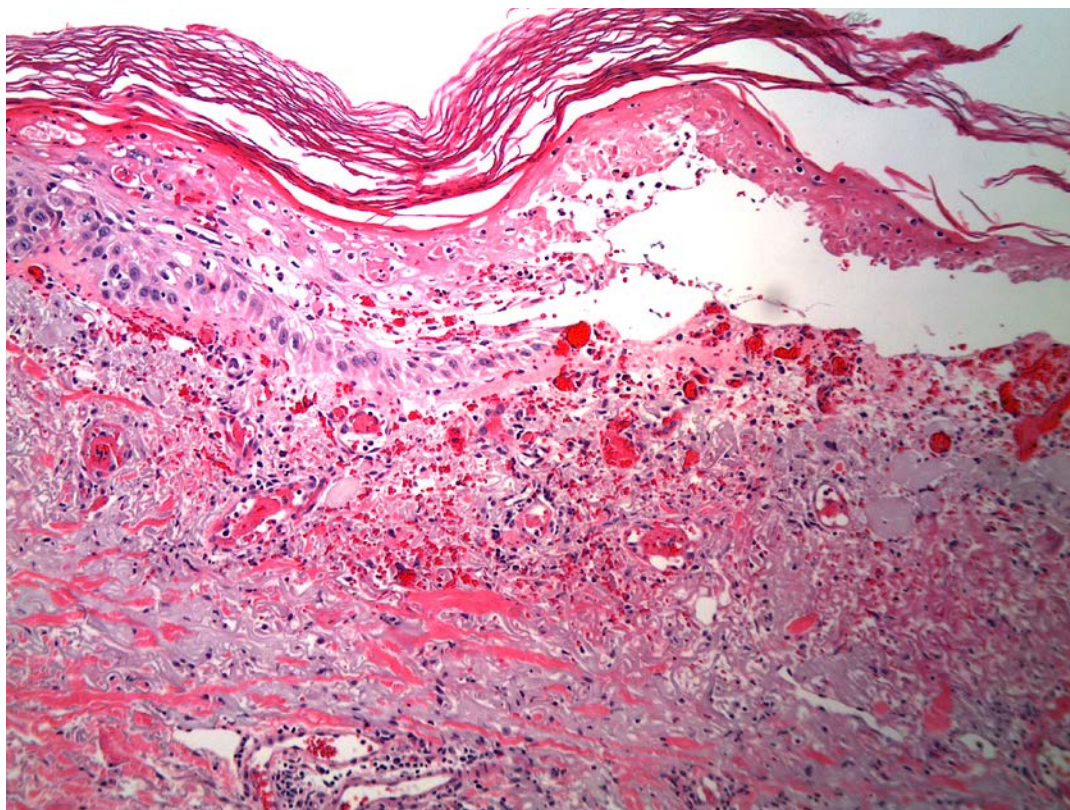
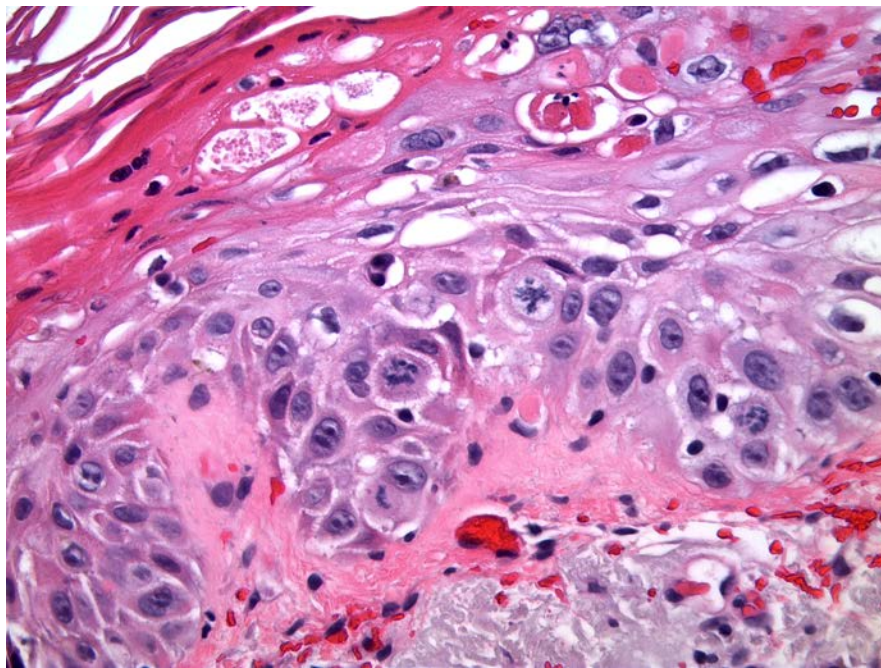


Figure 2: partial to full thickness epidermal necrosis with subepidermal separation



Figures 3: numerous extravasated red blood cells in the papillary dermis, marked solar elastosis

Microscopic Findings

Histopathologic examination of the biopsy specimen from the right forearm (Figure 2 and Figure 3) revealed partial to full thickness epidermal necrosis with subepidermal separation and numerous extravasated red blood cells in the papillary dermis. In areas of intact epidermis, basilar keratinocytes with enlarged pleomorphic nuclei were noted. Marked solar elastosis was present. There was no evidence of vasculitis.

Discussion

Chemotherapy-induced inflammation of actinic keratoses was first described by Falkson and Schulz in 1962 in patients receiving systemic 5-fluorouracil [1]. The authors noted that actinic keratoses developed erythema followed by resolution, resulting in a smoother skin texture in prior areas of photodamage. Subsequently, other chemotherapeutic agents causing a similar reaction have been described in patients receiving capecitabine [2], doxorubicin [3], pentostatin, dactinomycin [4], vincristine, dacarbazine, cytarabine, 6-thioguanine, docetaxel [5], and sorafenib [6].

Pearse and Marks showed that lesional and perilesional skin of actinic keratoses demonstrated abnormal cellular morphology with increased DNA synthesis, and postulated that this may partially explain the selective effect of chemotherapeutic agents on these lesions [7]. Another hypothesis is that this reaction represents a form of radiation recall, whereby the acute inflammatory reaction, strictly localized to previously irradiated skin occurs after exposure to a recall-triggering drug [8]. Authors in support of the latter hypothesis believe that such radiation recall represents a form of idiosyncratic drug hypersensitivity involving direct non-immune activation of inflammatory pathways [8]. The patient in this case, however, had no known therapeutic radiation exposure preceding the onset of his skin lesions.

Chemotherapy-induced inflammation of actinic keratoses typically presents in patients with subclinical actinic keratoses that become erythematous and pruritic within weeks of systemic chemotherapy initiation. The reaction is limited to sun-exposed areas and, classically, histologic findings of parakeratosis and epidermal necrosis with keratinocyte nuclear pleomorphism are present. Exuberant reactions with extensive epidermal necrosis may lead to subepidermal vesiculation.

The current case illustrates the importance of recognizing chemotherapy-induced inflammation of actinic keratoses in predisposed patients because it may be managed successfully with topical corticosteroids and does not necessitate discontinuation of the offending chemotherapeutic agent. In fact, many authors have observed clearance of the lesions despite continued therapy and argue that this reaction may be of therapeutic benefit, reflecting an extended pharmacologic side-effect.

References

1. Falkson G, Schulz E. Skin changes in patients treated with 5-fluorouracil. *BrJ Dermatol.* 1962 Jun;74:229-36. [PMID: 13891467].
2. Lewis KG, Lewis MD, Robinson-Bostom L, Pan TD. Inflammation of actinic keratoses during capecitabine therapy. *Arch Dermatol.* 2004 Mar;140(3):367-8. [PMID: 15023790].
3. Ilyas EN, Grana G, Green JJ. Inflammatory actinic keratoses secondary to systemic chemotherapy. *Cutis.* 2005 Mar;75(3):167-8. [PMID: 15839360].
4. Johnson TM, Rapini RP, Duvic M. Inflammation of actinic keratoses from systemic chemotherapy. *J Am Acad Dermatol.* 1987 Aug;17(2 Pt 1):192-7. [PMID: 3624557].
5. Zimmerman GC, Keeling JH, Burris HA, Cook G, Irvin R, Kuhn J, McCollough ML, Von Hoff DD. Acute cutaneous reactions to docetaxel, a new chemotherapeutic agent. *Arch Dermatol.* 1995 Feb;131(2):202-6. [PMID: 7857119].
6. Lacouture ME, Desai A, Soltani K, Petronic-Rosic V, Laumann AE, Ratain MJ, Stadler WM. Inflammation of actinic keratoses subsequent to therapy with sorafenib, a multitargeted tyrosine-kinase inhibitor. *ClinExp Dermatol.* 2006 Nov;31(6):783-5. Epub 2006 Jul 4. [PMID: 16824050].
7. Pearse AD, Marks R. Actinic keratoses and the epidermis on which they arise. *Br J Dermatol.* 1977 Jan;96(1):45-50. [PMID: 843436].
8. Hardwick N, Murray A. Inflammation of actinic keratoses induced by cytotoxic drugs. *Br J Dermatol.* 1986 May;114(5):639-40. [PMID: 3459547].