

UC Davis

Dermatology Online Journal

Title

Cutaneous sarcoidosis masquerading as psoriatic plaques

Permalink

<https://escholarship.org/uc/item/0pq3r2qv>

Journal

Dermatology Online Journal, 21(4)

Authors

Argraves, Melissa
Sloan, Steven B
Dadras, Soheil S

Publication Date

2015

DOI

10.5070/D3214026269

Copyright Information

Copyright 2015 by the author(s). This work is made available under the terms of a Creative Commons Attribution-NonCommercial-NoDerivatives License, available at <https://creativecommons.org/licenses/by-nc-nd/4.0/>

Peer reviewed

Case presentation

Cutaneous sarcoidosis masquerading as psoriatic plaques

Melissa Argraves, Steven B Sloan, Soheil S Dadras

Dermatology Online Journal 21 (4): 3

University of Connecticut Health Center

Correspondence:

Melissa Argraves
University of Connecticut Health Center
argraves@student.uhc.edu

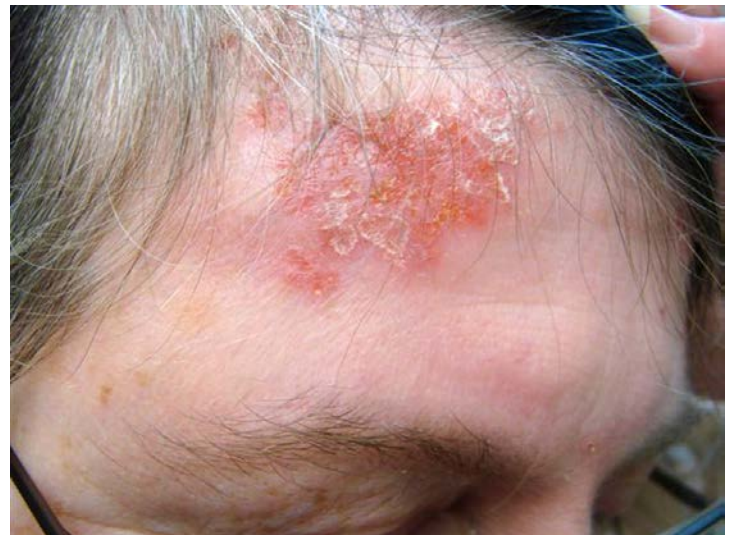Abstract

Sarcoidosis is a multisystem disease characterized by non-caseating granulomas present in the involved organ systems. The disease is believed to result from an interaction among genetic factors, antigens, and the immune response. Environmental exposures and infectious agents have been implicated as potential causes [1]. Cutaneous sarcoidosis presents clinically in many forms and the lesions are classified as either specific or non-specific. Non-specific lesions show a nondescript inflammatory process [2] whereas specific lesions display typical, non-caseating granulomas. There are many different forms of specific lesions with some being more common than others. Psoriasiform lesions are uncommon [1]. The literature suggests that as few as 0.9% of patients display this type of cutaneous sarcoidosis [3]. Some of these patients present solely with cutaneous sarcoidosis, but others have systemic involvement with pulmonary involvement being the most common concomitant presentation [4-8]. Plaques appear as round or oval, brownish, red infiltrated lesions [9], frequently involving the extensor surface of the extremities, face, scalp, back, and buttocks [9, 10]. Multiple configurations, including discrete, confluent, annular, and polycyclic, have been reported [5 11]. Despite the clinical resemblance to psoriasis, on histological examination, only non-caseating granulomas are seen in the dermis. In rare cases both psoriasiform sarcoidosis and psoriasis were present [4].

Keywords: Cutaneous sarcoidosis, psoriasiform, plaque

Case synopsis

A 54 year-old Caucasian woman with a 14-year history of multisystem sarcoidosis on rituximab, mycophenolate mofetil, and prednisone presented with worsening skin eruption. She had no personal or family history of psoriasis. The patient had a history of restrictive lung disease, optic neuritis, seizures, uveitis, and septal perforation, all considered to be caused by sarcoidosis. She had previously failed therapy with hydroxychloroquine, azathioprine, and methotrexate. She had been treated with infliximab for 8 years, with the most recent dose being 500 mg every 4 weeks,. Subsequently rituximab was added at 2 g IV every 4 weeks. The cutaneous eruption began two years prior, 6 months after discontinuation of infliximab and 5 months after beginning rituximab. Clinically, asymptomatic, scaly plaques initially on her legs, and then subsequently on her forearms and forehead developed. Additionally, in the few months prior to presentation,



she developed subcutaneous nodules around her knees and wrists. Treatment with clobetasol ointment decreased erythema, induration, and scaling but the plaques never completely resolved.

On physical examination, erythematous patches and plaques with silvery micaceous scale were present on her forehead (Figure 1), left hand (Figure 2), anterior lower legs (Figure 3), right thigh, and left inframammary chest. She also had non-tender, rubbery, mobile, 2-5 centimeter subcutaneous nodules with no overlying skin changes over her wrists, knees, and right elbow. She had no nail or mucous membrane abnormalities. There was no cervical, axillary or inguinal lymphadenopathy. Complete blood count, serum electrolytes, BUN/creatinine, calcium, liver function tests, and urinalysis were all within normal limits. HIV and hepatitis screening tests were negative.

Figure 1. Psoriasiform sarcoidal plaque on the forehead.

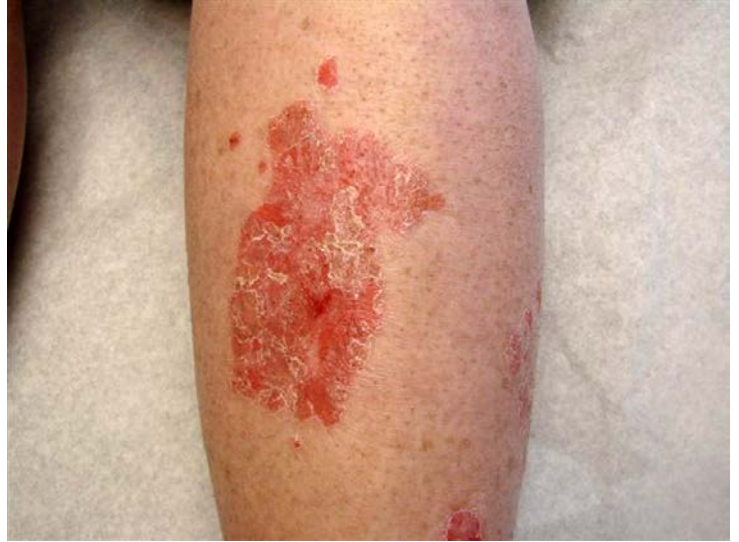
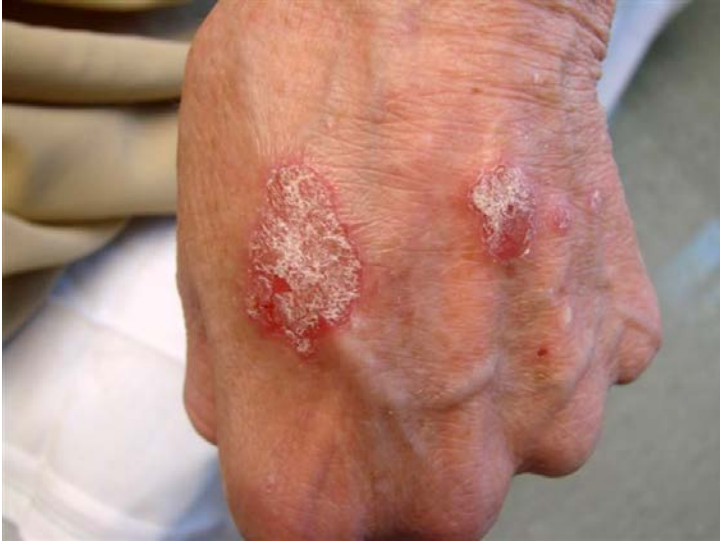
Figure 2. Psoriasiform sarcoidal plaques on the dorsal hand. **Figure 3.** Psoriasiform sarcoidal plaque on the shin.

A punch biopsy from a lesion on the left shin (Figure 4) showed hyperkeratosis and irregular psoriasiform hyperplasia (Figure 5) overlying dermal granulomatous inflammation composed of well-circumscribed, non-caseating epithelioid granulomas with a few lymphocytes (Figure 6). Biopsy of a left medial knee lesion (Figure 7) also showed multiple discrete granulomata shown at high magnification (Figure 8). Periodic Acid-Schiff and acid-fast stains were negative for microorganisms in both biopsies. Aside from irregular psoriasiform hyperplasia seen in the left shin biopsy, there were no other histopathologic features of psoriasis, such as regular psoriasiform hyperplasia, Munro microabscess, or spongiform pustule of Kogoj. The biopsy of the left medial knee showed no epidermal changes.

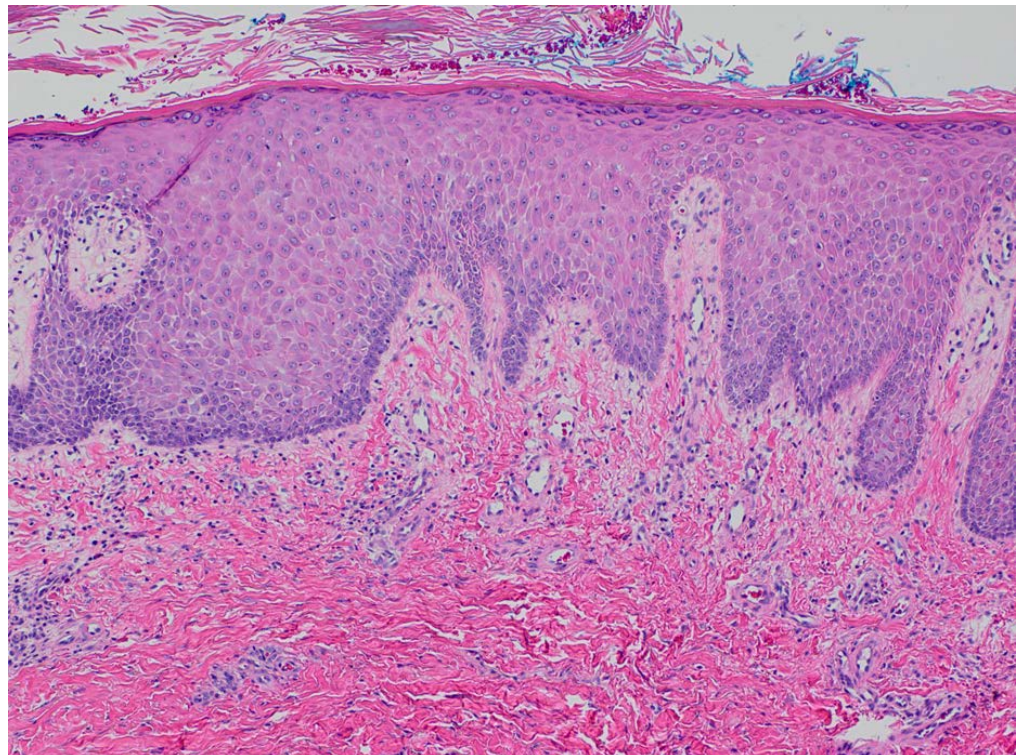
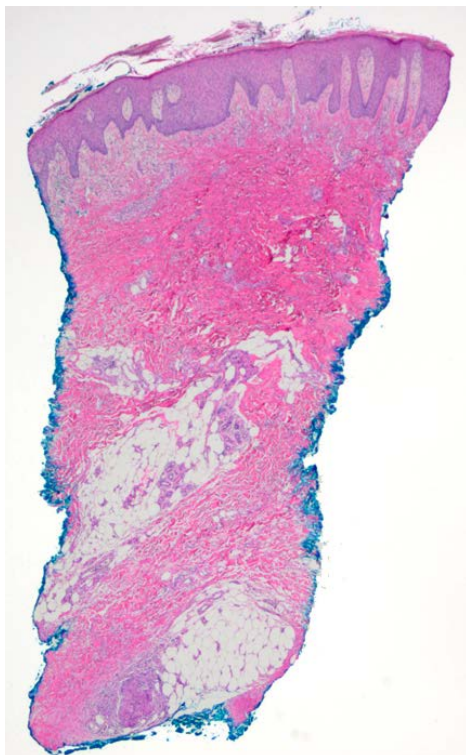


Figure 4. Irregular psoriasiform hyperplasia and hyperkeratosis overlying deep-seated granulomata in the shin **Figure 5.** : Irregular psoriasiform hyperplasia and hyperkeratosis in the shin at high magnification

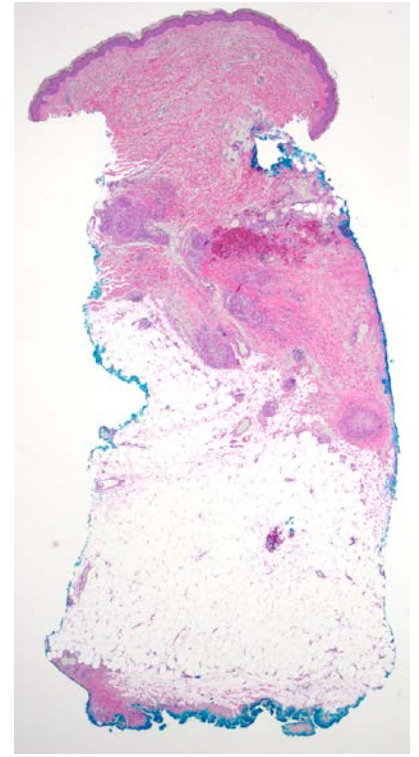
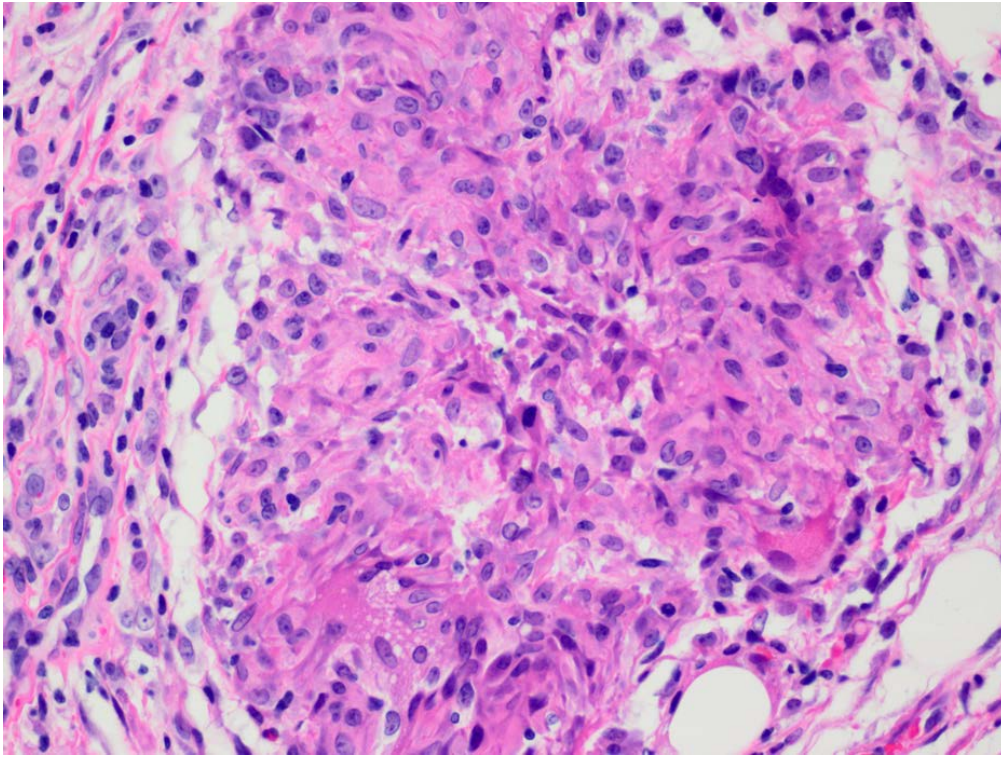
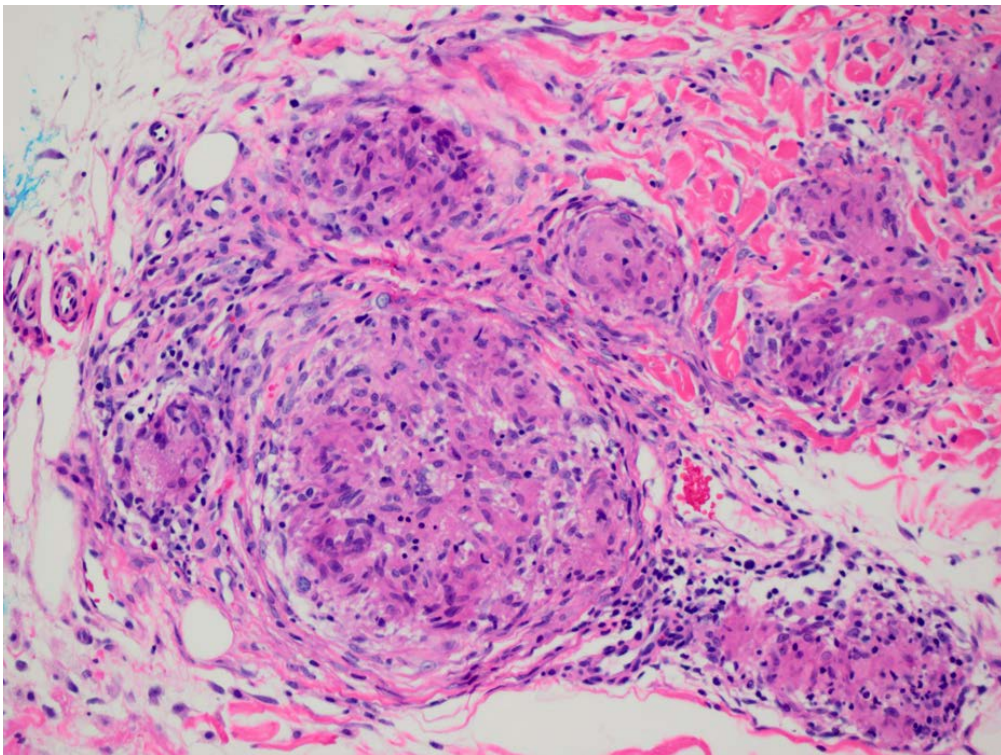


Figure 6. Well-circumscribed, non-caseating epithelioid granulomata with a few lymphocytes at high magnification

Figure 7. Multiple discrete granulomata in the dermis of left medial knee at low magnification

Figure 8. Multiple discrete granulomata with a few lymphocytes in the dermis of left medial knee at high magnification



Discussion

Treatment for patients with psoriasiform sarcoidosis includes hydroxychloroquine, prednisolone, and methotrexate. Most of the reported cases describe the psoriasiform lesions as part of the initial presentation of the disease and treatment resulted in remission of both cutaneous and systemic sarcoidosis [4, 5, 7]. In this case with multi-organ systemic disease, therapy for internal involvement took precedence over cutaneous disease. Despite treatment with systemic medication, her cutaneous disease continued to worsen. Topical and intralesional steroids decreased the erythema, induration, and scaling but never cleared the lesions. Topical tacrolimus had no effect.

Paradoxically, some patients treated with TNF inhibitors have developed psoriasis months to years after initiation of treatment with these agents [12]. Out of more than 200 documented cases, over 50% were treated with infliximab. Also, sarcoid-like granulomatosis has developed weeks to years after initiation of anti-TNF therapy, including infliximab [13, 14]. The length of time between discontinuation of infliximab and the appearance of skin lesions argues against induction of psoriasiform sarcoidosis by this drug. Notably, psoriasis, but not sarcoidosis, has developed in some patients 10 days to 6 months after initiation of rituximab [15]. Although clinically, our patient's lesions looked like psoriasis, histologically they were representative of sarcoidosis. There are no known reports of rituximab induced psoriasiform sarcoidosis in the literature, but its use has been associated with the development of various autoimmune conditions, making this a plausible explanation.

References

1. Haimovic A, Sanchez M, Judson MA, Prystowsky S. Sarcoidosis: a comprehensive review and update for the dermatologist: part II. Extracutaneous disease. *J Am Acad Dermatol*. 2012 May; 66(5): 719.e1-10; quiz 729-30. doi: 10.1016/j.jaad.2012.02.003. [PMID: 22507586]
2. Marchell RM, Judson MA. Chronic cutaneous lesions of sarcoidosis. *Clin Dermatol*. 2007 May-Jun;25(3):295-302. [PMID: 17560307]
3. Yanardağ H, Pamuk ON, Karayel T. Cutaneous involvement in sarcoidosis: analysis of the features in 170 patients. *Respir Med*. 2003 Aug;97(8):978-82. [PMID: 12924527]
4. Wanat KA, Schaffer A, Richardson V, VanVoorhees A, Rosenbach M. Sarcoidosis and Psoriasis: A Case Series and Review of the Literature Exploring Co-Incidence vs Coincidence. *JAMA Dermatol*. 2013;149(7):848-852. doi:10.1001/jamadermatol.2013.4256. [PMID: 23783749]
5. Reddy RR, Shashi kumar BM, Harish MR. Cutaneous sarcoidosis - a great masquerader: a report of three interesting cases. *Indian J Dermatol*. 2011;56(5):568-72. doi: 10.4103/0019-5154.87158. [PMID: 22121281]
6. Mahajan VK. Cutaneous sarcoidosis: clinical profile of 23 Indian patients. In *J Dermatol, Venerol, Leprol* 2007; 73(1):16-21 [PMID: 17314441]
7. Madke B. Polymorphic cutaneous sarcoidosis: A case report. *Iran J Dermatol* 2011; 14: 144-8
8. Sakemi H, Oiwa H. Psoriasiform plaques of sarcoidosis. *Intern Med*. 2009;48(5):391. [PMID: 19252370]
9. Mañá J, Marcoval J, Graells J, Salazar A, Peyrí J, Pujol R. Cutaneous involvement in sarcoidosis. Relationship to systemic disease. *Arch Dermatol*. 1997 Jul;133(7):882-8. [PMID: 9236527]
10. Elgart ML. Cutaneous sarcoidosis: definitions and types of lesions. *Clin Dermatol*. 1986 Oct-Dec;4(4):35-45. [PMID: 3542172]
11. Epstein WL. Cutaneous sarcoidosis. *Semin Respir Crit Care Med*. 2002 Dec;23(6):571-7. [PMID: 16088652]
12. Collamer AN, Battafarano DF. Psoriatic skin lesions induced by tumor necrosis factor antagonist therapy: clinical features and possible immunopathogenesis. *Semin Arthritis Rheum*. 2010 Dec;40(3):233-40. [PMID: 20580412]
13. Tong D, Manolios N, Howe G, Spencer D. New onset sarcoid-like granulomatosis developing during anti-TNF therapy: an under-recognized complication. *Intern Med* 2012 Jan;42(1):89-94 [PMID: 22389903]
14. Dhaille F, Viseux V, Caudron A, Dadban A, Tribout C, Boumier P, Clabaut A, Lok C. Cutaneous Sarcoidosis Occurring during Anti-TNF-Alpha Treatment: Report of Two Cases. *Dermatology*, 2010, Vol.220(3), p.234-237 [PMID: 20185892]
15. Guidelli GM, Fioravanti A, Rubegni P, Feci L. Induced psoriasis after rituximab therapy for rheumatoid arthritis: a case report and review of the literature. *Rheumatol Int*. 2013 Nov;33(11):2927-30. doi: 10.1007/s00296-012-2581-3. Epub 2012 Nov 8. [PMID: 23135613]